

Gastroduodenal melanoma in a male patient with hemoptysis

Nikolaos V. Chrysanthos, Evaggelia Anagnostopoulou, Stamatia Patsavela, Theofania Dontsi

“St George” General Hospital of Chania, Greece

Melanomas of gastrointestinal tract are rare carcinomas with high malignancy index and poor prognosis [1,2]. Often these neoplasms metastasize rapidly and it is not uncommon for them to present with complications from the metastasized location [3,4].

We describe a case of a male patient who was admitted to our hospital due to acute hemoptysis as the only symptom. He had no medical history and he did not take any medication. Laboratory tests revealed slight elevation of the liver enzymes and normocytic anemia. Computed tomography of the chest revealed a small oval lesion on the right middle lobe. Hepatic and splenic lesions suspected as metastases were revealed after abdominal computer tomography. A detailed dermatological inspection did not locate any suspect lesion of melanoma or other type of skin cancer. A bronchoscopy was performed, with a non-pathognomonic lavage specimen but a few cells with melanocytic origin from the secondary lesion were found.

The patient underwent an upper gastrointestinal endoscopy, which revealed multiple giant black brown lesions throughout the stomach (Fig. 1) and fewer spotty black-brown lesions in the duodenum. Multiple biopsies were obtained. Colonoscopy did not show any lesions of melanoma. Histology revealed an invasive gastroduodenal melanoma and immunohistochemistry shows positivity for proteins S-100 and HMB-45.

Melanomas of the alimentary tract are severe malignancies but there is a chance of cure, which is greater if early discovered and entirely removed.

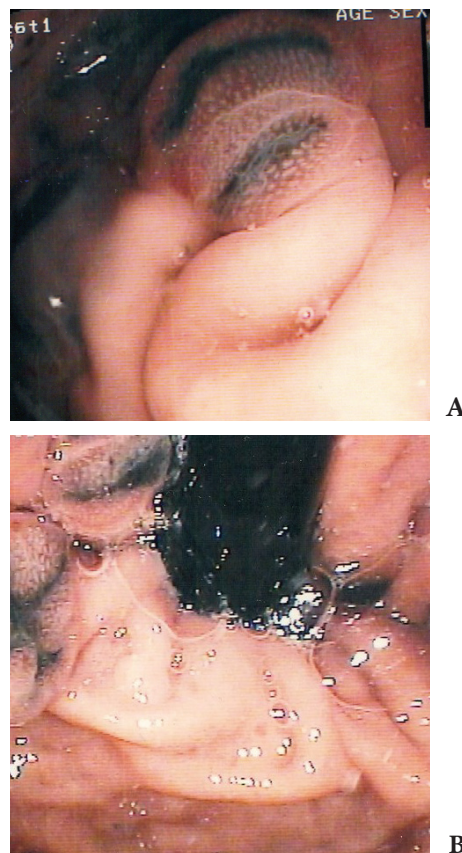


Figure 1 Giant pigmented lesions of melanoma in the body (A) and in the fundus (B) of the stomach

References

1. Nakamura T, Ide H. Malignant melanoma of the alimentary tract. *Gan To Kagaku Ryoho* 2003;30:619-625.
2. Alazmi WM, Nehme OS, Regalado JJ, et al. Primary gastric melanoma presenting as a nonhealing ulcer. *Gastrointest Endosc* 2003;57:431-433.
3. Bejarano González N, García Moforte N, Darnell Martín A, et al. Primary malignant melanoma of the common bile duct: a case report and literature review. *Gastroenterol Hepatol* 2005;28:382-384.
4. Volpin E, Sauvanet A, Couvelard A, et al. Primary malignant melanoma of the esophagus: a case report and review of the literature. *Dis Esophagus* 2002;15:244-249.

Gastrointestinal Department “St. George” General Hospital of Chania, Greece

Conflict of Interest: None

Correspondence to: NV Chrysanthos MD, PhD, Gastrointestinal Department “St. George” General Hospital of Chania, Greece, Tel: +306978310963, e-mail: nchrysanthos@yahoo.gr

Received 22 November 2011; accepted 27 November 2011