

# The role of antibiotics and probiotics in pouchitis

Paolo Gionchetti<sup>a</sup>, Andrea Calafiore<sup>a</sup>, Donatella Riso<sup>a</sup>, Giuseppina Liguori<sup>a</sup>, Carlo Calabrese<sup>a</sup>, Giulia Vitali<sup>b</sup>, Silvio Laureti<sup>b</sup>, Gilberto Poggioli<sup>b</sup>, Massimo Campieri<sup>a</sup>, Fernando Rizzello<sup>a</sup>

University of Bologna, Bologna, Italy

## Abstract

Pouchitis is a non-specific inflammation of the ileal reservoir and the most common complication of proctocolectomy with ileal pouch-anal anastomosis (IPAA) in patients with ulcerative colitis. Its frequency is related to the duration of the follow up, occurring in up to 50% of patients 10 years after IPAA in large series from major referral centers. Treatment of pouchitis is largely empirical and only small placebo-controlled trials have been conducted. The rationale for using probiotics and antibiotics in pouchitis is based on convincing evidence that implicates intestinal bacteria in the pathogenesis of this disease. Probiotics are living organisms, which, upon ingestion in certain numbers, exert health benefits beyond inherent basic nutrition. VSL#3, a highly concentrated cocktail of probiotics has been shown to be effective in the prevention of pouchitis onset and relapses. Antibiotics are the mainstay of treatment of pouchitis, and metronidazole and ciprofloxacin are the most common initial approaches, often with a rapid response. The use of antibiotics in pouchitis is largely justified although proper controlled trials have not been conducted.

**Keywords** probiotics, antibiotics, pouchitis, IBD

*Ann Gastroenterol 2012; 25 (2): 100-105*

## Introduction

The rationale for using probiotics and antibiotics in inflammatory bowel disease (IBD) is based on convincing evidence that implicates intestinal bacteria in the pathogenesis of the disease. The distal ileum and the colon are the areas with the highest bacterial concentrations and represent the sites of inflammation in IBD. Similarly, pouchitis, the nonspecific inflammation of the ileal reservoir after IPAA, appears to be associated with bacterial overgrowth and dysbiosis. Enteric bacteria and their products have been found within the inflamed mucosa of patients with Crohn's disease (CD) [1]. The composition of the enteric flora is altered in patients with IBD. Increased numbers of aggressive bacteria, such as bacteroides, adherent/invasive *Escherichia coli* and enterococci, and decreased numbers of protective lactobacilli and bifidobacteria have been observed [2]. Manichanh et al reported a restriction of

biodiversity in the fecal microbiota of CD patients. [3]. The phylum firmicutes and particularly the species *Fecalibacterium prausnitzii* are underrepresented in active CD and ulcerative colitis (UC) compared with healthy subjects [4], and reduction in *Fecalibacterium prausnitzii* is associated with higher risk of postoperative recurrence of ileal CD [5]. There is evidence of a loss of immunological tolerance to commensal bacteria in patients with IBD [6]. Patients with CD consistently respond to diversion of fecal stream, with immediate recurrence of inflammation after restoration of intestinal continuity or infusion of luminal content into the bypassed ileum [7,8]. Furthermore, pouchitis does not occur prior to closure of the ileostomy [9].

The most compelling evidence that intestinal bacteria play a role in IBD is derived from animal models. Despite great diversity in genetic defects and immunopathology, a consistent feature of many transgenic and knockout mutant murine models of colitis is that the presence of normal enteric flora is required for full expression of inflammation [10].

All of these observations suggest that IBD may be prevented or treated by the manipulation of intestinal microflora, and increasing evidence supports a therapeutic role for probiotics and antibiotics in IBD and particularly in pouchitis [11].

<sup>a</sup>Department of Clinical Medicine (Paolo Gionchetti, Andrea Calafiore, Donatella Riso, Giuseppina Liguori, Carlo Calabrese, Massimo Campieri, Fernando Rizzello);

<sup>b</sup>Department of Surgery (Giulia Vitali, Silvio Laureti, Gilberto Poggioli), University of Bologna, Bologna, Italy

Conflict of Interest: None

Correspondence to: Paolo Gionchetti, Department of Clinical Medicine and Gastroenterology, Policlinico S. Orsola, Via Massarenti 9, 40138 Bologna, Italy, e-mail: paolo.gionchetti@unibo.it

Received 28 December 2011; accepted 13 February 2012

## Probiotics

The potential benefit of probiotics in health maintenance and disease prevention has long been acknowledged. At the

turn of the last century, the Russian Nobel Prize winner Elie Metchnikoff suggested that high concentrations of lactobacilli in the intestinal flora were important for health and longevity in humans [12]. Probiotics are defined as “living organisms, which upon ingestion in certain numbers exert health benefits beyond inherent basic nutrition” [13].

The bacteria most commonly associated with probiotic activity are lactobacilli, bifidobacteria, and streptococci, but other, non-pathogenic bacteria (e.g. some strains of *E. coli*) and nonbacterial organisms (e.g. the yeast *Saccharomyces boulardii*) have been used. To be clinically useful probiotics should be resistant to acid and bile, metabolically active within the luminal flora (where they should survive but not persist in the long term), antagonistic against pathogenic bacteria, safe for human use, and viable following manufacturing processes [14].

Several mechanisms have been proposed to account for the action of probiotics (Table 1). These may include modulation of microbiota, enhancement of barrier function, and immunomodulation through direct effects of probiotic bacteria on different immune and epithelial cell types [15].

### Probiotics in pouchitis

Table 2 summarizes the results of trials carried-out with probiotics in pouchitis. Total proctocolectomy with ileal-pouch anal anastomosis (IPAA) represents nowadays the surgical treatment of choice for the management of patients with familial adenomatous polyposis and UC, and pouchitis, a non specific (idiopathic) inflammation of the ileal reservoir, is the most common long-term complication after pouch surgery for UC [16]. The etiology of pouchitis is still unknown, and is likely to be multifactorial; however the immediate response to antibiotic treatment suggests a pathogenic role for the microflora, and recently pouchitis was associated with a decreased ratio of anaerobic to aerobic bacteria and reduced fecal concentrations of lactobacilli and bifidobacteria [17]. Antibiotics are the mainstay of treatment, and metronidazole and ciprofloxacin are the common initial therapeutic approach and most patients have a dramatic response within a few days [16]. A double-blind study to compare the efficacy of

VSL#3 (VSL Pharmaceuticals, Inc., Ft. Lauderdale, FL) with placebo in the maintenance treatment of chronic pouchitis was carried out. Patients (n=40) who were in clinical and endoscopic remission after 1 month of combined antibiotic treatment (2 g/day of rifaximin plus 1 g/day of ciprofloxacin) were randomized to receive either VSL#3 ( $1.8 \times 10^{12}$  CFU) or placebo for 9 months. Patients were assessed clinically every month, and assessed endoscopically and histologically at entry and every 2 months thereafter. Stool culture was performed before and after antibiotic treatment and monthly during maintenance treatment. Relapse was defined as an increase of at least 2 points in the clinical section of the Pouchitis Disease Activity Index (PDAI) and was confirmed endoscopically and histologically. All 20 patients treated with placebo relapsed during the follow-up period. In contrast, 17 of the 20 (85%) patients treated with VSL#3 were still in remission after 9 months. Interestingly, all these 17 patients relapsed within 4 months of suspension of the active treatment. Fecal concentrations of lactobacilli, bifidobacteria, and *Streptococcus thermophilus* were significantly increased within 1 month of treatment initiation and remained stable throughout the study only in the group treated with VSL#3 [18]. A subsequent double-blind, placebo-controlled study on the effectiveness of VSL#3 (at a daily dose of  $1.8 \times 10^{12}$  CFU) in the maintenance of antibiotic-induced remission in patients with refractory or recurrent pouchitis reported similar results [19]. After 1 year of treatment, 85% of those in the VSL#3 group were in remission versus only 6% of those in the placebo group. With respect to the mechanism of action of VSL#3 in these patients, continuous administration of VSL#3 decreases matrix metalloproteinase activity, significantly increases tissue levels of interleukin (IL)-10, and significantly decreases tissue levels of the proinflammatory cytokines IL-1, tumor necrosis factor- $\alpha$ , and interferon  $\gamma$  [20]. In contrast, in a 3-month double-blind, placebo-controlled trial *Lactobacillus rhamnosus* strain GG (two gelatin capsules/day of  $0.5-1 \times 10^{10}$  CFU/capsule) in patients with a previous history of pouchitis showed that this probiotic was not effective in preventing relapses [21].

In an open study Shen et al treated 31 patients with antibiotic-dependent pouchitis with VSL#3 at the dose of  $1.8 \times 10^{12}$  CFU/day after having had a clinical improvement with

**Table 1** Mechanisms of action of probiotics

Action	Mechanism
Inhibit pathogenic enteric bacteria	<ul style="list-style-type: none"> <li>• Decrease luminal pH</li> <li>• Secrete bacteriocidal proteins</li> <li>• Colonization resistance</li> <li>• Block epithelial binding</li> </ul>
Improve epithelial and mucosal barrier function	<ul style="list-style-type: none"> <li>• Produce short-chain fatty acids</li> <li>• Enhance mucus production</li> <li>• Increase barrier integrity</li> </ul>
Alter immunoregulation	<ul style="list-style-type: none"> <li>• Increase IL-10 and TGF-<math>\beta</math> and decrease TNF-<math>\alpha</math></li> <li>• Increase immunoglobulin A production</li> </ul>

IL-10, interleukin-10; TGF- $\beta$ , transforming growth factor- $\beta$ ; TNF- $\alpha$ , tumor necrosis factor- $\alpha$

**Table 2** Probiotics in pouchitis

Study	N	Duration	Probiotic	Control	Remission (Probiotic; Control)	P
Gionchetti 2002 [Maintenance: antibiotic-remission]	40	9 mo	VSL#3	placebo	85% ; 0%	<0.001
Mimura 2004 [Maintenance: antibiotic-remission]	36	12 mo	VSL#3	placebo	85% ; 6%	<0.001
Gionchetti 2003 [Post-op prevention]	40	12 mo	VSL#3	placebo	90% ; 60%	<0.05
Shen 2005 [Maintenance antibiotic-dependent]	31	8 mo	VSL#3	open label	19.4%	ns
Kuisma 2003 [Acute pouchitis]	20	3 mo	Lactobacillus GG	placebo	0% ; 0%	ns
Gionchetti 2007 [Acute pouchitis]	29	4 wk	VSL#3	open label	69%	P<0.01

2 weeks treatment with ciprofloxacin 500 mg PO BID. At 8-month follow-up, six patients were still on VSL#3, while 25 had discontinued therapy due to either recurrence of symptoms or adverse effects. This study has numerous limitations. Firstly patients had to purchase VSL#3 from the company's web site; VSL#3 is not covered by insurance and therefore patient's adherence to therapy was a problem. Secondly, because VSL#3 was self-administered by patients medicine counts and prescription records were impossible. Further, fecal bacteriology, as in the previous study was not done and this further raises the issue of adherence to therapy. Another important issue is that patients were not assessed endoscopically before starting VSL#3 treatment (in contrast to previous placebo-controlled studies); this would have missed residual inflammation in the pouch and may explain the high relapse rate. Finally patients' response was based on symptoms assessment, and recurrence of symptoms while on VSL#3 does not necessarily indicate the presence of pouchitis [22]. A double-blind, placebo-controlled trial has evaluated the efficacy of VSL#3 in the prevention of pouchitis onset in patients following IPAA for UC [23]. Within 1 week after ileostomy closure, 40 patients were randomized to receive either VSL#3 ( $0.9 \times 10^{12}$  CFU) or placebo for 12 months. Patients were assessed clinically, endoscopically, and histologically at 1, 3, 6, 9, and 12 months according to PDAI score. During the first year after ileostomy closure, patients treated with VSL#3 had a significantly lower incidence of acute pouchitis compared with those treated with placebo (10% vs. 40%;  $p < 0.05$ ). Moreover, IBD questionnaire score was significantly improved only in the group treated with VSL#3 and among those who did not develop pouchitis, the median stool frequency was significantly lower in the VSL#3 group. More recently, an open-label study evaluated the efficacy of

high-dose of VSL#3 ( $3.6 \times 10^{12}$  CFU/day) in the treatment of mild pouchitis, defined as a score between 7 and 12 in the PDAI. Sixteen of 29 patients (69%) were in remission after 4 weeks [24]. Recently ECCO guidelines suggested the use of VSL#3 both for maintenance of antibiotic-induced remission and for prevention of pouchitis [25].

### Antibiotics in pouchitis

Table 3 summarizes the results of trials carried-out with antibiotics in pouchitis. The evidence of the crucial role of fecal stasis and the bacterial overgrowth in the pathogenesis of acute pouchitis has led the clinicians to treat patients with antibiotics, which have become the mainstay of treatment, in absence of controlled trials. Usually metronidazole represents the most common first therapeutic approach, and most patients with acute pouchitis respond quickly to administration of 1-1.5 g/day [16,26,27]. A double-blind, randomized, placebo-controlled, crossover trial was carried out by Madden et al to assess the efficacy of 400 mg TID of metronidazole PO in 13 patients (11 completed both arms of the study) with chronic, unremitting pouchitis. Patients were treated for two weeks, and metronidazole was significantly more effective than placebo in reducing the stool frequency (73% vs. 9%), even without improvement in endoscopic appearance and histologic grade of activity. Some patients (55%) experienced side effects of metronidazole including nausea, vomiting, abdominal discomfort, headache, skin rash and metallic taste [28].

More recently Shen et al have compared the effectiveness and side effects of ciprofloxacin and metronidazole for treating acute

**Table 3** Antibiotics in pouchitis

Study	n	Weeks	Main Outcome	Study design	Treatment schedules	Results
Madden (1994)	11	1	Clinical Improvement	DB crossover	Mtz (400 mg TID) vs. Placebo	Reduced stool frequency (Mtz 79% vs. placebo 9%)
Shen (2001)	16	2	Change in PDAI from baseline	DB	Ciprofloxacin (500 BID) vs. Mtz (20mg/kg/day)	Significant reduction of PDAI in both groups
Gionchetti (1999)	18	2	Change in PDAI from baseline	Open label in chronic refractory patients	Ciprofloxacin (500 mg BID) + Rifaximin (2 g/day)	88.8% improvement or remission
Mimura (2002)	44	4	Change in PDAI from baseline	Open label in chronic refractory patients	Mtz (800-1000 mg/day) + Ciprofloxacin (500 BID)	82% remission
Shen (2007)	16	4	Change in PDAI from baseline	RCT with comparison with historic cohort	Tinidazole (15 mg/kg/day) + Ciprofloxacin (500 mg BID)	87.5% remission

PDAI, pouchitis disease activity index; Mtz, metronidazole; DB, double-blind; RCT, randomized controlled trial

pouchitis in a randomized clinical trial. Seven patients received ciprofloxacin 1 g/day and nine patients metronidazole 20 mg/Kg/day for a period of 2 weeks. The results of this study have shown that both ciprofloxacin and metronidazole are efficacious as treatment of acute pouchitis: they reduced the total PDAI scores and led to a significant improvement in symptoms and endoscopic and histologic scores. However ciprofloxacin led to a greater degree of reduction in total PDAI score and to a greater improvement in symptoms and endoscopic scores; furthermore ciprofloxacin was better tolerated than metronidazole (33% of metronidazole-treated patients reported adverse-effects, none of ciprofloxacin-treated) [29].

### Treatment of chronic pouchitis

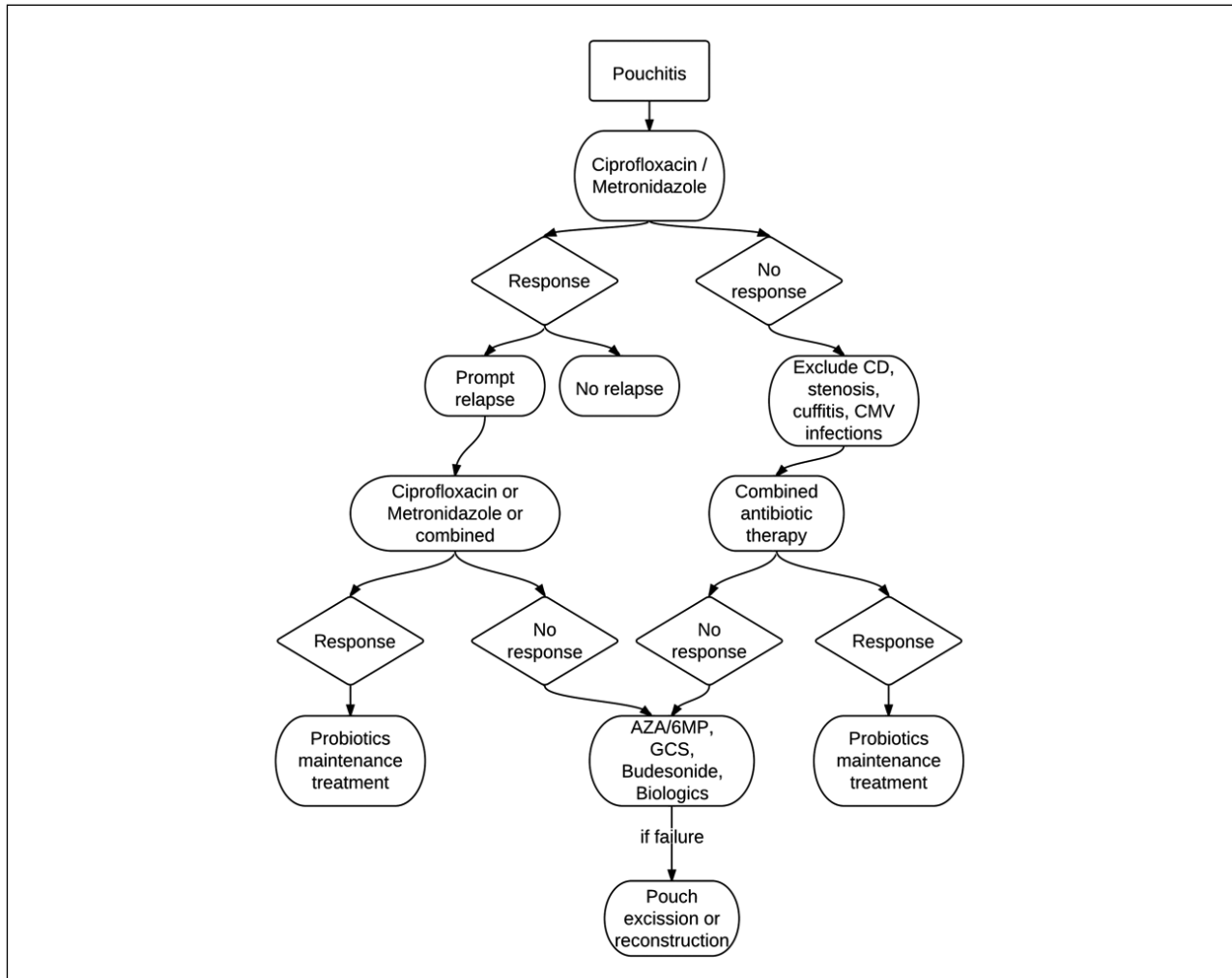
Medical treatment of patients with chronic refractory pouchitis is particularly difficult and disappointing. A possible therapeutic alternative for chronic refractory pouchitis is the use of a combined antibiotic treatment. In an open trial, 18 patients with active pouchitis not responding to the standard therapy (metronidazole or ciprofloxacin) for 4 weeks, were treated orally with rifaximin 2 g/day + ciprofloxacin 1g/day for 15 days; symptoms assessment, endoscopic and histological evaluations were performed at screening and after 15 days according to PDAI. Sixteen of 18 patients (88.8%) either improved (n=10) or went into remission (n=6); the median PDAI scores before and after therapy were 11 and 4 respectively (p<0.002) [30].

In another controlled study, 44 patients with refractory pouchitis received metronidazole 800 mg 1g/day and ciprofloxacin 1 g/day for 28 days. Thirty-six patients (82%) went into remission; the median PDAI scores before and after therapy were 12 and 3 respectively (p<0.0001). Patients' quality

of life significantly improved with the treatment (median IBDQ increased from 96.5 to 175) [31]. More recently, sixteen consecutive patients with chronic, refractory pouchitis (disease >4 weeks and failure to respond to >4 weeks of single-antibiotic therapy) were treated with ciprofloxacin 1 g/day and tinidazole 15 mg/kg/day for 4 weeks. A historic cohort of ten consecutive patients with chronic refractory pouchitis treated with 5-8 g oral and topical mesalazine daily was used as a comparator. These refractory patients had a significant reduction in the total PDAI score and a significant improvement in quality-of-life score (p<0.002) when they received ciprofloxacin and tinidazole, compared to baseline. The rate of clinical remission in the antibiotic group was 87.5% and for the mesalazine group was 50% [32]. Recently ECCO guidelines suggested that antibiotics (ciprofloxacin and metronidazole) are the first-line treatment for acute pouchitis, and that the combination of two antibiotics is effective in chronic pouchitis [25].

### Treatment algorithm in pouchitis

A proposed algorithm for treatment of pouchitis (Fig. 1) is that once diagnosis is confirmed by endoscopy and histology, the main treatment consists of metronidazole 250 mg TID or ciprofloxacin 500 mg BID for at least two weeks. In case of a subsequent prompt relapse the patients can be treated with a prolonged course of the same antibiotic or with a combined antibiotic treatment; in case of positive response we suggest to start maintenance treatment with highly concentrated probiotics. In refractory pouchitis, patients should be treated with other antibiotics or prolonged combined antibiotic treatment. Again, in case of response, maintenance probiotic treatment after stopping of antimicrobial agents is suggested. When no positive



**Figure 1** Proposed treatment algorithm in pouchitis  
 CD, Crohn's disease; CMV, Cytomegalovirus; AZA/6MP, azathioprine/6-mercaptopurine, GCS, glucocorticosteroids

response is obtained one should try other types of treatment such as oral budesonide, corticosteroids, oral or topical salicylates, immunosuppressive agents or biologics. Patients who will be refractory to all forms of medical treatment should be referred to a surgeon for a redo-pouch or pouch excision.

of bacteria in many of the currently available preparations are unproven. It should be noted that the beneficial effect of one probiotic preparation does not imply efficacy of other preparations containing different bacterial strains, because each individual probiotic strain has unique biological properties.

The use of antibiotics in pouchitis is largely justified although proper controlled trials have not been conducted.

**Conclusions**

Many clinical and experimental observations indicate that the intestinal microflora is involved in the pathogenesis of IBD.

Probiotics may provide a simple and attractive way of preventing or treating IBD, and patients find the probiotic concept appealing because it is safe, nontoxic, and natural.

VSL#3, a highly concentrated cocktail of probiotics has been shown to be effective in the prevention of pouchitis onset and relapses.

It is important to select a well-characterized probiotic preparation, in view of the fact that the viability and survival

**References**

1. Guarner F, Casellas F, Borruel N, et al. Role of microecology in chronic inflammatory bowel diseases. *Eur J Clin Nutr* 2002;**56**:S34-S38.
2. Neut C, Bulois P, Desreumaux P, et al. Changes in the bacterial flora of the neoterminal ileum after ileocolonic resection for Crohn's disease. *Am J Gastroenterol* 2002;**97**:939-946.
3. Manichanh C, Rigottier-Gois L, Bonnaud E, et al. Reduced diversity of faecal microbiota in Crohn's disease revealed by a

- metagenomic approach. *Gut* 2006;**55**:205-211.
4. Sokol H, Seksik P, Furet JP, et al. Low counts of fecalibacterium prausnitzii in colitis microbiota. *Inflamm Bowel Dis* 2009;**15**:1183-1189.
  5. Sokol H, Pigneur B, Watterlot L, et al. Fecalibacterium prausnitzii is an anti-inflammatory commensal bacterium identified by gut microbiota analysis of Crohn's disease patients. *PNAS* 2008;**105**:16731-16736.
  6. Duchmann R, Kaiser I, Hermann E, et al. Tolerance exist towards resident intestinal flora but is broken in active inflammatory bowel disease (IBD). *Clin Exp Immunol* 1995;**102**:445-447.
  7. Janowitz HD, Croen EC, Sachar DB. The role of the faecal stream in Crohn's disease: an historical and analytic perspective. *Inflamm Bowel Dis* 1998;**4**:29-39.
  8. D'Haens GR, Geboes K, Peeters M, et al. Early lesions of recurrent Crohn's disease caused by infusion of intestinal contents in excluded ileum. *Gastroenterology* 1998;**114**:771-774.
  9. Abdelrazeq AS, Kandiyil N, Botterill ID, et al. Predictors for acute and chronic pouchitis following restoration proctocolectomy for ulcerative colitis. *Colorectal Dis* 2007;**10**:805-813.
  10. Sartor RB. Insights into the pathogenesis of inflammatory bowel disease provided by new rodent models of spontaneous colitis. *Inflamm Bowel Dis* 1995;**1**:64-75.
  11. Campieri M, Gionchetti P. Probiotics in inflammatory bowel disease: new insight to pathogenesis or a possible therapeutic alternative? *Gastroenterology* 1999;**116**:1246-1249.
  12. Metchnikoff E. *The Prolongation of Life: Optimistic Studies*. William Heinemann: London; 1907, pp. 161-183.
  13. Schaafsma G. State of the art concerning probiotic strains in milk products. *IDF Nutr Newsl* 1996;**5**:23-24.
  14. Lee YK, Salminen S. The coming age of probiotics. *Trends Food Sci Technol* 1995;**6**:241-245.
  15. Ng SC, Hart AL, Kamm MA, et al. Mechanism of action of probiotics: recent advances. *Inflamm Bowel Dis* 2009;**15**:300-310.
  16. Pardi DS, D'Haens G, Shen B, Campbell S, Gionchetti P. Clinical guidelines for the management of pouchitis. *Inflamm Bowel Dis* 2009;**15**:1424-1431.
  17. Ruseler-van-Emden JGH, Schouten WR, van Lieshout LMC. Pouchitis: result of microbial imbalance? *Gut* 1994;**35**:658-664.
  18. Gionchetti P, Rizzello F, Venturi A, et al. Oral bacteriotherapy as maintenance treatment in patients with chronic pouchitis: a double-blind, placebo-controlled trial. *Gastroenterology* 2000;**119**:305-309.
  19. Mimura T, Rizzello F, Helwig U, et al. Once daily high dose probiotic therapy for maintaining remission in recurrent or refractory pouchitis. *Gut* 2004;**53**:108-114.
  20. Ulisse S, Gionchetti P, D'Alò S, et al. Increased expression of cytokines, inducible nitric oxide synthase and matrix metalloproteinases in pouchitis: effects of probiotic treatment (VSL#3). *Gastroenterology* 2001;**96**:2691-2699.
  21. Kuisma J, Mentula S, Kahri A, et al. Effect of Lactobacillus rhamnosus GG on ileal pouch inflammation and microbial flora. *Aliment Pharmacol Ther* 2003;**17**:509-515.
  22. Shen B, Brzezinski A, Fazio VW, et al. Maintenance therapy with a probiotic in antibiotic-dependent pouchitis: experience in clinical practice. *Aliment Pharmacol Ther* 2005;**22**:721-728.
  23. Gionchetti P, Rizzello F, Helvig U, et al. Prophylaxis of pouchitis onset with probiotic therapy: a double-blind placebo controlled trial. *Gastroenterology* 2003;**124**:1202-1209.
  24. Gionchetti P, Rizzello F, Morselli C, et al. High-dose probiotics for the treatment of active pouchitis. *Dis Colon Rectum* 2007;**50**:2075-2082.
  25. Biancone L, Michetti P, Travis S, et al. European evidence-based Consensus in the management of ulcerative colitis: special situations. *J Crohns Colitis* 2008;**2**:63-92.
  26. Sandborn WJ, McLeod, Jewell DP. Medical therapy for induction and maintenance of remission in pouchitis. A systematic review. *Inflamm Bowel Dis* 1999;**5**:33-39.
  27. Hurst RD, Molinari M, Chung P, Rubin M, Michelassi F. Prospective study of the incidence, timing and treatment of pouchitis in 104 consecutive patients after restorative proctocolectomy. *Arch Surg* 1996;**131**:497-502.
  28. Madden M, McIntyre A, Nicholls RJ. Double-blind cross-over trial of metronidazole versus placebo in chronic unremitting pouchitis. *Dig Dis Sci* 1994;**39**:1193-1196.
  29. Shen B, Achkar JP, Lashner BA, et al. A randomized clinical trial of ciprofloxacin and metronidazole to treat acute pouchitis. *Inflamm Bowel Dis* 2001;**7**:301-305.
  30. Gionchetti P, Rizzello F, Venturi A, et al. Antibiotic combination therapy in patients with chronic, treatment-resistant pouchitis. *Aliment Pharmacol Ther* 1999;**13**:713-718.
  31. Mimura T, Rizzello F, Helwig U, et al. Four week open-label trial of metronidazole and ciprofloxacin for the treatment of recurrent or refractory pouchitis. *Aliment Pharmacol Ther* 2002;**16**:909-917.
  32. Shen B, Fazio VW, Remzi FH, et al. Combined ciprofloxacin and tinidazole therapy in the treatment of chronic refractory pouchitis. *Dis Colon Rectum* 2007;**50**:498-508.