

Endoscopic management of early gastric cancer: endoscopic mucosal resection or endoscopic submucosal dissection: data from a Japanese high-volume center and literature review

Noriya Uedo, Yoji Takeuchi, Ryu Ishihara

Osaka Medical Center for Cancer and Cardiovascular Diseases, Osaka, Japan

Abstract

As detection of early gastric cancer (EGC) has improved, endoscopic mucosal resection (EMR) has been adopted as a treatment option for small intramucosal carcinoma. Endoscopic submucosal dissection (ESD) has enabled high *en bloc* resection rate for small and large lesions, as well as those with scarring. Moreover, the specimens obtained by ESD facilitate precise histological assessment of curability compared with the piecemeal specimens obtained by EMR. Accordingly, ESD has been established as a standard treatment for management of EGC in Japan. The long-term outcome of endoscopic management of EGC is based on: a) the accuracy of endoscopic diagnosis which defines the optimal treatment; b) endoscopist's expertise on methods for tumor removal (currently techniques of ESD); c) precise histological assessment of the resected specimen for curability; and d) surveillance endoscopy for early detection of metachronous multiple cancer. Efforts to establish a standardized protocol for practice and training can accelerate dissemination of gastric ESD in regions where gastric cancer is highly prevalent, and may help endoscopists worldwide to adopt this technique for other organs in the digestive tract.

Keywords early gastric cancer, endoscopic mucosal resection, endoscopic submucosal dissection
Ann Gastroenterol 2012; 25 (4): 281-290

Introduction

Gastric cancer is currently the fourth most common malignancy and the second most common cause of cancer deaths worldwide. Half the global totals occur in Eastern Asia, where the highest mortality rates are expected (28.1 per 100,000 in men, 13.0 per 100,000 in women) [1]. In Japan, early detection and treatment are considered to be effective strategies in reducing mortality from gastric cancer. Thus, many efforts have been made on screening and accurate detection of early gastric cancer (EGC).

Department of Gastrointestinal Oncology, Osaka Medical Center for Cancer and Cardiovascular Diseases, Osaka, Japan
Endoscopic Learning and Training Center, Osaka Medical Center for Cancer and Cardiovascular Diseases, Osaka, Japan

Conflict of Interest: None

Correspondence to: Noriya Uedo, Department of Gastrointestinal Oncology, Endoscopic Training and Learning Center, Osaka Medical Center for Cancer and Cardiovascular Diseases, 1-3-3 Nakamichi, Higashinari-ku, Osaka 537-8511, Japan, Tel.: +81 66972 1181; Fax: +81 6 6981 4067, e-mail: uedou-no@mc.pref.osaka.jp

Received 14 April 2012; accepted 12 June 2012

Definition of early gastric cancer

EGC was first defined in 1962 by the Japanese Society of Gastroenterological Endoscopy as adenocarcinoma confined to the mucosa or submucosa irrespective of lymph node involvement [2]. The need for such a definition was based on the observation that this type of gastric cancer has a favourable prognosis; 5-year survival rates are >95%. With the increase in the detection rate of EGC throughout the country, the Japanese national records show that the percentage of EGC among resected cases was 40% in 1985. Recently, the number of cases of EGC exceeded that of advanced cancer in some centers.

The fact that lymph node invasion is uncommon explains the good prognosis in EGC. The presence of lymph node metastasis is closely related to depth of local invasion. With submucosal invasion, lymph nodes are involved in 15-20% of cases, whereas when lesions are confined to the mucosa, lymph node involvement is uncommon ($\leq 3\%$) [3]. Advances on the efficacy of EGC screening has increased detection of small intramucosal carcinoma. Do all patients with intramucosal EGC require gastrectomy with lymph node dissection? If lymphatic spread has been ruled out as far as possible, local therapy with endoscopic resection would be a reasonable approach in selected cases.

Indications of endoscopic treatment for early gastric cancer

Endoscopic resection for EGC is indicated in patients with negligible risk of lymph node metastasis. Although lymph node metastasis of intramucosal EGC is rare, it certainly occurs. Lymph node-positive intramucosal cancers are usually macroscopically depressed, ulcerated or scarred lesions which are commonly large in size and of the undifferentiated type [4]. Conversely, patients with small (≤ 2 cm) differentiated intramucosal carcinoma without ulceration or scarring have a low risk of lymph node metastasis (Table 1). Accordingly, the Japanese gastric cancer treatment guidelines [5] states that differentiated adenocarcinoma without ulcerative findings, of which the depth of invasion is clinically diagnosed as intramucosal and the diameter is ≤ 2 cm, is a "guideline-indication" for endoscopic resection (Table 2). In addition, data from two large Japanese cancer centers indicate that lymph node metastasis is absent in the following lesions [6-8]: a) differentiated intramucosal carcinoma, was a) differentiated intramucosal carcinoma, was >2 cm in size, without ulceration or scarring; b) differentiated intramucosal carcinoma, ≤ 3 cm

in size, with ulceration or scarring; and c) undifferentiated intramucosal carcinoma, ≤ 2 cm in size, without ulceration or scarring (Table 1). Hence, these lesions were regarded as "expanded indications" for endoscopic resection (Table 2).

Method of endoscopic tumor resection, endoscopic mucosal resection and endoscopic submucosal dissection

EMR was first developed in 1984 to obtain large specimens of gastric mucosa for diagnosis of chronic gastritis [9]. Eventually, EMR was used for endoscopic removal of intramucosal carcinoma. EMR is superior to ablation techniques such as argon plasma coagulation, photodynamic therapy or radiofrequency ablation, because it permits complete endoscopic treatment which can be assessed by the histological findings on the retrieved specimen.

The strip biopsy EMR method, using double-channel videoendoscopy, involves: injection of physiological saline into the submucosa to lift the mucosal layer away from the

Table 1 Lymph node metastasis rate of early gastric cancer

Depth	Ulcer or scar	Histological type			
		Differentiated		Undifferentiated	
		≤ 2 cm*	>2 cm*	≤ 2 cm	>2 cm
Mucosa	(-)	0% (0-0.8%) 0/437	0% (0-0.6%) 0/493	0%** (0-0.96%) 0/310	5.0%** (2.9-7.0%) 21/423
	(+)	0% (0-0.6%) 0/488	3.0% (1.5-6.1%) 7/230		5.9%** (4.6-7.1%) 84/1430
Submucosa (≤ 500 μ m)		0% (0-2.0%) 0/145	2.6% (0.3-9.0%) 2/78		10.6%* (5.0-19.2%) 9/85

*Data are derived from references 6, 8; **Data are derived from reference 7

Table 2 Indication for endoscopic mucosal resection/ endoscopic submucosal dissection according to endoscopic finding

	Depth of invasion	Histology	Ulcer or scar	Size
Guideline indication	Intramucosal	Differentiated type	(-)	≤ 2 cm
	=	=	=	>2 cm
Expanded indication	=	=	(+)	≤ 3 cm
	=	Undifferentiated type	=	=

=: same as guideline-indication

submucosa (Fig. 1A); passing of a grasping forceps through the snaring wire and grasping the proximal margin of the tumor (Fig. 1B); pulling the grasping forceps to draw the lesion into the snaring wire (Fig. 1C); and cutting (Fig. 1D). *En bloc* resection is always attempted. However, one of the main drawbacks of EMR is that the size of the removable mucosa is limited by size of the snare. Moreover, it is sometimes difficult to remove the intended area precisely with EMR. Thus, when the lesions cannot be resected *en bloc* and part of the tumor or suspicious area remains, additional EMR should be performed at the same time. Large tumors which cannot be resected *en bloc* are removed piecemeal which makes difficult to assess completion and curability of the resection by histopathology and increases the incidence of residual tumor.

The original form of ESD was developed in the mid-1980s by Hirao *et al* [10]. They used a needle knife to incise the mucosa around a lesion and a snare to remove the area of mucosa including the lesion. This method did not become popular in contrast to strip biopsy EMR because of the complicated nature of the procedure, which demands high expertise and carries a high risk of bleeding and perforation. In late 1990, Hosokawa *et al* developed a new endoscopic electrosurgical knife that has a small insulated ceramic ball on its tip to prevent perforation (insulated-tip knife, IT knife, KD-610L; Olympus Medical Systems, Tokyo, Japan)

[11]. Later on, Ono *et al* developed a technique of ESD using the IT knife [12]. This ESD technique consists of marking the margins of the area to be removed with the utilization of dye-spray chromoendoscopy (Fig. 2A, B); injection of a solution outside the marking dots (Fig. 2C); mucosal incision outside the marking dots with an IT knife (Fig. 2D); additional injection into the submucosa underneath the isolated area to achieve sufficient mucosal elevation (Fig. 2E); submucosal dissection with the IT knife (Fig. 2F, G); and retrieval of the specimen (Fig. 2H) [13]. The Intelligent Cut and Coagulation 200 (ICC-200; ERBE Elektromedizin GmbH, Tübingen, Germany) or VIO 300D (ERBE) was currently used as an electrical surgical unit in our endoscopy unit; the output settings are summarized in Table 3. After the removal of the lesion, the mucosal defect is washed out repeatedly and any adherent clots or suspicious protrusions are coagulated with a coagulation forceps to avoid delayed hemorrhage. With this method, the indicated mucosal lesion can be theoretically removed *en bloc* even it is large or scarred. Refinements of equipment or accessories, such as development of various knives (Fig. 3) [14-16], or use of a transparent hood or water-jet endoscope [17], have been carried on to improve practice of ESD. The knives that are used for gastric ESD are basically divided into two types. For one type, tip of the knife is covered with insulating material and a blade proximal to the tip is

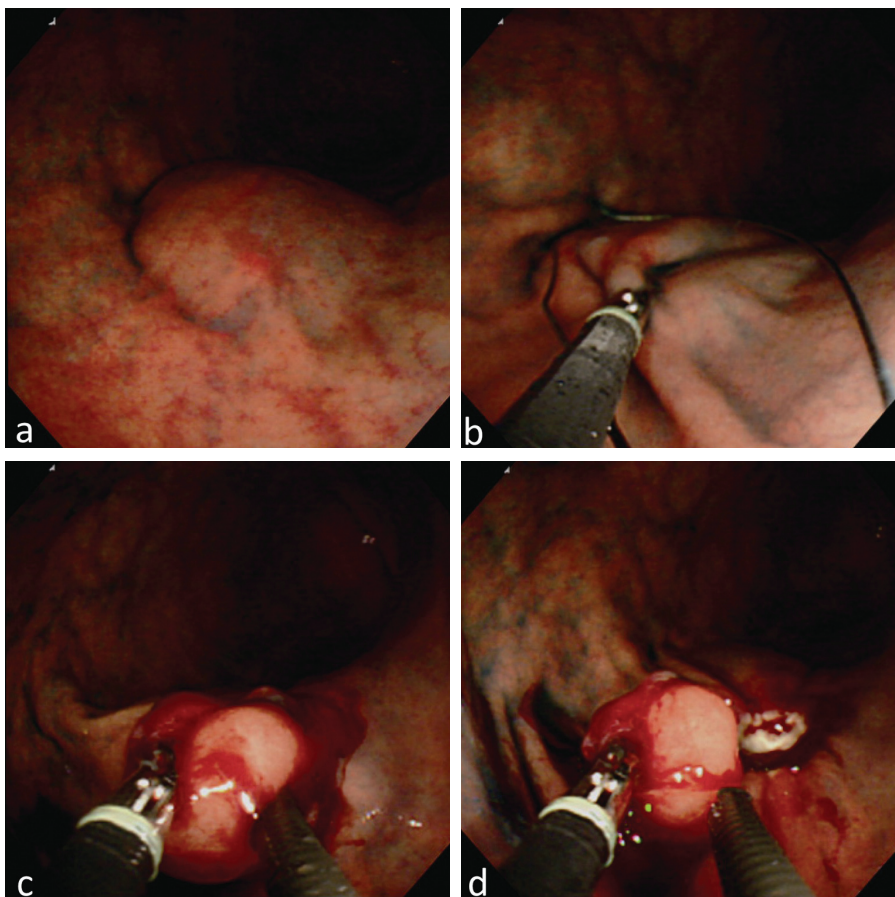


Figure 1 Method of strip biopsy endoscopic mucosal resection. (A) Injection of physiological saline; (B) grasping a lesion with forceps passed through a snare wire; (C) closing the snare; (D) cutting

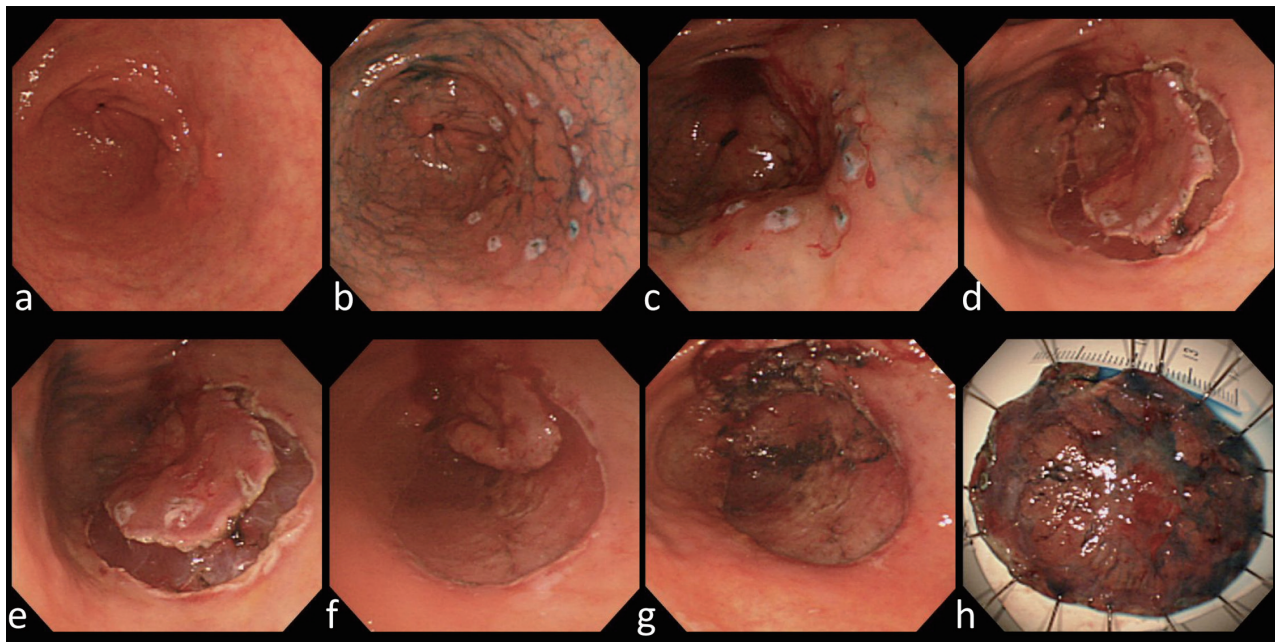


Figure 2 Method of endoscopic submucosal dissection. (A-B) Marking under chromoendoscopy; (C) solution injection outside marking; (D) circumferential mucosal incision; (E) solution injection beneath the lesion; (F-G) submucosal dissection; (H) retrieval of resected specimen

used for mucosal incision and submucosal dissection e.g. IT knife or SAFE knife (Fujifilm Medical Systems, Tokyo, Japan). This type of knife is safe because insulating material prevents perforation, although it demands characteristic manipulation for the procedures. Another type is the device that uses the tip of the knife for mucosal incision and submucosal dissection, such as the Triangle-tipped (KD-640L, Olympus Medical Systems), Hook (KD-620LR, Olympus Medical Systems), Dual (KD-650L, Olympus Medical Systems) and Flush (DK2618JN, Fujifilm Medical Systems) knife. Mucosal incision and submucosal dissection by using the tip of the knife is basically carried out under observation, thus the maneuver is easier than that of IT knife. However, careful manipulation to avoid perforation is necessitated for this type of knives. The Flush knife can emit a jet of water from the tip of its sheath

to rinse mucus and blood clots and enables saline injection into the submucosa, thereby bypassing the need to change endoscopic devices [18].

Pretreatment diagnosis

Compared to gastric surgical resection, the extent and depth of the tumor should be carefully assessed before ESD because only superficial lesions can be endoscopically removed, and the risk of lymph node metastasis is closely associated with size and depth of EGC. The types of tumor are classified according to the Japanese classification of gastric carcinoma [19,20]: type 0 I (protruded); type 0 IIa (slightly elevated);

Table 3 Settings of electrosurgical unit

Procedure	Device	ICC200	VIO 300D
Marking	Needle knife	Forced 20 W	Forced 20 W, Effect 2
Mucosal incision	IT knife or Needle knife	Endo-cut 80-120 W, Effect 3	Endo-cut I, Effect 3, Cut duration 2, Cut interval 3
Submucosal dissection	IT knife	Forced coagulation 50 W	Swift coagulation 100 W, Effect 4
	IT knife (Fibrous submucosal tissue)	Endo-cut 80-120 W, Effect 3	Endo-cut I, Effect 3, Cut duration 2, Cut interval 3
Hemostasis	IT knife (small vessel)	Forced coagulation 50 W	Swift coagulation 100 W, Effect 4
	Hemostatic forceps (large vessel)	Soft coagulation 80 W	Soft coagulation 80 W, Effect 6

IT, insulated-tip




Figure 3 Representative devices used for gastric endoscopic submucosal dissection. (A) Insulation-tipped diathermic knife-2; (B) ball-tipped flush knife; (C) hook knife; (D) hemostatic forceps (Coagrasper)

type 0 IIb (flat); type 0 IIc (slightly depressed); or type 0 III (excavated). The tumor extent is basically determined using chromoendoscopy with 0.2% indigo carmine according to differences in color, height, and areae gastricae patterns between cancer and non-cancer mucosa. Nagahama *et al* indicated that around 80% of early gastric cancers were clearly delineated with chromoendoscopy but the remainder of the tumors showed unclear margin. Narrow band imaging, when it is used with magnifying endoscopy, successfully determined tumor boundary in more than 70% of cases that showed unclear margin in chromoendoscopy [21]. Magnifying narrow band imaging adds useful information for diagnosis of tumor extent but solely a small area of mucosa is observable, therefore chromoendoscopy is still essential for diagnosis of tumor extent because it enables us to evaluate gross appearance of tumors [22]. The depth of the tumor is assessed mainly by morphological features of conventional endoscopy and chromoendoscopy. In the case of inconclusive findings, endoscopic ultrasound (EUS) with a standard echoendoscope (GIF-UMQ200; Olympus Medical Systems) or a miniprobe (UM-2R, UM-3R; Olympus Medical Systems) is used. 20 MHz is recommended for assessment of tumor depth and 7.5 MHz is used to observe extramural lymph nodes. The diagnostic

accuracy of conventional endoscopic findings for tumor depth by experienced endoscopists is comparable to EUS [23], which has a tendency to overestimate tumor depth [24], leading to unnecessary surgery in some cases. Histological analysis of resected specimens provides the most accurate assessment of the tumor depth and lymphatic or venous involvement, which define requirement for surgery. Therefore, when all attempts are made at pretreatment diagnosis, and there is a possibility of intramucosal carcinoma, with no definitive findings of massive submucosal invasion, ESD is usually carried out after explaining the possibility of additional surgery.

Assessment of curability by histology

Retrieved specimens are pinned onto hard gum plates and immersed in 20% formalin. Piecemeal-resected specimens were reconstituted to the greatest extent possible. The fixed specimens are serially sectioned at 2-mm intervals for histological examination. According to the Japanese classification of gastric carcinoma [19], histological type, depth of invasion, presence of ulcerative change, lymphatic and venous involvement, and tumor involvement to the horizontal (mucosal) and vertical (submucosal) margins are evaluated to estimate the curability of the resection. The lesion is considered to be curative when the completely resected specimen satisfies the following criteria [5]. No tumor invasion to horizontal and vertical margins, and no lymphatic or venous involvement, and: a) differentiated intramucosal tumor without ulceration or scarring; b) differentiated intramucosal adenocarcinoma with ulceration or scarring, tumor ≤ 3 cm; c) differentiated adenocarcinoma with minimal submucosal invasion (SM1: ≤ 500 μm from the muscularis mucosae), ≤ 3 cm; and d) undifferentiated intramucosal adenocarcinoma without ulceration or scarring, ≤ 2 cm (Table 4). When a differentiated carcinoma shows a positive horizontal (mucosal) margin but satisfies all the other curable criteria, repeated ESD could be proposed for residual tumor or when local recurrence is found during close observation because it carries a very low risk of harboring lymph node metastasis [25]. In the case of possible lymph node metastasis, demonstrated by submucosal invasion or lymphatic or venous involvement, patients are subjected to gastric resection with lymph node dissection [26] (Fig. 4).

Table 4 Criteria for curative resection in histological findings

Predominant histological type	Tumor invasion to resected margin*	Lymphatic or venous involvement	Depth of invasion	Ulcerative finding	Size
Differentiated	(-)	(-)	Intramucosal	(-)	Any
			Intramucosal	(+)	≤ 3 cm
			Minimal submucosal invasion	(-)	≤ 3 cm
Undifferentiated type			Intramucosal	(-)	≤ 2 cm

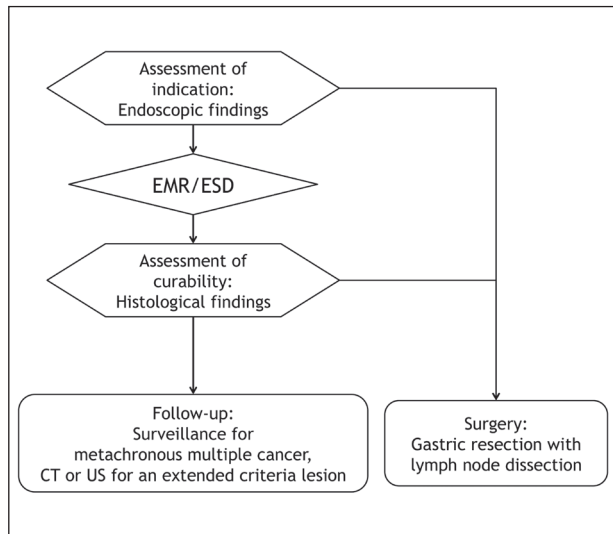


Figure 4 Flow of endoscopic management of early gastric cancer with endoscopic mucosal resection (EMR)/endoscopic submucosal dissection (ESD). It consists of pretreatment diagnosis, EMR/ESD procedure, histological assessment and endoscopic surveillance

Treatment outcomes, endoscopic mucosal resection versus endoscopic submucosal dissection

Treatment outcomes of EMR and ESD were evaluated with reference to six previous studies [27-32] and our own experience. Moreover, differences in treatment outcomes between EMR and ESD with regard to the different indication categories were investigated in our data. During 1996-2008, 2190 EGCs were treated with endoscopic resection in Osaka Medical Center for Cancer and Cardiovascular Diseases. Of these, 75 lesions in the operated stomach were excluded. Seven lesions could not be retrieved and one lesion was not found to be carcinoma in retrieved specimen, leaving 882 lesions that were treated with EMR and 1233 lesions with ESD for analysis. The resected lesions were retrospectively classified into the following indication-categories according to the endoscopic finding before treatment: the guideline-indication (≤ 2 cm differentiated adenocarcinoma without ulceration or scarring, for which the depth of invasion was estimated to be intramucosal, $n=1388$); >2 cm differentiated intramucosal carcinoma without ulceration or scarring ($n=378$); ≤ 3 cm differentiated intramucosal carcinoma with ulceration or scarring ($n=210$); and ≤ 2 cm undifferentiated intramucosal carcinoma without ulceration or scarring ($n=73$). Fifty-eight lesions that did not fulfill the indication criteria were treated palliatively because of patients' comorbidity or old age (Fig. 5).

Outcomes of each method in the literature review and our center are summarized in Table 5. The rate of *en bloc* resection that was defined as one-piece resection without tumor invasion to the resected margin was 50-70% for EMR, whereas it was almost 90-95% for ESD. The difference in *en bloc* resection rate was also higher for ESD than EMR in our experience, and the

difference in *en bloc* resection rate between EMR and ESD was more evident for expanded indication lesions (EMR: 20-40% vs. ESD: 75-85%) than for guideline-indication lesions (EMR: 64% vs. ESD: 95%, Fig. 6). When histological findings of the resected specimens fulfilled the curable criteria listed in Table 4, the resection was regarded as curative. Curative resection rates of EMR and ESD were 55-60% and 75-95%, respectively (Table 5). The discrepancy between *en bloc* and curative resection rates for ESD lesions was mainly caused by lesions that had submucosal invasion and/or lymphatic involvement. Non-curative resection rate for ESD for guideline-indication lesions was only 10%, whereas that for lesions >2 cm, lesions with scarring and undifferentiated lesions was 33%, 39% and 68%, respectively, and subsequent surgery was recommended (Fig. 7). Prior to the procedure, all patients should be informed for the possibility of additional surgery following ESD. This risk is higher for those fulfilling the expanded indications for endoscopic resection.

Complications

Delayed bleeding and perforation are the major complications of endoscopic resection for EGC. Delayed bleeding occurs in 2.5-3.9% of EMR patients and 1.8-16% of ESD patients (Table 4). ESD has a higher rate of delayed bleeding than EMR and delayed bleeding is more frequent for expanded indication lesions compared to guideline-indication lesions (Fig. 8). Routine coagulation of all visible vessels at the post-ESD mucosal defect decreases the rate of delayed hemorrhage [33] and is performed as standard practice. Administration of proton pump inhibitors reduces incidence of delayed bleeding compared to

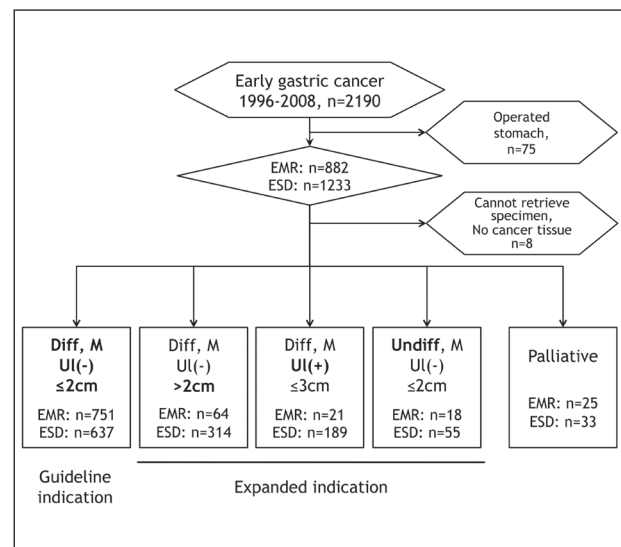


Figure 5 Participant flow of outcome analysis in the Osaka Medical Center for Cancer and Cardiovascular Diseases. EMR, endoscopic mucosal resection; ESD, endoscopic submucosal dissection

Table 5 Outcomes of endoscopic resection, endoscopic mucosal resection versus endoscopic submucosal dissection

	Literature review		OMCC	
	EMR	ESD	EMR (n=879)	ESD (n=1228)
<i>En bloc</i> resection rate	56–73%	88–95%	58%	89%
Curative resection rate	61%	74–95%	56%	76%
Complication rate				
Delayed bleeding	3.9%	1.8–16%	2.5%	6.8%
Perforation	0.5–3.2%	1.2–9.7%	1.1%	3.1%

OMCC, Osaka Medical Center for Cancer and Cardiovascular Diseases; EMR, endoscopic mucosal resection; ESD, endoscopic submucosal dissection

administration of histamine 2-receptor antagonists [34].

Rates of perforation during ESD are higher (1.2-9.7%) than those in EMR (0.5-3.2%) (Table 5). In our data, perforation during EMR only occurs in lesions with fibrosis in the submucosa caused by ulceration, scarring or tumor invasion, whereas perforation during ESD has been observed in 2-5% of cases in all indication categories (Fig. 9). Significant risk factors for perforation during gastric ESD are tumor location (upper third), tumor size (>2 cm) and experience of an institution (lesions treated in early period) [35]. Most intraoperative perforations can be managed conservatively with endoscopic clipping [36], but surgical intervention is required for delayed perforation [37]. In our experience, emergency surgery was needed in 6% (3 of 50, 95% CI 0-13%) of cases with intraoperative perforation [35] and 83% (5 of 6, 95% CI 54-100%) of those with delayed perforation, respectively [37].

Stricture can occur after >75% resection of antral, prepyloric or cardiac lesions [38,39]. Endoscopic balloon dilation is effective for stricture, but one should be careful

not to cause perforation and surgical intervention is required in an ineffective case.

Surveillance for metachronous multiple cancers

Compared to gastric resection, endoscopic treatment leaves the stomach that contains premalignant mucosal lesions such as atrophic gastritis, intestinal metaplasia and dysplasia. Hence, multiple metachronous cancers develop after endoscopic resection for EGC in 5.9% of cases within 3 years, and annual endoscopic surveillance is recommended [40]. Recently, the prophylactic effect of *H. pylori* eradication on the incidence of metachronous gastric cancer after endoscopic resection of EGC has been demonstrated in a randomized controlled trial (OR 0.35 in favor of eradication therapy) [41]. However, atrophic gastritis and intestinal metaplasia usually

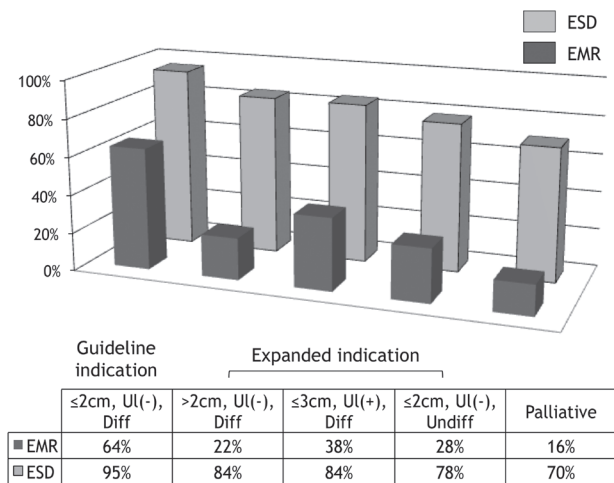


Figure 6 *En bloc* resection rate of endoscopic mucosal resection and endoscopic submucosal dissection in our institution
ESD, endoscopic submucosal dissection; EMR, endoscopic mucosal resection

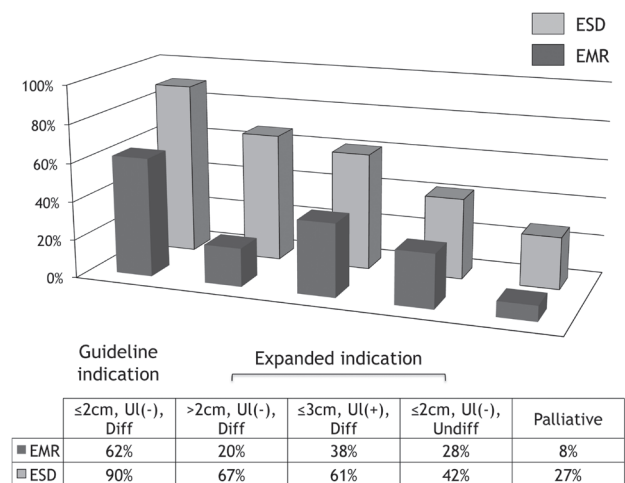


Figure 7 Curable resection rate of endoscopic mucosal resection and endoscopic submucosal dissection in our institution
ESD, endoscopic submucosal dissection; EMR, endoscopic mucosal resection

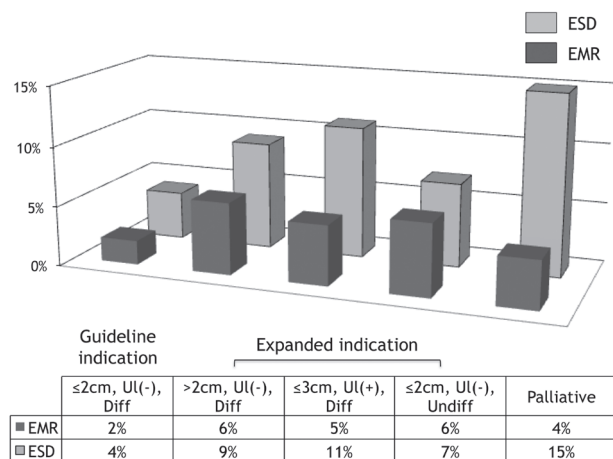


Figure 8 Delayed bleeding rate of endoscopic mucosal resection and endoscopic submucosal dissection in our institution
ESD, endoscopic submucosal dissection; EMR, endoscopic mucosal resection




Figure 9 Perforation rate of endoscopic mucosal resection and endoscopic submucosal dissection in our institution
ESD, endoscopic submucosal dissection; EMR, endoscopic mucosal resection

continue after successful eradication of *H. pylori* in patients undergoing EMR or ESD for EGC [42]. Therefore, surveillance endoscopy to detect metachronous multiple cancers is essential for management of EMR and ESD patients, even if they have received *H. pylori* eradication therapy, because such continuous atrophy and intestinal metaplasia can be the background for further metachronous EGC in these patients [43].

Long-term outcome

Excellent long-term outcomes after gastric EMR and ESD (5-year survival rate >90%) have been reported from several institutions (Table 6) [31,44-46]. All these single-center

retrospective studies refer to a median follow-up <5 years after endoscopic excision. EGC has a long natural history [47] and incidence of disease-related death is low, therefore, long-term survival should be investigated with a high follow-up rate. Moreover, intent-to-treat analysis in a prospective cohort study is desirable. The Japan Clinical Oncology Group is currently conducting a multicenter prospective cohort study investigating 5-year survival rate of all ESD patients who had EGC that fulfilled the expanded indication criteria, and the result is pending.

Technical aspects and learning of gastric endoscopic submucosal dissection

Despite good outcome results of ESD for EGC, it

Table 6 Long-term survival after endoscopic resection

Author	Method of endoscopic resection	Study design	Institution	Number of study sample	Median observation period (months)	5-year survival rate		Follow-up rate
						Overall	Gastric cancer	
Uedo	EMR	Retrospective	Single	131	58	84%	99%	95%
Oda	EMR/ESD	Retrospective	Multi	655	38	99%*	ND	ND
Goto	ESD	Retrospective	Single	276	36	96%	100%	76%
Isomoto	ESD	Retrospective	Multi	551	30	97%	100%	85%
Gotoda	ESD	Retrospective	Single	1485	44	92% (guideline indication), 93% (expanded indication)	ND	100%

*: Data for 3-year survival rate
ND, not described; EMR, endoscopic mucosal resection; ESD, endoscopic submucosal dissection

demands greater expertise and longer procedure time, and is associated with a higher risk of complications compared to EMR [48]. It is suggested that experienced endoscopists who are familiar with EMR or other therapeutic procedures could gain early proficiency after 30 cases [13,49]. This may indicate that experienced endoscopists could improve their skill by themselves if they have proper information or guidance, that is, good textbooks, live workshops, or DVDs about actual techniques of ESD. Yamamoto *et al* have shown that trainee endoscopists could perform gastric ESD under appropriate supervision of an experienced endoscopist, and they could efficiently learn the actual steps and how to troubleshoot complications through the supervised practice [50]. This suggests that, as well as other endoscopic procedures, even highly advanced endoscopic technique of ESD can be transmitted to trainees. Experienced endoscopists who have developed the appropriate endoscopic skills required for ESD can become good trainers for other endoscopists.

Gastric ESD is currently performed by many endoscopists in tertiary centers and secondary care hospitals (50 to >100 hospitals in Japan, Korea and China, with 1-10 endoscopists who perform ESD in each hospital) in East Asian countries [51]. In western countries, a European survey in 2010 reported that only 20 centers performed gastric ESD, which was mostly performed by a single endoscopist in each center at that time [52]. The difference in case volume is mainly caused by the difference in incidence of EGC, and this could affect learning speed and skill. Kim *et al* has suggested that, in an area with low volume of EGC, trials should be carried out *ex vivo* or in live animal models to improve learning [53].

Conclusions

- EMR had been adopted as a treatment option for small intramucosal carcinoma but ESD enabled high *en bloc* resection rates for small and large lesions, as well as those with scarring. Consequently, endoscopic resection has been established as a standard treatment for management of EGC in Japan.
- Improvement in ESD technique for tumor removal is pivotal for management of EGC but there are other important steps to achieve excellent long-term outcome such as the accuracy of endoscopic diagnosis which defines the optimal treatment; precise histological assessment of the resected specimen for curability; and surveillance endoscopy for early detection of metachronous multiple cancer.
- Efforts to establish a standardized protocol for practice and training can accelerate dissemination of gastric ESD in regions where gastric cancer is highly prevalent, and may help endoscopists worldwide to adopt this technique for other organs in the digestive tract.

References

1. Ferlay J, Shin HR, Bray F, Forman D, Mathers C, Parkin DM. Estimates of worldwide burden of cancer in 2008: GLOBOCAN 2008. *Int J Cancer* 2010;**127**:2893-2917.
2. Murakami T. Pathomorphological diagnosis. Definition and gross classification of early gastric cancer. *Gann Monogr Cancer Res* 1971;**11**:53-55.
3. Sano T, Kobori O, Muto T. Lymph node metastasis from early gastric cancer: endoscopic resection of tumour. *Br J Surg* 1992;**79**:241-244.
4. Tsuji N, Ishiguro S, Suzuki N, et al. Risk factors for lymph node metastasis of intramucosal gastric cancer: a case-control study. *Gastroenterol Endosc* 1999;**41**:1059-1065.
5. Japanese Gastric Cancer Association. Japanese gastric cancer treatment guidelines 2010 (ver. 3). *Gastric Cancer* 2011;**14**:113-123.
6. Gotoda T, Yanagisawa A, Sasako M, et al. Incidence of lymph node metastasis from early gastric cancer: estimation with a large number of cases at two large centers. *Gastric Cancer* 2000;**3**:219-225.
7. Hirasawa T, Gotoda T, Miyata S, et al. Incidence of lymph node metastasis and the feasibility of endoscopic resection for undifferentiated-type early gastric cancer. *Gastric Cancer* 2009;**12**:148-152.
8. Japanese Gastric Cancer Association. Japanese gastric cancer treatment guidelines 2004 (ver. 2). available at <http://www.jgca.jp/PDFfiles/GL2004VER2.PDF>
9. Tada M, Shimada M, Murakami F, et al. Development of strip-off biopsy. *Gastroenterol Endosc* 1984;**26**:833-839.
10. Hirao M, Masuda K, Ananuma T, et al. Endoscopic resection of early gastric cancer and other tumors with local injection of hypertonic saline-epinephrine. *Gastrointest Endosc* 1988;**34**:264-269.
11. Ohkuwa M, Hosokawa K, Boku N, Ohtu A, Tajiri H, Yoshida S. New endoscopic treatment for intramucosal gastric tumors using an insulated-tip diathermic knife. *Endoscopy* 2001;**33**:221-226.
12. Ono H, Kondo H, Gotoda T, et al. Endoscopic mucosal resection for treatment of early gastric cancer. *Gut* 2001;**48**:225-229.
13. Takeuchi Y, Uedo N, Iishi H, et al. Endoscopic submucosal dissection with insulated-tip knife for large mucosal early gastric cancer: a feasibility study (with videos). *Gastrointest Endosc* 2007;**66**:186-193.
14. Oyama T, Tomori A, Hotta K, et al. Endoscopic submucosal dissection of early esophageal cancer. *Clin Gastroenterol Hepatol* 2005;**3**:S67-S70.
15. Ono H, Hasuike N, Inui T, et al. Usefulness of a novel electro-surgical knife, the insulation-tipped diathermic knife-2, for endoscopic submucosal dissection of early gastric cancer. *Gastric Cancer* 2008;**11**:47-52.
16. Toyonaga T, Man-I M, Fujita T, et al. The performance of a novel ball-tipped Flush knife for endoscopic submucosal dissection: a case-control study. *Aliment Pharmacol Ther* 2010;**32**:908-915.
17. Tatsumi K, Uedo N, Ishihara R, et al. A water-jet videoendoscope may reduce operation time of endoscopic submucosal dissection for early gastric cancer. *Dig Dis Sci* 2012;**57**:2122-2129.
18. Takeuchi Y, Uedo N, Ishihara R, et al. Efficacy of an endo-knife with a water-jet function (flushknife) for endoscopic submucosal dissection of superficial colorectal neoplasms. *Am J Gastroenterol* 2010;**105**:314-322.
19. Japanese classification of gastric carcinoma: 3rd English edition. Japanese Gastric Cancer Association. *Gastric Cancer* 2011;**14**:101-112.
20. Participants in the Paris Workshop. The Paris endoscopic classification of superficial neoplastic lesions: esophagus, stomach, and colon: November 30 to December 1, 2002. *Gastrointest Endosc* 2003;**58**(6 Suppl):S3-S43.

21. Nagahama T, Yao K, Maki S, et al. Usefulness of magnifying endoscopy with narrow-band imaging for determining the horizontal extent of early gastric cancer when there is an unclear margin by chromoendoscopy (with video). *Gastrointest Endosc* 2011;**74**:1259-1267.
22. Uedo N, Fujishiro M, Goda K, et al. Role of narrow band imaging for diagnosis of early-stage esophagogastric cancer: current consensus of experienced endoscopists in Asia-Pacific region *Digestive Endoscopy* 2011;**23**(Suppl. 1):58-71.
23. Choi J, Kim SG, Im JP, Kim JS, Jung HC, Song IS. Comparison of endoscopic ultrasonography and conventional endoscopy for prediction of depth of tumor invasion in early gastric cancer. *Endoscopy* 2010;**42**:705-713.
24. Yanai H, Noguchi T, Mizumachi S, et al. A blind comparison of the effectiveness of endoscopic ultrasonography and endoscopy in staging early gastric cancer. *Gut* 1999;**44**:361-365.
25. Yokoi C, Gotoda T, Hamanaka H, Oda I. Endoscopic submucosal dissection allows curative resection of locally recurrent early gastric cancer after prior endoscopic mucosal resection. *Gastrointest Endosc* 2006;**64**:212-218.
26. Oda I, Gotoda T, Sasako M, et al. Treatment strategy after non-curative endoscopic resection of early gastric cancer. *Br J Surg* 2008;**95**:1495-1500.
27. Oda I, Gotoda T, Hamanaka H, et al. Endoscopic submucosal dissection for early gastric cancer: technical feasibility, operation time and complications from a large consecutive series. *Dig Endosc* 2005;**17**:54-58.
28. Watanabe K, Ogata S, Kawazoe S, et al. Clinical outcomes of EMR for gastric tumors: historical pilot evaluation between endoscopic submucosal dissection and conventional mucosal resection. *Gastrointest Endosc* 2006;**63**:776-782.
29. Oka S, Tanaka S, Kaneko I, et al. Advantage of endoscopic submucosal dissection compared with EMR for early gastric cancer. *Gastrointest Endosc* 2006;**64**:877-883.
30. Oda I, Saito D, Tada M, et al. A multicenter retrospective study of endoscopic resection for early gastric cancer. *Gastric Cancer* 2006;**9**:262-270.
31. Chung IK, Lee JH, Lee SH, et al. Therapeutic outcomes in 1000 cases of endoscopic submucosal dissection for early gastric neoplasms: Korean ESD Study Group multicenter study. *Gastrointest Endosc* 2009;**69**:1228-1235.
32. Isomoto H, Shikuwa S, Yamaguchi N, et al. Endoscopic submucosal dissection for early gastric cancer: a large-scale feasibility study. *Gut* 2009;**58**:331-336.
33. Takizawa K, Oda I, Gotoda T, et al. Routine coagulation of visible vessels may prevent delayed bleeding after endoscopic submucosal dissection--an analysis of risk factors. *Endoscopy* 2008;**40**:179-183.
34. Uedo N, Takeuchi Y, Yamada T, et al. Effect of a proton pump inhibitor or an H2-receptor antagonist on prevention of bleeding from ulcer after endoscopic submucosal dissection of early gastric cancer: a prospective randomized controlled trial. *Am J Gastroenterol* 2007;**102**:1610-1616.
35. Ohta T, Ishihara R, Uedo N, et al. Factors predicting perforation during endoscopic submucosal dissection for gastric cancer. *Gastrointest Endosc* 2012;**75**:1159-1165.
36. Minami S, Gotoda T, Ono H, Oda I, Hamanaka H. Complete endoscopic closure of gastric perforation induced by endoscopic resection of early gastric cancer using endoclips can prevent surgery (with video). *Gastrointest Endosc* 2006;**63**:596-601.
37. Hanaoka N, Uedo N, Ishihara R, et al. Clinical features and outcomes of delayed perforation after endoscopic submucosal dissection for early gastric cancer. *Endoscopy* 2010;**42**:1112-1115.
38. Tsunada S, Ogata S, Mannen K, et al. Case series of endoscopic balloon dilation to treat a stricture caused by circumferential resection of the gastric antrum by endoscopic submucosal dissection. *Gastrointest Endosc* 2008;**67**:979-983.
39. Iizuka H, Kakizaki S, Sohara N, et al. Stricture after endoscopic submucosal dissection for early gastric cancers and adenomas. *Dig Endosc* 2010;**22**:282-288.
40. Nakajima T, Oda I, Gotoda T, et al. Metachronous gastric cancers after endoscopic resection: how effective is annual endoscopic surveillance? *Gastric Cancer* 2006;**9**:93-98.
41. Fukase K, Kato M, Kikuchi S, et al; Japan Gast Study Group. Effect of eradication of *Helicobacter pylori* on incidence of metachronous gastric carcinoma after endoscopic resection of early gastric cancer: an open-label, randomised controlled trial. *Lancet* 2008;**372**:392-397.
42. Shiotani A, Uedo N, Iishi H, et al. *H. pylori* eradication did not improve dysregulation of specific oncogenic miRNAs in intestinal metaplastic glands. *J Gastroenterol* 2012;**47**:988-998.
43. Hanaoka N, Uedo N, Shiotani A, et al. Autofluorescence imaging for predicting development of metachronous gastric cancer after *Helicobacter pylori* eradication. *J Gastroenterol Hepatol* 2010;**25**:1844-1849.
44. Uedo N, Iishi H, Tatsuta M, et al. Longterm outcomes after endoscopic mucosal resection for early gastric cancer. *Gastric Cancer* 2006;**9**:88-92.
45. Gotoda T, Iwasaki M, Kusano C, Seewald S, Oda I. Endoscopic resection of early gastric cancer treated by guideline and expanded National Cancer Centre criteria. *Br J Surg* 2010;**97**:868-871.
46. Goto O, Fujishiro M, Kodashima S, Ono S, Omata M. Outcomes of endoscopic submucosal dissection for early gastric cancer with special reference to validation for curability criteria. *Endoscopy* 2009;**41**:118-122.
47. Tsukuma H, Oshima A, Narahara H, Morii T. Natural history of early gastric cancer: a non-concurrent, long term, follow up study. *Gut* 2000;**47**:618-621.
48. Park YM, Cho E, Kang HY, Kim JM. The effectiveness and safety of endoscopic submucosal dissection compared with endoscopic mucosal resection for early gastric cancer: a systematic review and metaanalysis. *Surg Endosc* 2011;**25**:2666-2677.
49. Gotoda T, Friedland S, Hamanaka H, Soetikno R. A learning curve for advanced endoscopic resection. *Gastrointest Endosc* 2005;**62**:866-867.
50. Yamamoto S, Uedo N, Ishihara R, et al. Endoscopic submucosal dissection for early gastric cancer performed by supervised residents: assessment of feasibility and learning curve. *Endoscopy* 2009;**41**:923-928.
51. Uedo N, Jung HY, Fujishiro M, et al. Current situation of endoscopic submucosal dissection for superficial neoplasms in the upper digestive tract in east asian countries: a questionnaire survey. *Dig Endosc* 2012;**24** Suppl 1:124-128.
52. Ribeiro-Mourão F, Pimentel-Nunes P, Dinis-Ribeiro M. Endoscopic submucosal dissection for gastric lesions: results of an European inquiry. *Endoscopy* 2010;**42**:814-819.
53. Kim EY, Jeon SW, Kim GH. Chicken soup for teaching and learning ESD. *World J Gastroenterol* 2011;**17**:2618-2622.