

Gastroparesis in children

Efstratios Saliakellis^a, Maria Fotoulaki^b

Great Ormond Street Hospital, NHS Foundation Trust, London, UK; Aristotle University of Thessaloniki, Papageorgiou General Hospital, Thessaloniki, Greece

Abstract

Historically, gastroparesis is characterized by delayed gastric emptying of fluids and/or solids without evidence of a mechanical gastric outlet obstruction. To provide a thorough, evidence-based overview of the diagnosis, treatment, outcome and future advances for gastroparesis in children, a web search (PubMed, Cochrane Database of Systematic Reviews, EMBASE, Clinical Evidence) was performed. Original articles and reviews were identified, examined and included as appropriate. The prevalence of gastroparesis is vague in adults and unknown in children. It is suspected on the presence of symptoms indicating gastric dysmotility (nausea, vomiting, early satiety, postprandial fullness, failure to thrive, weight loss) and is confirmed on the demonstration of delayed gastric emptying. It can be assessed with various methods from which gastric emptying scintigraphy of a radiolabeled solid meal is considered as the golden standard. Therapeutic approaches include: dietary modifications, medical treatment (prokinetics, antiemetics, intrapyloric injection of botulinum toxin, enteral feeds via jejunostomy, total parenteral nutrition) and surgical interventions (laparoscopic placement of gastric pacemaker) aiming at alleviating symptoms and maintaining optimal nutritional status. Gastroparesis in children can be challenging to diagnose and treat. Specific protocols for the evaluation of gastric emptying and for a stepwise management are required to optimise future outcomes.

Keywords Gastroparesis, gastric emptying, children, gastric motility disorders

Ann Gastroenterol 2013; 26 (3): 204-211

Introduction

Symptoms such as abdominal pain, nausea, vomiting and early satiety are quite common in everyday pediatric clinical practice. However, when they persist the diagnostic approach can become challenging because the physician has to differentiate among various clinical entities that include gastroesophageal reflux, peptic ulcer disease, malformations of the upper gastrointestinal tract, gastroparesis and functional dyspepsia (FD).

By definition gastroparesis is a gastric motility disorder characterized by delayed gastric emptying (GE) in the absence of mechanical obstruction [1]. The gold standard for the diagnosis of gastroparesis is GE scintigraphy [2]. For adults

there is a consensus on the diagnostic approach and treatment of gastroparesis; the GE test is well standardized and the normal values for the latter are clearly defined [2-4]. On the contrary, there is no such position statement for the pediatric population. Furthermore, GE scintigraphy protocols vary across different institutions and lack normative values [5]. Additionally, only limited data are available on the epidemiology, etiology, pathophysiology, clinical presentation, treatment and outcome of gastroparesis in children [6,7].

The aim of this article is to systematically review the literature concerning the epidemiology, diagnosis and therapy of gastroparesis in the pediatric population including future perspectives in the overall management of this largely unknown entity.

Epidemiology

The epidemiology of gastroparesis is still not well defined either in adults or in children [4]. One study showed that 7-15% of the adult population had symptoms indicative of gastroparesis [8]; however, another study demonstrated that the age-adjusted prevalence of definite gastroparesis in adults per 100,000 population was 9.6 for men and 37.8 for women [9]. Unfortunately there are no data available on

^aDepartment of Pediatric Gastroenterology, Academy of Pediatric Gastroenterology, Great Ormond Street Hospital, NHS Foundation Trust, London, UK (Efstratios Saliakellis); ^b4th Department of Pediatrics, Medical School, Aristotle University of Thessaloniki, Papageorgiou General Hospital, Thessaloniki, Greece (Maria Fotoulaki)

Conflict of Interest: None

Correspondence to: Maria Fotoulaki, MD, PhD, 41, Alexandrou Michailidi, 54641, Thessaloniki, Greece, Tel.: +30 6944 949964, Fax: +30 2310 991538, e-mail: mfotoul@otenet.gr

Received 4 January 2013; accepted 14 February 2013

the prevalence of gastroparesis in children [10]. A recent retrospective study of a large cohort of pediatric patients revealed that there was almost equal distribution between females and males. The difference among genders increased with age, so that in patients older than 17 years almost two-thirds were females [10].

Etiology and pathophysiology

The integrity of gastric function relies on a fine coordination between the autonomic nervous system, smooth muscle cells and enteric neurons. Literally, any disease affecting the neuromuscular control of the stomach can lead to gastroparesis [11]. The classical teaching in adult gastroparesis has been that approximately one third of cases are related to type I or II diabetes mellitus [12]; one third is attributed to various causes including postsurgical conditions, neurological (e.g. Parkinson disease) [13], metabolic or gastrointestinal disorders and multisystemic diseases. Finally, one third is of unknown etiology, i.e. idiopathic [14].

In children, the majority of cases were considered either postviral or idiopathic [15]. Current literature reveals a predominance of idiopathic gastroparesis in children (70%), followed by drugs (18%) and postsurgical gastroparesis (12%). Additionally, a significant percentage (38.5%) presented concurrently with comorbidities (i.e. seizure disorders, cerebral palsy, developmental delay, prematurity) as well as with psychiatric disorders (28.4%) (e.g. attention deficit-hyperactivity disorder, anxiety, bipolar disorder, other behavioral problems) [10].

Drugs that could potentially cause delayed GE leading to gastroparesis include α -2 adrenergic agonists and tricyclic antidepressants which stimulate adrenergic receptors and thus decrease gastrointestinal motility. Also proton-pump inhibitors, antacids, H_2 receptor agonists, sucralfate, octreotide, β -adrenergic agonists, calcium channel blockers and diphenhydramine may delay GE leading to gastroparesis [16-20].

Viruses (rota virus, Epstein-Barr virus, cytomegalovirus) [15,21] have been implicated as causes of post-infectious gastroparesis. Although the exact mechanism of post-infectious gastroparesis is vague it seems that the infecting agent causes neuropathy by either direct damage of the autonomic ganglia or by indirect effect on the neurons via an immunologic or inflammatory response to the infection [22-24]. The post-infectious delayed GE is usually self-limited and resolves within 24 months [5,15].

Upper abdominal surgery (e.g. fundoplication for gastroesophageal reflux disease) or lung and heart transplantation can cause postsurgical gastroparesis for a number of reasons (e.g. vagal nerve injury leading to reduced antral contractions and pyloric spasticity or opportunistic viral infections due to immunosuppressive medications) [17,25].

Children with neurological conditions can develop gastroparesis possibly due to abnormal function of both the

central and enteric nervous system [26,27]. Dysfunction of the autonomic nervous system plays a key role in diabetes-associated gastroparesis (loss of interstitial cells of Cajal, atrophy of gastric smooth muscle) and also in other conditions (e.g. Hirschsprung's disease) [28,29]. Gastroparesis has also been described in premature neonates [30], children with eosinophilic gastrointestinal disease, cow's milk protein allergy, celiac disease, cystic fibrosis, chronic intestinal pseudo-obstruction [10] and autoimmune disorders (dermatomyositis, Crohn's disease) [31,32], renal disease [33], and after corrosive ingestion [34].

Table 2 summarizes the most frequent causes of childhood gastroparesis.

Clinical presentation

Recent data support that the mean age of presentation of gastroparesis is school-age with males predominating among infants and females among adolescents [5]. It is associated with upper gastrointestinal symptoms: vomiting appears as the most common (68%) followed by abdominal pain (51%), nausea (28%), weight loss (27%), early satiety (25%) and postprandial fullness (7%) [10]. However the correlation between the presence and severity of symptoms and the degree of delayed GE is poorly defined. One study in children with gastroparesis found no correlation between symptom severity and the degree of emptying delay [5], whereas another study demonstrated an association between the severity of delayed GE and the frequency of nausea and abdominal pain [10].

Over the years several tools have been proposed for the assessment of the quality of life in patients with gastroparesis. The Gastroparesis Cardinal Symptom Index (GCSI) is believed to be one of the most reliable and valid modalities. It allows better symptom reporting from patients, higher correlation between symptoms and GE time and quantification of symptoms across various institutions. This instrument is used by adult services but is not validated for use in pediatrics [35].

Differential diagnosis

A detailed history and a careful physical examination can aid differentiation from other diseases which present with recurrent nausea, vomiting, abdominal pain, early satiety and postprandial fullness. Patients with gastroparesis may complain of nonspecific abdominal pain and on examination they could have epigastric or diffuse abdominal pain but often physical examination is unremarkable. Conditions that should be distinguished from gastroparesis include firstly esophagitis and peptic ulcer disease, which can be easily diagnosed endoscopically [36]. In cyclical vomiting syndrome GE time is normal in the free of symptoms periods [37]. Rumination syndrome shares common symptoms with gastroparesis but

is characterized by effortless regurgitation immediately or a short period (e.g. 30 min) after meal consumption [38,39]. Intestinal obstruction (e.g. pyloric stenosis, malrotation with volvulus, intestinal atresia or stenosis) are usually diagnosed with upper gastrointestinal contrast series or with transabdominal ultrasonography [40-42].

Interestingly, there is significant overlap between true gastroparesis, FD - as it is defined by the Rome III criteria - and the recently described gastroparesis-like syndrome [43,44]. Delayed GE is present in a subset of pediatric patients with FD [45] and as a result the differential diagnosis in this case can be challenging. Table 1 depicts the data from pediatric studies [10,46,47] regarding the prevalence of common symptoms in children with FD and gastroparesis. Abdominal pain and nausea are the predominant symptoms in FD, while vomiting is the cardinal symptom of gastroparesis. The differentiation between gastroparesis and FD with delayed GE can be difficult and the classification of these disorders as completely different clinical entities still remains controversial [48,49].

Medications that cause nausea and vomiting as side effects also need to be excluded (e.g. anti-neoplastic drugs) [50]. Other diseases that could potentially mimic gastroparesis include conditions affecting the gastrointestinal tract (pancreatobiliary disorders, celiac artery compression syndrome) [51,52], endocrine system (hyperaldosteronism), central nervous system (tumors) and the genitourinary tract (pregnancy, chronic pyelonephritis, uremia) [33].

Table 1 Occurrence of common symptoms in children with functional dyspepsia and gastroparesis

Symptoms	Functional dyspepsia (% of children)	Gastroparesis (% of children)
Nausea	70	28
Abdominal pain	70	5
Bloating	30	7
Vomiting	55	68
Early satiety	10	25

Table 2 The most common causes of gastroparesis in children

Etiological factors	Percent (%) *
Idiopathic	70
Drug-induced	18
Postsurgical	12.5
Postviral	5
Diabetic	4

(Adapted from: Waseem S, Islam S, Kahn G, Moshiree B, Talley NJ. Spectrum of gastroparesis in children. *J Pediatr Gastroenterol Nutr* 2012;55:166-172)

*The numbers need to be interpreted by taking into account that there is overlap between the various categories of gastroparesis

Diagnostic investigations

When gastroparesis is considered as a potential diagnosis an upper gastrointestinal contrast study or esophagogastroduodenoscopy are initially required in order to rule out mechanical obstruction. Subsequently a GE scintigraphy of a radiolabeled solid meal is performed as it remains the gold standard for the diagnosis of gastroparesis [1].

GE scintigraphy

During this test a radiolabeled meal is ingested and the percentage of the radioactivity, which correlates with the amount of the meal retained in the stomach, is calculated at various times. Scintigraphy is a physiological, cost-effective, non-invasive and quantitative method of evaluating GE time [53]. A consensus regarding the methodology of this test has been established for adults by the American Neurogastroenterology and Motility Society and the Society of Nuclear Medicine but not for the pediatric population. According to this protocol the patient ingests a technetium-99m sulphur colloid radiolabeled meal consisting of two large eggs, two slices of bread, jam and water. GE time is considered delayed if there is retention >90% at 1 h after meal ingestion, >60% at 2 h, and >10% at 4 h [2,3,54]. Of note, despite the fact that nuclear scintigraphy with solids is the standard criterion of determining GE time a study has been published indicating that GE of liquids can be abnormal in patients with normal GE of solids, suggesting therefore to perform the study for both the liquid and solid phase [55].

In children, the investigation is performed in accordance to various institution protocols. This limits the clinical utility of the test especially in terms of interpreting results from laboratories which follow a different methodology [56-59]. Apparently when the protocols are not the same between institutions or differ from published data then each laboratory needs to determine their own control values for their methodology.

Breath test

This is also a non-invasive method that indirectly measures GE time. The results from breath testing are similar to the ones measured by the GE scintigraphy [60,61]. The test is performed with a stable nonradioactive ^{13}C -isotope which is bound to a digestible substance and then mixed into a solid or liquid meal. The meal is ingested and then the isotope is absorbed by the small intestine and subsequently metabolized into ^{13}C - CO_2 which is exhaled and collected. The ratio $^{13}\text{CO}_2/^{12}\text{CO}_2$ in exhalation is used to evaluate the GE time [62,63]. This test has the advantage of not exposing the patient to radiation but it can be inaccurate in patients with specific conditions such as celiac disease and liver cirrhosis (impaired metabolism of the isotope to CO_2) [64].

Other methods

Other methods that assess the gastric motor activity and measure GE time include transabdominal ultrasonography, Magnetic Resonance Imaging (MRI) and antroduodenal manometry.

Both ultrasound and MRI are non-invasive techniques that measure not only GE time but also other parameters which affect the latter such as accommodation, antral contractility, and distribution of the meal. Few data are available and further validation of both techniques is required [65,66].

Antroduodenal manometry is an invasive technique that uses a water-perfused or solid-state catheter (placed intranasally or via a gastrostomy site) to measure intraluminal pressures in the stomach and small intestine. In gastroparetic children there is a disruption of the normal relationship between antral, pyloric and duodenal waves [67,68]. Antroduodenal manometry is particularly useful in differentiating between gastroparesis due to myopathy (presence of coordinated low amplitude contractions) or neuropathy (uncoordinated contractions with normal amplitude) [69,70].

Management

General approach

The pillars of treatment in gastroparesis include the diagnosis and management of an underlying disease, correction of fluid and electrolyte imbalances, alleviation of symptoms, and maintenance of optimal nutritional status. Patients with mild disease can be managed as outpatients whereas those with severe and life threatening manifestations (e.g. pronounced dehydration, electrolyte imbalances, intractable vomiting) need hospitalization and close monitoring.

Dietary and lifestyle modifications

Management of gastroparesis includes dietary and lifestyle recommendations such as small-volume and frequent meals with low content in fat and non-digestible fibers. Patients are advised to avoid carbonated beverages and lying down for 1 to 2 h following meals. A thorough dietary history must be obtained in order to enlighten the clinician about the caloric intake of the patient and the tolerance of solids and liquids. Referral to a dietician is always warranted.

In cases of severe and persistent symptoms the majority of calories are provided in a liquid form given that liquid emptying is often preserved. Enteral nutrition via nasojejun tube or jejunostomy may be required for patients with severely impaired nutritional status. Total parenteral nutrition is reserved for the most complex patient who fails enteral feeds [71-73].

Pharmacologic treatment

There are many agents available for the management of gastroparesis.

Prokinetics

This category includes drugs such as metoclopramide, domperidone, and erythromycin. They promote GE by stimulating antral motility, correcting gastric dysrhythmias and enhancing antroduodenal coordination [74]. In one large pediatric cohort, promotility drugs were found to be effective in 55% of patients. A tendency towards a positive response to prokinetic drugs was also demonstrated in children in comparison to adolescents and infants and in patients with postviral gastroparesis. In the same study 26% of patients responded to metoclopramide with 24% reporting adverse effects (AEs), 74% responded to domperidone with 6% AEs and 51% responded to erythromycin with 10% AEs [5].

Metoclopramide and domperidone are dopamine antagonists. Metoclopramide has a central antiemetic and a peripheral prokinetic effect. Domperidone acts only as a peripheral dopamine antagonist because it does not cross the brain-blood barrier [75]. Although they are considered safe and effective drugs in the treatment of gastroparesis there are reports about potential side-effects such as galactorrhea for both drugs due to hyperprolactinemia, extrapyramidal dyskinetic reactions for metoclopramide, and cardiac arrhythmias or even sudden death for domperidone [74,76].

Erythromycin when administered in subtherapeutic doses (3-5 mg/kg/dose every 6 h) acts as a motilin agonist and has a significant prokinetic effect. Its safety and efficacy in improving feeding intolerance have been demonstrated in multiple studies with premature infants and children [30]. However, there are reports showing that early exposure to erythromycin in the neonatal period significantly increases the risk of pyloric stenosis in infants [10,77]. Interestingly prolongation of QT, a well-known side effect of erythromycin [78], was not reported as an AE in a recent large pediatric retrospective study on gastroparesis [5].

Cisapride and tegaserode both 5-HT₄ receptor agonists have been licensed in the past but then withdrawn from the market because of risk of arrhythmia-associated death [79] and cardiovascular ischemic events [80] respectively.

Antiemetics

This group includes phenothiazines (e.g. prochlorperazine), 5-HT₃ antagonists (e.g. ondasetron), dopamine antagonists (e.g. metoclopramide), histamine H₁ antagonists (e.g. diphenhydramine), and benzodiazepines (e.g. lorazepam). They are prescribed in conjunction with prokinetic drugs in order to symptomatically alleviate nausea [81].

Proton pump inhibitors (PPIs)

Lansoprazole, omeprazole, esomeprazole and pantoprazole

are frequently used to address gastroesophageal reflux which is a common complication of gastroparesis in children [5].

Botulinum toxin

Botulinum toxin type A is endoscopically injected into the pylorus [82]. It blocks the release of acetylcholine from cholinergic nerve endings and as a result alleviates symptoms by promoting GE [83]. In pediatrics although botulinum toxin is occasionally used in children with refractory gastroparesis, sufficient data to definitively evaluate its use for this purpose are not yet available [84].

Gastric stimulation

This intervention is based on the laparoscopic implantation of two electrodes - connected to a pacemaker - into the seromuscular layer of the stomach. Two studies in children with gastroparesis demonstrated that gastric stimulation alleviated their symptoms and improved quality of life [85,86]. Despite the promising results the long-term efficacy and safety of this modality need to be established.

Surgical interventions

These include gastrostomy tube insertion, which may be required in order to facilitate gastric ventilation and symptomatic relief, and the placement of a jejunostomy tube. These therapeutic options are reserved for refractory cases that fail medical treatment [5,10,87]. Other sophisticated surgical techniques have also been proposed for complicated cases of gastroparesis [88]. Studies in both children and adults show favorable outcomes in terms of promotion of nutritional status, relief of symptoms and reduction of hospitalization frequency [5,89].

Alternative medical therapies

Apart from the therapeutic modalities that have been previously described, non-conventional medical treatments are also used to alleviate symptoms in patients with gastroparesis and FD [1]. Such interventions include the use of nutraceuticals (ginger, iberogast, rikkunshito), hypnosis and biofeedback as well as acupuncture [90-93]. The majority of published studies were conducted in adult populations and as a result their applicability in pediatrics needs to be further explored.

Figure 1 presents a summarized stepwise approach in the diagnosis and treatment of gastroparesis as proposed by the American Gastroenterological Association, based on the expertise of physicians who specialize in this field [1].

Outcome

Two retrospective studies in large pediatric cohorts

provide useful data on the outcome of gastroparesis in children. The first study demonstrated resolution of symptoms in 52% of the patients after a median follow-up period of 18 months [5] and found that factors such as younger age, postviral etiology, shorter duration of symptoms, response to prokinetics and presence of nausea correlated with a favorable outcome. The second study revealed significant symptom improvement in 60% of the patients after a mean follow-up period of 24 months [10], and showed that favorable outcome was not related to gender, age, or degree of GE delay [10]. These data, although conflicting, further enrich our understanding of gastroparesis in children. Additionally, these studies differ from those performed in adults which show a high morbidity and mortality for this disease.

Future prospects

During the past few years our understanding of the etiology, pathophysiology, and management of gastroparesis has significantly improved. Current research on novel therapeutic agents: hemin [94], ghrelin agonist TZP-101 [95], muscarinic receptor antagonist acotiamide (Z-338) [96] and the motilin receptor agonist mitemincal [97] just to name a few, along with recent advances in reprogramming of somatic cells and stem cell transplantation [98,99], create a whole new era of future treatment possibilities for gastroparesis.

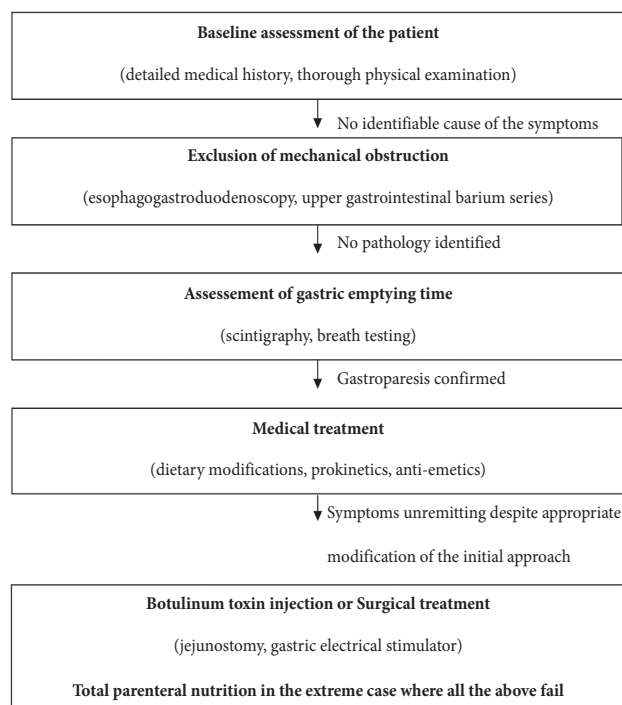


Figure 1 Stepwise approach in the diagnosis and treatment of gastroparesis

References

- Parkman HP, Hasler WL, Fisher RS. American Gastroenterological Association technical review on the diagnosis and treatment of gastroparesis. *Gastroenterology* 2004;**127**:1592-1622.
- Abell TL, Camilleri M, Donohoe K, et al. Consensus recommendations for gastric emptying scintigraphy: a joint report of the American Neurogastroenterology and Motility Society and the Society of Nuclear Medicine. *Am J Gastroenterol* 2008;**103**:753-763.
- Tougas G, Eaker EY, Abell TL, et al. Assessment of gastric emptying using a low fat meal: establishment of international control values. *Am J Gastroenterol* 2000;**95**:1456-1462.
- Parkman HP, Hasler WL, Fisher RS. American Gastroenterological Association medical position statement: diagnosis and treatment of gastroparesis. *Gastroenterology* 2004;**127**:1589-1591.
- Rodriguez L, Irani K, Jiang H, Goldstein AM. Clinical presentation, response to therapy, and outcome of gastroparesis in children. *J Pediatr Gastroenterol Nutr* 2012;**55**:185-190.
- Franzese A, Borrelli O, Corrado G, et al. Domperidone is more effective than cisapride in children with diabetic gastroparesis. *Aliment Pharmacol Ther* 2002;**16**:951-957.
- Pande H, Lacy BE, Crowell MD. Inflammatory causes of gastroparesis: report of five cases. *Dig Dis Sci* 2002;**47**:2664-2668.
- Frank L, Kleinman L, Ganoczy D, et al. Upper gastrointestinal symptoms in North America: prevalence and relationship to healthcare utilization and quality of life. *Dig Dis Sci* 2000;**45**:809-818.
- Jung HK, Choung RS, Locke GR, 3rd, et al. The incidence, prevalence, and outcomes of patients with gastroparesis in Olmsted County, Minnesota, from 1996 to 2006. *Gastroenterology* 2009;**136**:1225-1233.
- Waseem S, Islam S, Kahn G, Moshiree B, Talley NJ. Spectrum of gastroparesis in children. *J Pediatr Gastroenterol Nutr* 2012;**55**:166-172.
- Vittal H, Farrugia G, Gomez G, Pasricha PJ. Mechanisms of disease: the pathological basis of gastroparesis--a review of experimental and clinical studies. *Nat Clin Pract Gastroenterol Hepatol* 2007;**4**:336-346.
- Migdalis L, Thomaidis T, Chairopoulos C, Kalogeropoulos C, Charalabides J, Mantzara F. Changes of gastric emptying rate and gastrin levels are early indicators of autonomic neuropathy in type II diabetic patients. *Clin Auton Res* 2001;**11**:259-263.
- Thomaidis T, Karapanayiotides T, Zoukos Y, et al. Gastric emptying after semi-solid food in multiple system atrophy and Parkinson disease. *J Neurol* 2005;**252**:1055-1059.
- Parkman HP, Camilleri M, Farrugia G, et al. Gastroparesis and functional dyspepsia: excerpts from the AGA/ANMS meeting. *Neurogastroenterol Motil* 2009;**22**:113-133.
- Sigurdsson L, Flores A, Putnam PE, Hyman PE, Di Lorenzo C. Postviral gastroparesis: presentation, treatment, and outcome. *J Pediatr* 1997;**131**:751-754.
- Tougas G, Earnest DL, Chen Y, Vanderkoy C, Rojavin M. Omeprazole delays gastric emptying in healthy volunteers: an effect prevented by tegaserod. *Aliment Pharmacol Ther* 2005;**22**:59-65.
- Sodhi SS, Guo JP, Maurer AH, O'Brien G, Srinivasan R, Parkman HP. Gastroparesis after combined heart and lung transplantation. *J Clin Gastroenterol* 2002;**34**:34-39.
- Marano AR, Caride VJ, Prokop EK, Troncale FJ, McCallum RW. Effect of sucralfate and an aluminum hydroxide gel on gastric emptying of solids and liquids. *Clin Pharmacol Ther* 1985;**37**:629-632.
- Maes BD, Ghooys YE, Geypens BJ, Hiele MI, Rutgeerts PJ. Influence of octreotide on the gastric emptying of solids and liquids in normal healthy subjects. *Aliment Pharmacol Ther* 1995;**9**:11-18.
- Parkman HP, Harris AD, Krevsky B, Urbain JL, Maurer AH, Fisher RS. Gastrointestinal motility and dysmotility: an update on techniques available for evaluation. *Am J Gastroenterol* 1995;**90**:869-892.
- Naftali T, Yishai R, Zangen T, Levine A. Post-infectious gastroparesis: clinical and electrogastrographic aspects. *J Gastroenterol Hepatol* 2007;**22**:1423-1428.
- Bitvutskiy LP, Soykan I, McCallum RW. Viral gastroparesis: a subgroup of idiopathic gastroparesis--clinical characteristics and long-term outcomes. *Am J Gastroenterol* 1997;**92**:1501-1504.
- Vassallo M, Camilleri M, Caron BL, Low PA. Gastrointestinal motor dysfunction in acquired selective cholinergic dysautonomia associated with infectious mononucleosis. *Gastroenterology* 1991;**100**:252-258.
- Oh JJ, Kim CH. Gastroparesis after a presumed viral illness: clinical and laboratory features and natural history. *Mayo Clin Proc* 1990;**65**:636-642.
- Shafi MA, Pasricha PJ. Post-surgical and obstructive gastroparesis. *Curr Gastroenterol Rep* 2007;**9**:280-285.
- Ravelli AM. Diagnostic and therapeutic approach to vomiting and gastroparesis in children with neurological and neuromuscular handicap. *J Pediatr Gastroenterol Nutr* 1997;**25**(Suppl 1):S34-S36.
- Werlin SL. Antroduodenal motility in neurologically handicapped children with feeding intolerance. *BMC Gastroenterol* 2004;**4**:19.
- Miele E, Tozzi A, Staiano A, Toraldo C, Esposito C, Clouse RE. Persistence of abnormal gastrointestinal motility after operation for Hirschsprung's disease. *Am J Gastroenterol* 2000;**95**:1226-1230.
- Gatopoulou A, Papanas N, Maltezos E. Diabetic gastrointestinal autonomic neuropathy: current status and new achievements for everyday clinical practice. *Eur J Intern Med* 2012;**23**:499-505.
- Costalos C, Gounaris A, Varhalama E, Kokori F, Alexiou N, Kolovou E. Erythromycin as a prokinetic agent in preterm infants. *J Pediatr Gastroenterol Nutr* 2002;**34**:23-25.
- Laskin BL, Choyke P, Keenan GF, Miller FW, Rider LG. Novel gastrointestinal tract manifestations in juvenile dermatomyositis. *J Pediatr* 1999;**135**:371-374.
- Grill BB, Lange R, Markowitz R, Hillemeier AC, McCallum RW, Gryboski JD. Delayed gastric emptying in children with Crohn's disease. *J Clin Gastroenterol* 1985;**7**:216-226.
- Ravelli AM. Gastrointestinal function in chronic renal failure. *Pediatr Nephrol* 1995;**9**:756-762.
- Yamataka A, Pringle KC, Wyeth J. A case of zinc chloride ingestion. *J Pediatr Surg* 1998;**33**:660-662.
- Revicki DA, Rentz AM, Dubois D, et al. Gastroparesis Cardinal Symptom Index (GCSI): development and validation of a patient reported assessment of severity of gastroparesis symptoms. *Qual Life Res* 2004;**13**:833-844.
- Parkman HP, Schwartz SS. Esophagitis and gastroduodenal disorders associated with diabetic gastroparesis. *Arch Intern Med* 1987;**147**:1477-1480.
- Turchetti A, Guglielmi S, Fossati C, Matrunola M, Corrado G. Gastric emptying time in cyclic vomiting syndrome in children. *Eur Rev Med Pharmacol Sci* 2004;**8**:295-298.
- Chial HJ, Camilleri M, Williams DE, Litzinger K, Perrault J. Rumination syndrome in children and adolescents: diagnosis, treatment, and prognosis. *Pediatrics* 2003;**111**:158-162.
- Hussain SZ, Di Lorenzo C. Motility disorders. Diagnosis and treatment for the pediatric patient. *Pediatr Clin North Am* 2002;**49**:27-51.
- Hryhorczuk AL, Lee EY. Imaging evaluation of bowel obstruction in children: updates in imaging techniques and review of imaging findings. *Semin Roentgenol* 2012;**47**:159-170.
- Costa Dias S, Swinson S, Torrao H, et al. Hypertrophic pyloric stenosis: tips and tricks for ultrasound diagnosis. *Insights Imaging* 2012;**3**:247-250.
- Lamp B, Levin TL, Berdon WE, Cowles RA. Malrotation and midgut volvulus: a historical review and current controversies

- in diagnosis and management. *Pediatr Radiol* 2009;**39**:359-366.
43. Rasquin A, Di Lorenzo C, Forbes D, et al. Childhood functional gastrointestinal disorders: child/adolescent. *Gastroenterology* 2006;**130**:1527-1537.
 44. Anaparthi R, Pehlivanov N, Grady J, Yimei H, Pasricha PJ. Gastroparesis and gastroparesis-like syndrome: response to therapy and its predictors. *Dig Dis Sci* 2009;**54**:1003-1010.
 45. Friesen CA, Lin Z, Hyman PE, et al. Electrogastrography in pediatric functional dyspepsia: relationship to gastric emptying and symptom severity. *J Pediatr Gastroenterol Nutr* 2006;**42**:265-269.
 46. Hoffman I, Vos R, Tack J. Assessment of gastric sensorimotor function in paediatric patients with unexplained dyspeptic symptoms and poor weight gain. *Neurogastroenterol Motil* 2007;**19**:173-179.
 47. Chitkara DK, Delgado-Aros S, Bredenoord AJ, et al. Functional dyspepsia, upper gastrointestinal symptoms, and transit in children. *J Pediatr* 2003;**143**:609-613.
 48. Lacy BE. Functional dyspepsia and gastroparesis: one disease or two? *Am J Gastroenterol* 2012;**107**:1615-1620.
 49. Janssen P, van Oudenhove L, Bisschops R, Tack J. Idiopathic gastroparesis or functional dyspepsia with delayed gastric emptying: where is the difference? *Gastroenterology* 2011;**140**:2145-2146; author reply 2146-2148.
 50. Clinton F, Dowling M, Capra M. An audit of chemotherapy-induced nausea and vomiting in children. *Nurs Child Young People* 2012;**24**:18-23.
 51. Schweizer P, Berger S, Schweizer M, Schaefer J, Beck O. Arcuate ligament vascular compression syndrome in infants and children. *J Pediatr Surg* 2005;**40**:1616-1622.
 52. Chowdhury RS, Forsmark CE, Davis RH, Toskes PP, Verne GN. Prevalence of gastroparesis in patients with small duct chronic pancreatitis. *Pancreas* 2003;**26**:235-238.
 53. Donohoe KJ, Maurer AH, Ziessman HA, Urbain JL, Royal HD, Martin-Comin J. Procedure guideline for adult solid-meal gastric-emptying study 3.0. *J Nucl Med Technol* 2009;**37**:196-200.
 54. Chogle A, Saps M. Gastroparesis in Children. The Benefit of Conducting 4 Hours Scintigraphic Gastric Emptying Studies. *J Pediatr Gastroenterol Nutr*. DOI: 10.1097/MPG.0b013e31827a789c
 55. Ziessman HA, Okolo PI, Mullin GE, Chander A. Liquid gastric emptying is often abnormal when solid emptying is normal. *J Clin Gastroenterol* 2009;**43**:639-643.
 56. Maes BD, Ghoos YF, Geypens BJ, Hiele MI, Rutgeerts PJ. Relation between gastric emptying rate and energy intake in children compared with adults. *Gut* 1995;**36**:183-188.
 57. Montgomery M, Escobar-Billing R, Hellstrom PM, Karlsson KA, Frenckner B. Impaired gastric emptying in children with repaired esophageal atresia: a controlled study. *J Pediatr Surg* 1998;**33**:476-480.
 58. Heyman S. Gastric Emptying in Children. *J Nucl Med* 1998;**39**:865-869.
 59. Singh SJ, Gibbons NJ, Blackshaw PE, Vincent M, Wakefield J, Perkins AC. Gastric emptying of solids in normal children--a preliminary report. *J Pediatr Surg* 2006;**41**:413-417.
 60. Bromer MQ, Kantor SB, Wagner DA, Knight LC, Maurer AH, Parkman HP. Simultaneous measurement of gastric emptying with a simple muffin meal using [¹³C]octanoate breath test and scintigraphy in normal subjects and patients with dyspeptic symptoms. *Dig Dis Sci* 2002;**47**:1657-1663.
 61. Delbende B, Perri F, Couturier O, et al. ¹³C-octanoic acid breath test for gastric emptying measurement. *Eur J Gastroenterol Hepatol* 2000;**12**:85-91.
 62. Maes BD, Ghoos YF, Rutgeerts PJ, Hiele MI, Geypens B, Vantrappen G. [¹³C]octanoic acid breath test to measure gastric emptying rate of solids. *Dig Dis Sci* 1994;**39**:104S-106S.
 63. Braden B, Adams S, Duan LP, et al. The [¹³C]acetate breath test accurately reflects gastric emptying of liquids in both liquid and semisolid test meals. *Gastroenterology* 1995;**108**:1048-1055.
 64. Perri F, Bellini M, Portincasa P, et al. (¹³C)-octanoic acid breath test (OBT) with a new test meal (EXPIROGer): Toward standardization for testing gastric emptying of solids. *Dig Liver Dis* 2010;**42**:549-553.
 65. Gilja OH, Hausken T, degaard S, Berstad A. Gastric emptying measured by ultrasonography. *World J Gastroenterol* 1999;**5**:93-94.
 66. Feinle C, Kunz P, Boesiger P, Fried M, Schwizer W. Scintigraphic validation of a magnetic resonance imaging method to study gastric emptying of a solid meal in humans. *Gut* 1999;**44**:106-111.
 67. Di Lorenzo C, Hillemeier C, Hyman P, et al. Manometry studies in children: minimum standards for procedures. *Neurogastroenterol Motil* 2002;**14**:411-420.
 68. Camilleri M, Bharucha AE, di Lorenzo C, et al. American Neurogastroenterology and Motility Society consensus statement on intraluminal measurement of gastrointestinal and colonic motility in clinical practice. *Neurogastroenterol Motil* 2008;**20**:1269-1282.
 69. Tomomasa T, DiLorenzo C, Morikawa A, Uc A, Hyman PE. Analysis of fasting antroduodenal manometry in children. *Dig Dis Sci* 1996;**41**:2195-2203.
 70. Cucchiara S, Borrelli O, Salvia G, et al. A normal gastrointestinal motility excludes chronic intestinal pseudoobstruction in children. *Dig Dis Sci* 2000;**45**:258-264.
 71. Abell TL, Malinowski S, Minocha A. Nutrition aspects of gastroparesis and therapies for drug-refractory patients. *Nutr Clin Pract* 2006;**21**:23-33.
 72. Karamanolis G, Tack J. Nutrition and motility disorders. *Best Pract Res Clin Gastroenterol* 2006;**20**:485-505.
 73. Parrish CR. Nutrition concerns for the patient with gastroparesis. *Curr Gastroenterol Rep* 2007;**9**:295-302.
 74. Patterson D, Abell T, Rothstein R, Koch K, Barnett J. A double-blind multicenter comparison of domperidone and metoclopramide in the treatment of diabetic patients with symptoms of gastroparesis. *Am J Gastroenterol* 1999;**94**:1230-1234.
 75. Ahmad N, Keith-Ferris J, Gooden E, Abell T. Making a case for domperidone in the treatment of gastrointestinal motility disorders. *Curr Opin Pharmacol* 2006;**6**:571-576.
 76. Dumitrascu DL, Weinbeck M. Domperidone versus metoclopramide in the treatment of diabetic gastroparesis. *Am J Gastroenterol* 2000;**95**:316-317.
 77. Cooper WO, Griffin MR, Arbogast P, Hickson GB, Gautam S, Ray WA. Very early exposure to erythromycin and infantile hypertrophic pyloric stenosis. *Arch Pediatr Adolesc Med* 2002;**156**:647-650.
 78. O'Donovan D, Feinle-Bisset C, Jones K, Horowitz M. Idiopathic and Diabetic Gastroparesis. *Curr Treat Options Gastroenterol* 2003;**6**:299-309.
 79. Hennessy S, Leonard CE, Newcomb C, Kimmel SE, Bilker WB. Cisapride and ventricular arrhythmia. *Br J Clin Pharmacol* 2008;**66**:375-385.
 80. Busti AJ, Murillo JR, Jr., Cryer B. Tegaserod-induced myocardial infarction: case report and hypothesis. *Pharmacotherapy* 2004;**24**:526-531.
 81. Quigley EM, Hasler WL, Parkman HP. AGA technical review on nausea and vomiting. *Gastroenterology* 2001;**120**:263-286.
 82. Ezzeddine D, Jit R, Katz N, Gopalswamy N, Bhutani MS. Pyloric injection of botulinum toxin for treatment of diabetic gastroparesis. *Gastrointest Endosc* 2002;**55**:920-923.
 83. Montecucco C, Molgo J. Botulinum neurotoxins: revival of an old killer. *Curr Opin Pharmacol* 2005;**5**:274-279.
 84. Rodriguez L, Rosen R, Manfredi M, Nurko S. Endoscopic intrapyloric injection of botulinum toxin A in the treatment of children with gastroparesis: a retrospective, open-label study.

- Gastrointest Endosc* 2012;**75**:302-309.
85. Islam S, Vick LR, Runnels MJ, Gosche JR, Abell T. Gastric electrical stimulation for children with intractable nausea and gastroparesis. *J Pediatr Surg* 2008;**43**:437-442.
 86. Teich S, Mousa HM, Punati J, Di Lorenzo C. Efficacy of permanent gastric electrical stimulation for the treatment of gastroparesis and functional dyspepsia in children and adolescents. *J Pediatr Surg* 2013;**48**:178-183.
 87. Michaud L, Guimber D, Carpentier B, et al. Gastrostomy as a decompression technique in children with chronic gastrointestinal obstruction. *J Pediatr Gastroenterol Nutr* 2001;**32**:82-85.
 88. Tatekawa Y, Komuro H. A technical surgery for refractory gastroparesis in a patient with a mitochondrial disorder. *Pediatr Surg Int* 2010;**26**:655-658.
 89. Zehetner J, Ravari F, Ayazi S, et al. Minimally invasive surgical approach for the treatment of gastroparesis. *Surg Endosc* 2013;**27**:61-66.
 90. Perez ME, Youssef NN. Dyspepsia in childhood and adolescence: insights and treatment considerations. *Curr Gastroenterol Rep* 2007;**9**:447-455.
 91. Sun BM, Luo M, Wu SB, Chen XX, Wu MC. Acupuncture versus metoclopramide in treatment of postoperative gastroparesis syndrome in abdominal surgical patients: a randomized controlled trial. *Zhong Xi Yi Jie He Xue Bao* 2010;**8**:641-644.
 92. Kawahara H, Mitani Y, Nomura M, et al. Impact of rikkunshito, an herbal medicine, on delayed gastric emptying in profoundly handicapped patients. *Pediatr Surg Int* 2009;**25**:987-990.
 93. Chiarioni G, Vantini I, De Iorio F, Benini L. Prokinetic effect of gut-oriented hypnosis on gastric emptying. *Aliment Pharmacol Ther* 2006;**23**:1241-1249.
 94. A Pilot Study of Hemin Therapy for Gastroparesis (Diabetes Mellitus). <http://clinicaltrials.gov/ct2/show/NCT01206582>. Access Date: 16/12/2012
 95. Ejskjaer N, Vestergaard ET, Hellstrom PM, et al. Ghrelin receptor agonist (TZP-101) accelerates gastric emptying in adults with diabetes and symptomatic gastroparesis. *Aliment Pharmacol Ther* 2009;**29**:1179-1187.
 96. Kusunoki H, Haruma K, Manabe N, et al. Therapeutic efficacy of acotiamide in patients with functional dyspepsia based on enhanced postprandial gastric accommodation and emptying: randomized controlled study evaluation by real-time ultrasonography. *Neurogastroenterol Motil* 2012;**24**:540-545, e250-e251.
 97. Takanashi H, Cynshi O. Motilides: a long and winding road: lessons from mitemcinal (GM-611) on diabetic gastroparesis. *Regul Pept* 2009;**155**:18-23.
 98. Micci MA, Kahrig KM, Simmons RS, Sarna SK, Espejo-Navarro MR, Pasricha PJ. Neural stem cell transplantation in the stomach rescues gastric function in neuronal nitric oxide synthase-deficient mice. *Gastroenterology* 2005;**129**:1817-1824.
 99. Jaenisch R. Stem cells, pluripotency and nuclear reprogramming. *J Thromb Haemost* 2009;**7** (Suppl 1):21-23.