

Gastric outlet obstruction secondary to adult gastric antral web

Rachel M. Gomes^a, Jayesh Kudchadkar^a,
Harish Peshwe^b, Trupti Gundawar^c

NUSI Wockhardt Hospital, Goa, India

The gastric antral mucosal diaphragms also called gastric antral webs (GAW) are circumferential membranes of mucosa and submucosa with a central aperture that occur in the gastric antrum near the pyloric canal [1]. They form a rare cause of gastric outlet obstruction (GOO) in adults [2,3].

A 45-year-old well-nourished male presented with postprandial epigastric pain, bloating, fullness and belching since childhood. He had borborygmi and crampy pain postprandially for several hours after which fullness and pain was relieved. He reported intermittent exacerbations with repeated vomiting containing undigested food taken several days before with recent increase in frequency of episodes. He had undergone an endoscopy a year back reporting a prepyloric ulcer with pyloric stenosis and was treated conservatively with not much improvement.

An endoscopy revealed GOO with a very small opening of the pylorus, not negotiable with the scope (Fig. 1). A contrast-enhanced computed tomography demonstrated normal but overdistended stomach, showing abrupt cutoff just proximal to pylorus, with normal caliber pylorus and duodenum without any lesion or thickening but showed some contrast indicating incomplete obstruction (Fig. 2). A diagnosis of pyloric obstruction secondary to healed prepyloric ulcer was made. At laparotomy there was no scarring of antrum, pylorus or duodenum. On pyloroduodenotomy the obstruction was found to be because of a GAW immediately juxtapyloric in position. After dividing the web, a pyloroplasty was completed. Post surgery patient's symptoms resolved with normal imaging.

The etiology of GAWs is agreed to be congenital in infants and children whereas in adults, whether it is congenital or acquired is controversial [4]. Approximately one fourth of all reported cases is associated with either gastric or duodenal ulcer disease, possibly caused by scarring of linear circumferential prepyloric and pyloric ulcers [4,5].

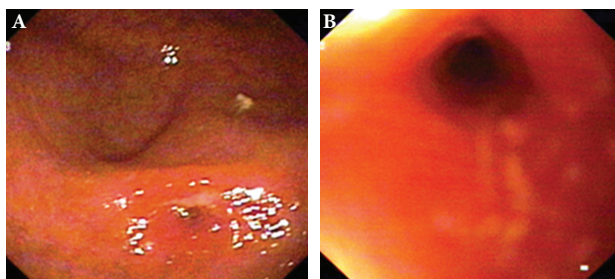


Figure 1 (A,B) Endoscopic gastroduodenoscopy showing gastric outlet obstruction with a very small opening in the antrum with scope not negotiable across (pinpoint pseudopylorus appearance)

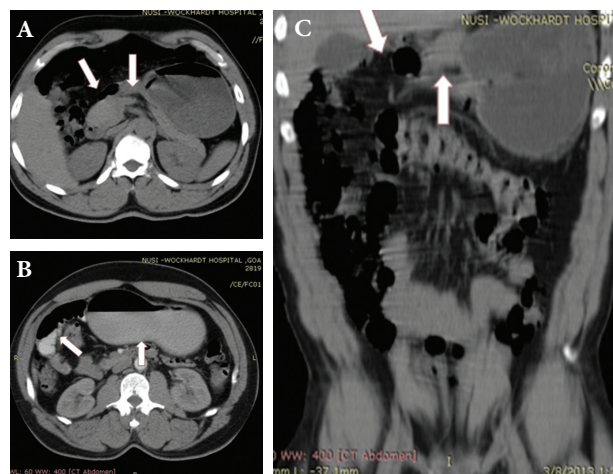


Figure 2 (A,B,C) Horizontal and coronal sections of computed tomography scan showing normal but overdistended stomach with retained contrast with abrupt cutoff just proximal to pylorus. Pylorus and duodenum are of normal calibre without any lesion or thickening (arrows image A and C) with some contrast emptying into the duodenum indicating partial obstruction (arrows image B)

Infants and children present with persistent postprandial non bile-stained vomiting and failure to thrive or malnutrition [3]. Adults present with postprandial fullness, bloating, epigastric pain, eructation of foul gas, symptomatically relieved by vomiting. Late presentations in adults are possibly due to progressive narrowing of aperture following marginal ulcerations and decreased motility with time or sudden obstruction secondary to poorly masticated food or mucosal edema of gastritis [6].

A classic feature on barium is a double-bulb appearance: normal duodenal bulb with a proximal antral chamber between the web and the pylorus [6]. However, if the antral chamber is small with close proximity of the web to the pylorus, as in our case, this sign may not be demonstrated. Whenever the stomach is normal but with gastric retention with an abrupt cutoff, and the pylorus and duodenal cap are normal, a GAW should be considered. EGD usually shows a large mucosal fold with a variable aperture or a pinpoint pseudopylorus as in our case causing diagnostic confusion [5,7].

If GAW aperture is more than one centimeter and the patient is asymptomatic, only dietary modifications are advised [4-6]. In symptomatic patients or in smaller aperture, either surgical or endoscopic intervention is needed. Surgical options are incision of the web with or without pyloroplasty [5-7]. Endoscopic options are resection with a snare, papilotomy, or Nd:YAG laser [7].

References

1. Clements JL, Jinkins JR, Tomes WE, et al. Antral mucosal diaphragms in adults. *Am J Roentgenol* 1979;133:1105-1111.
2. Pederson WC, Sirinek KR, Schwesinger WH, Levine BA. Gastric outlet obstruction secondary to antral mucosal diaphragm. *Dig*

Dis Sci 1984;**29**:86-90.

3. Nissan A, Seror D, Udassin R. Gastric outlet obstruction caused by prepyloric mucosal diaphragm mimicking duodenal ulcer: a case report. *Acta Paediatr* 1997;**86**:116-118.
4. Huggins MJ, Friedman AC, Lichtenstein JE, and Bova JG. Adult acquired antral web. *Dig Dis Sci* 1982;**27**:80-83.
5. Gul W, Abbass K, Markert RJ, Barde CJ. Gastric antral web in a 103-year-old patient. *Case Rep Gastrointest Med* 2011;**2011**:957060.
6. Ghahremani GG. Nonobstructive mucosal diaphragms or rings of the gastric antrum in adults. *Am J Roentgenol* 1974;**121**:236-247.
7. Maldonado ME, Mamel JJ, Johnson MC. Resolution of symptomatic GERD and delayed gastric emptying after endoscopic ablation of antral diaphragm (web). *Gastrointest Endosc* 1998;**48**:428-429.

Departments of ^aSurgical Gastroenterology (Rachel M. Gomes, Jayesh Kudchadkar), ^bMedical Gastroenterology (Harish Peshwe), ^cRadiology (Trupti Gundawar), NUSI Wockhardt Hospital, Goa, India

Conflict of interest: None

Correspondence to: Dr. Rachel M. Gomes, NUSI Wockhardt Hospital, Panzorconni, Cuncolim, Salcette, Goa, India 403 703, Tel.: +0832 6684000, e-mail: dr.gomes@rediffmail.com

Received 5 April 2013; accepted 16 April 2013

Two overlapping uncovered metallic stents for duodenal obstruction due to primary lymphoma

Mohammed Amine Benatta^a, Ariane Desjeux^b, Jean-Charles Grimaud^b

Military University Hospital, Oran, Algeria; Hopital Nord Marseille France

Primary non-Hodgkin's lymphoma (NHL) of the duodenum is an uncommon primary tumor of the gastrointestinal tract which accounts for less than 12% of all NHL [1,2]. Obstruction is a preterminal event. A decision-analytic model comparing open gastrojejunostomy, laparoscopic gastrojejunostomy, and endoscopic stenting for malignant gastroduodenal obstruction showed that self-expandable metal stent (SEMS) placement was the most cost-effective strategy and was associated with the lowest rate of complications and the highest success rate over a 1-month period [3]. This is a rare case of primary duodenal lymphoma with a poor response to chemotherapy, inoperable given the poor nutritional status and treated with SEMSs. A 24-year-old man was referred to our hospital with abdominal pain and upper obstruction signs, consisting of nausea, vomiting, dysphagia and progressive weight loss. Physical examination showed tenderness in the epigastrium without peripheral lymphadenopathy, hepatosplenomegaly, or intra-abdominal mass. Laboratory tests were normal. Upper gastrointestinal endoscopy demonstrated an ulcerated polypoid lesion with a near-complete duodenal obstruction. Histopathology of the lesion was compatible with large B-cell lymphomas and immunohistochemical

study was positive for CD20. Abdominal CT scans showed a circumferential thickening of the duodenal wall and revealed several lymph nodes. Chest CT scans showed no evidence of lymph node enlargement in the mediastinum. Bone marrow laboratory showed no tumor infiltration. Our patient received several cycles of systemic Rituximab (Mabthera[®]), Cyclophosphamide, Doxorubicine, Vincristine, Prednisone. This treatment failed to ameliorate the obstructive symptoms with objective weight loss of 9 kg. Upper endoscopy showed a near-complete obstruction. To alleviate this obstruction surgical intervention was deemed necessary but impossible given the poor nutritional status of our patient. In conscious sedation under both fluoroscopic and endoscopic control, a 0.035-inch biliary guidewire was indwelled over the stenosis (Fig. 1A). Without balloon dilatation, due to the length and anatomy of the stricture, and to a tendency for the stent to move away from the stricture it was essential to insert two overlapping uncovered SEMSs through the scope, 22 mm in diameter and 60mm in length (WallFlex duodenal stent, Boston Scientific) in D2-D3 and D1-D2.

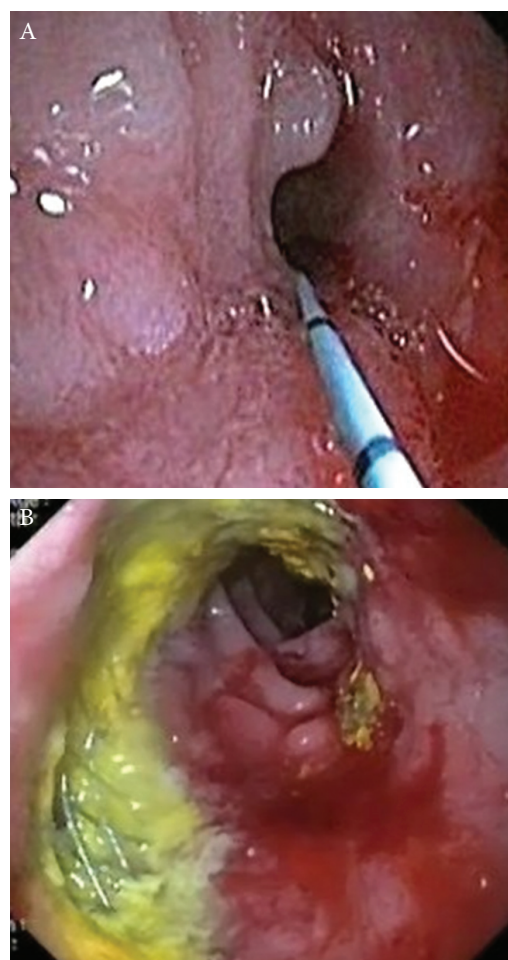


Figure 1 (A) A biliary guidewire indwelled over the duodenal stenosis. (B) Endoscopic control performed one year after placement of the stents

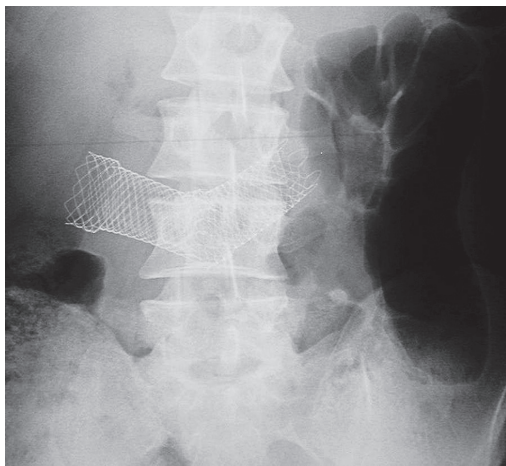


Figure 2 Abdominal X-ray showing the two overlapping self-expandable metal stents a few days after placement

No immediate complications were noted. The patient resumed oral intake immediately, received proton pump inhibitor treatment and was instructed to avoid leafy and uncooked vegetables. A few days after insertion the abdominal X-ray control showed the two overlapping SEMSs in place (Fig. 2).

After follow up of 36 months, no migration, re-obstruction, or occlusion was noted in our patient with two uncovered stents. Our patient was able to resume oral intake with objective weight gain of 10 kg. Endoscopic controls regularly performed showed the two SEMSs in place and functional (Fig. 1B).

Duodenal SEMSs are still underused in patients with malignant gastroduodenal obstruction. In our patient presenting a primary duodenal obstructing lymphoma, the SEMSs placement was effective in alleviating the intestinal obstruction. SEMSs should be recommended in treatment of malignant gastroduodenal obstruction especially in patients with poor performance status.

References

1. Tari A, Asaoku H, Kunihiro M, Tanaka S, Fujihara M, Yoshino T. Clinical features of gastrointestinal follicular lymphoma: comparison with nodal follicular lymphoma and gastrointestinal MALT lymphoma. *Digestion* 2011;**83**:191-197.
2. Muchmore JH, Haddad CG, Goldwag S. Primary non-Hodgkin's lymphoma of the duodenum. *Am Surg* 1994;**60**:924-928.
3. Siddiqui A, Spechler SJ, Huerta S. Surgical bypass versus endoscopic stenting for malignant gastroduodenal obstruction: a decision analysis. *Dig Dis Sci* 2007;**52**:276-281.

^aGastroenterology Department, Military University Hospital, Oran, Algeria (Amine Benatta); ^bGastroenterology Department, Hospital Nord Marseille France (Ariane Desjeux, Jean-Charles Grimaud)

Conflict of Interest: None

Correspondence to: Mohammed Amine Benatta, 156 Bakhti Noubra Oran, Algeria, e-mail: benattaamine@yahoo.fr

Received 17 April 2013; accepted 22 April 2013

Agitation as the only symptom of cerebral venous sinus thrombosis in a patient with Crohn's disease

Maria Kosmidou, Ioannis Vagias, Konstantinos H. Katsanos, Epameinondas V. Tsianos

University of Ioannina School of Medicine, Ioannina, Greece

Neurologic manifestations in inflammatory bowel disease (IBD) are not precisely estimated. Cerebral venous sinus thrombosis (CVT) is rare and only 1.6% of total CVTs are associated with IBD [1-5]. CVT occurs in only 1.3-6.4% of adults and 3.3% of children with IBD [2-5].

A 44-year-old female presented to the emergency department with fever of up to 38°C, abdominal pain and hemorrhagic diarrhea. Initially she was diagnosed as having ulcerative colitis, but 5 years ago the diagnosis was changed to Crohn's disease (CD) and was treated with adalimumab.

Physical, neurological and fundoscopic examinations were unremarkable apart from a temperature of 38°C. She had clotted external grade III hemorrhoids and perianal abscess.

Hematology examination revealed hematocrit of 27%, hemoglobin of 8.5 mg/dL and platelet count of 506,000 /mm³. Biochemical investigation was normal. The antithrombin level and the activities of the proteins C and S were normal. At that time the event was considered as a relapse of CD. The patient underwent surgical procedure for the abscess, and was treated with IV meropenem, and methylprednisolone. A prophylactic dose of enoxaparine was introduced.

On the 3rd day of hospitalization she became agitated, with anxiety attacks, ideas of impending doom, suspiciousness and insomnia. The symptoms were compatible with acute paranoid reaction or organic psychosyndrome. The brain MRI showed a subacute thrombus in the superior sagittal sinus. MR venography confirmed the absence of venous flow (Fig. 1).

The patient was treated with a therapeutic dose of enoxaparine for six months. Follow-up MR brain venography and neurological examination at three months after hospital discharge were normal.

There are limited reports in the literature concerning CVT associated with CD [3-5]. In our patient mainly the elevated platelets were indicative of increased activity of the coagulation system but she was receiving a prophylactic dose of enoxaparine. Mental disorders are a common side effect of corticosteroids [6]. These events were against the diagnosis of CVT.

Factors that promote thrombosis in IBD are: generalized inflammatory activity, intestinal loss of circulating anticoagu-

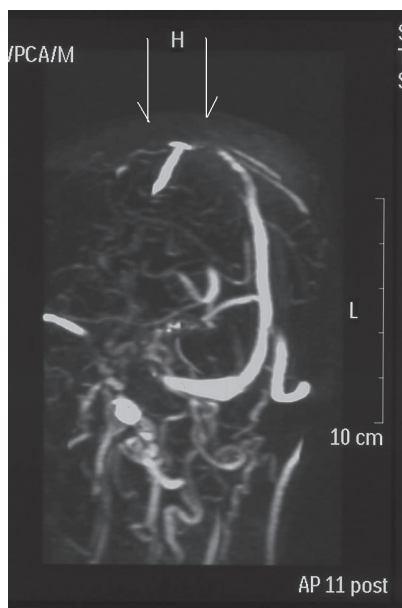

Figure 1 MR venography showing absence of flow on superior sagittal sinus

lants and transient abnormalities of the coagulation system during the active course of the disease such as: thrombocytosis, increased levels of factor V, VIII and fibrinogen and decreased antithrombin III and protein S [3-5]. High-dose corticosteroid treatment is associated with an increased risk of CVT [7]. Notably, there is one case reported with ulcerative colitis at anti-tumor necrosis factor (TNF) treatment which developed CVT [5]. Of all these mentioned factors our patient had thrombocytosis, she was receiving corticosteroids and anti-TNF.

The usual neurological symptom is persistent, global headache. The increased intracranial pressure results in vomiting and papilledema. The most common focal symptoms are: seizures, hemiplegia, tetraplegia, vision deficits, altered consciousness, aphasic disorders and confusion [2-5]. Rarely, CVT could present with psychiatric abnormalities if thalami or cortex are affected [2,3,5]. To our knowledge, pure psychiatric manifestations without a structural lesion have not been reported.

The current therapeutic approach recommends initial treatment with heparin which should be switched to oral anticoagulation for 3 to 6 months if a risk factor is not identified or is transient, otherwise treatment should be longer, even indefinitely [2-5,8].

References

1. Zois CD, Katsanos KH, Kosmidou M, Tsianos EV. Neurologic manifestations in inflammatory bowel diseases: current knowledge and novel insights. *J Crohns Colitis* 2010;4:115-124.
2. Einhaupl K, Stam J, Bousser MG, et al. EFNS guideline on the treatment of cerebral venous and sinus thrombosis in adult patients. *Eur J Neurol* 2010;17:1229-1235.
3. Katsanos AH, Katsanos KH, Kosmidou M, Giannopoulos S,

Kyritsis AP, Tsianos EV. Cerebral sinus venous thrombosis in inflammatory bowel diseases. *Q J Med* 2013;106:401-413.

4. Diakou M, Kostadima V, Giannopoulos S, Zikou AK, Argyropoulou MI, Kyritsis AP. Cerebral venous thrombosis in an adolescent with ulcerative colitis. *Brain Dev* 2011;33:49-51.
5. Cognat E, Crassard I, Denier C, Vahedi K, Bousser MG. Cerebral venous thrombosis in inflammatory bowel diseases: eight cases and literature review. *Int J Stroke* 2011;6:487-492.
6. Warrington TP, Bostwick JM. Psychiatric adverse effects of corticosteroids. *Mayo Clin Proc* 2006;81:1361-1367.
7. Stolz E, Klötzsch C, Schlachetzki F, Rahimi A. High-dose corticosteroid treatment is associated with an increased risk of developing cerebral venous thrombosis. *Eur Neurol* 2003;49:247-248.
8. Kosmidou M, Katsanos AH, Giannopoulos S. On the trail of cerebral sinus venous events in inflammatory bowel diseases. *J Neurosci Rural Pract* 2013;4:7-8.

1st Division of Internal Medicine & Hepato-Gastroenterology Unit, University of Ioannina School of Medicine, Ioannina, Greece

Conflict of Interest: None

Correspondence to: Maria Kosmidou, MD, PhD, 1st Division of Internal Medicine, University of Ioannina School of Medicine, 45110 Ioannina, Greece, Tel.-Fax: +30 26510 07500, e-mail: mkosmid@cc.uoi.gr

Received 29 April 2013; accepted 8 May 2013

Anorectal avulsion: report of a rare case of rectal injury

Rachel M. Gomes^a, Jayesh Kudchadkar^a, Edwin Araujo^b, Trupti Gundawar^c

NUSI Wockhardt Hospital, Goa, India

Blunt rectal injuries are very uncommon forming 4-11% of all rectal injuries and the rest are accounted for by penetrating rectal trauma [1]. Anorectal avulsion is a rare rectal injury [2].

A 30-year-old male admitted after a motorcycle accident with history of being partly runover by a vehicle over the right side of his pelvis with no history of impalement was found to have right superior and inferior pubic ramus and right T11 transverse process fractures with no chest, abdominal or bladder injuries. He had soft tissue injuries with a large hematoma over his right lateral thigh treated with aspirations. On resurvey in 72 h an inspection of his anus revealed patulous opening with bleeding and feculent material. Digital examination revealed complete avulsion of the anorectal complex from the anal opening at the skin lying above at a distance of around 12 cm with a large cavity below including both ischioanal fossae (Fig. 1A, 1B). The stump was also separated from the lower sacrum and coccyx (Fig. 1B, 2B). Both the levator ani were exposed but intact with the anorectum surrounded by the anal sphincter and puborectal muscle which appeared intact but with obvious loss of attachments and no tone (Fig. 2A, 2B). No direct suture was possible because of the retracted stump and infected cavity. A diverting sigmoid loop colostomy was

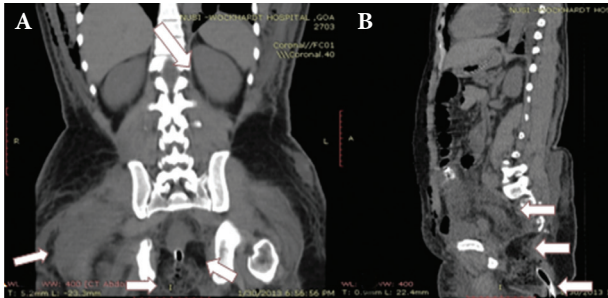


Figure 1 Plain CT scan abdomen (A) coronal section demonstrating intact levator ani, avulsed anorectal stump, ischioanal fossae with traumatic cavity (medial arrows) and abscess cavity right thigh (lateral arrow) (B) sagittal section demonstrating avulsed anorectal stump separated from lower sacrum and coccyx (top arrow) with cavity below (middle arrow) with tube exiting at skin level (lower arrow)

performed and the anorectal stump was intubated with distal loop washouts, debridements and dressing changes. Right thigh hematoma was infected after a few weeks and drained revealing communication with the perineal cavity through the posterior thigh compartment. Ischio-rectal and thigh wound healing by secondary intention was awaited. Patient was transferred after 4 weeks to another hospital because of financial constraints and lost to follow up. Digital exams still revealed patulous distal anorectal stump with no tone before transfer but no analysis with manometry was performed.

Anorectal avulsion is a rare case of rectal injury with only a few case reports available in the literature [2-4]. The mechanism of the injury is that crushing of the pelvis causes a reduction in its anteroposterior diameter and corresponding increase in its laterolateral diameter together with an abrupt increase in intraabdominal pressure [3]. The anus and sphincter lose their joining with the perineum because of divarication of the levator ani and are pulled upward and ventrally disrupting tissues in both ischioanal fossae [4] which can also affect muscles of the thigh as seen in our case. Treatment is not standardized. Direct repair is reported if detected early but is a major undertaking [3]. It is usually not possible due to

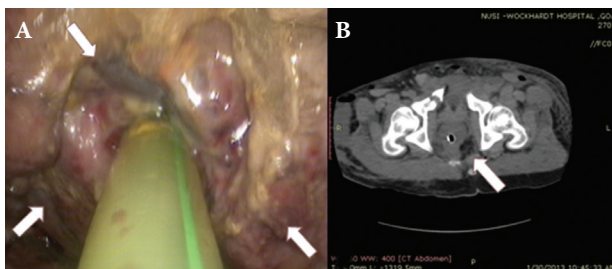


Figure 2 (A) Intracavity photograph of avulsed anorectal stump, part of skin avulsed seen attached to anal canal (top arrow), surrounded by the anal sphincter and puborectal muscle with exposed levator ani both sides (both lower arrows). (B) Corresponding plain CT scan abdomen horizontal section demonstrating avulsed anorectal stump separated from the sacrum

large loss of substance, high lying avulsed stump and high risk of infection. Healing is allowed by secondary intention and resulting gap can be covered with advancement flaps [4]. Long-term prognosis is good if the sphincter complex is intact around the anal canal after avulsion and though it remains displaced superiorly, anal canal length and resting pressure can be improved after pelvic floor rehabilitation and the diverting colostomy closed without significant complications [4].

References

1. Haas PA, Fox TA Jr. Civilian injuries of the rectum and anus. *Dis Colon Rectum* 1979;22:17-23.
2. Sharma D, Rahman H, Mandloi KC, Saxena A, Raina VK, Kapoor JP. Anorectal avulsion: an unusual rectal injury. *Dig Surg* 2000;17:193-194.
3. Terrosu G, Rossetto A, Kocjancic E, Rossitti P, Bresadola V. Anal avulsion caused by abdominal crush injury. *Tech Coloproctol* 2011;15:465-468.
4. Rispoli C, Andreuccetti J, Iannone L, et al. Anorectal avulsion: Management of a rare rectal trauma. *Int J Surg Case Rep* 2012;3:319-321.

Departments of ^aSurgical Gastroenterology (Rachel M. Gomes, Jayesh Kudchadkar), ^bOrthopaedics (Edwin Araujo); ^cRadiology (Trupti Gundawar), NUSI Wockhardt Hospital, Goa, India

Conflict of Interest: None

Correspondence to: Dr. Rachel M. Gomes, NUSI Wockhardt Hospital, Panzorconni, Cuncolim, Salcette, Goa, India 403703, Tel.: +832 668 4000, e-mail: dr.gomes@rediffmail.com

Received 2 March 2013; accepted 15 March 2013

A rare cause of biliary obstruction and pancreatitis

Yang Liu^a, Paul B. Lamb^b, Michael Piesman^b

Brooke Army Medical Center, San Antonio Uniformed Services Health Education Consortium (SAUSHEC), Ft. Sam Houston, Texas, USA

The prevalence of duodenal diverticula varies considerably in the literature, between 3-24% [1,2]. They are acquired extraluminal outpouchings of the mucosal wall through the muscularis propria and their incidence increases with age. While most duodenal diverticula do not cause major symptoms, they are increasingly recognized as causes of pancreaticobiliary disease. Food bezoar in a juxtapancreatic duodenal diverticulum (JPDD) causing pancreaticobiliary obstruction is rare, with the first of such case reported in 1977 [3]. We present a case of food bezoar in JPDD causing pancreatitis, severe pancreaticobiliary duct obstruction and dilation--mimicking as neoplasm-- that was successfully diagnosed and treated endoscopically.

A 60-year-old female presented with two months of right

upper quadrant abdominal (RUQ) pain radiating to the back with associated jaundice, nausea, vomiting, pruritus and clay colored stools. Physical exam was significant for jaundice, epigastric and RUQ tenderness without guarding. Vital signs were normal and afebrile. Laboratory testing revealed leukocyte count of 8,800 mm³, lipase of 1085 U/L, alanine aminotransferase 164 IU/L, total/direct bilirubin of 10.8/8.9 mg/dL and alkaline phosphatase of 523 IU/L. Abdominal ultrasound showed common bile duct (CBD) dilation to 17 mm and was without choledocholithiasis. CT of abdomen showed a 3.8 cm pancreatic head mass causing significant biliary ductal dilatation as well as pancreatic ductal dilatation (Fig. 1). Esophagogastroduodenoscopy (EGD) revealed large periampullary diverticula with impacted bezoar that was disimpacted with flushes and Roth Net (Fig. 2). Endoscopic ultrasound performed post disimpaction demonstrated aforementioned ductal dilatation on CT and diverticula, but without pancreatic head mass, choledocholithiasis, or pancreatic duct stones. The patient's symptoms and obstructive liver associated enzymes improved to normal levels over the next two months. Patient did not have recurrence of symptoms and laboratory findings also did not show evidence of hepatobiliary obstruction at one year follow up.

Diagnosis of JPDD can be suggested by upper gastrointestinal barium examinations visualized as collections of gas and barium in round or oval sack-like protrusions that usually arise from the medial aspect of the periampullary duodenum [4]. Direct visualization of the extraluminal outpouchings of the duodenum mucosal wall with EGD provides definitive diagnosis.

There is no consensus about the optimal treatment modality. Surgical procedures are available and are considered in diverticula with complications, but postoperative complications are not uncommon and carry a considerable mortality rate [5,6]. Complications of untreated duodenal diverticula, in addition to pancreatitis, biliary obstruction, cholangitis; can also include ulceration, hemorrhage, diverticulitis, and perforation with fistula and abscess formation [5]. Studies of endoscopic treatments of symptomatic duodenal diverticula are lacking. In our patient, the obstruction and symptoms were successfully relieved through endoscopic removal of the impacted material. There were no immediate complications

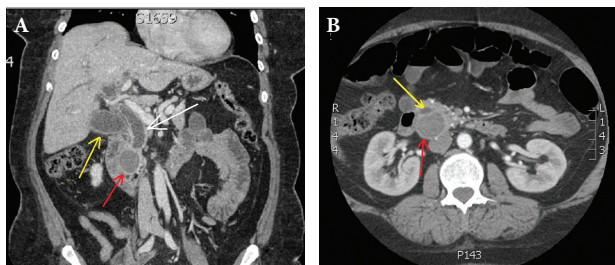


Figure 1 (A) Large heterogenous density mass (red arrow) at the head of pancreas causing marked common hepatic (yellow arrow) and common bile duct (white arrow) dilatation measuring up to 17 mm. (B) Transverse view of same mass (red arrow) at the head of pancreas causing significant pancreatic duct (yellow arrow) dilatation

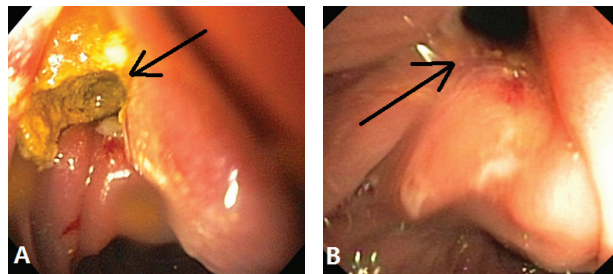


Figure 2 (A) Large severe food impaction was seen in a juxtampillary duodenal diverticulum. (B) Food bezoar was disimpacted revealing the lumen of the juxtampillary duodenal diverticulum

observed in this case. Although anecdotal, this case suggests endoscopy as a safe and effective alternative treatment modality to impacted JPDD. Furthermore, because the clinical and radiological findings associated with an impacted JPDD can be very similar to pancreatic neoplasm, cysts or abscess; therefore, it is important to consider impacted juxtampillary duodenal diverticulum in the differential diagnosis in patients presenting with obstructive jaundice and pancreatic head mass.

References

1. Lotveit T, Osnes M. Duodenal diverticula. *Scand J Gastroenterol* 1984;**19**:579-581.
2. Banwait KS, Sanaka MR, Spodik M, et al. Characteristics of juxtampillary duodenal diverticula (JPDD) in patients undergoing ERCP at a tertiary care center. *Gastrointest Endosc* 2006;**63**:AB295.
3. Armengol-Miro JR, Villagrasa M, Formiguera J, et al. Preampillary intradiverticular bezoar as a cause of obstructive jaundice. Removed by endoscopy. *Endoscopy* 1977;**9**:247-249.
4. Macari M, Lazarus D, Israel G, Megibow A. Duodenal diverticula mimicking cystic neoplasms of the pancreas: CT and MR imaging findings in seven patients. *Am J Roentgenol* 2003;**180**:195-199.
5. Gudjonsson H, Gamelli RL, Kaye MD. Symptomatic biliary obstruction associated with juxtampillary duodenal diverticulum. *Dig Dis Sci* 1988;**33**:114-121.
6. Van der Linde K, van der Linden GH, Beukers R, Cleophas TA. Food impaction in a duodenal diverticulum as an unusual cause of biliary obstruction: case reports and review of the literature. *Eur J Gastroenterol Hepatol* 1997;**9**:635-639.

Departments of ^aInternal Medicine (Yang Liu); ^bGastroenterology (Paul B. Lamb, Michael Piesman), Brooke Army Medical Center, San Antonio Uniformed Services Health Education Consortium (SAUSHEC), Ft. Sam Houston, Texas, USA

Disclaimer The opinion or assertions contained herein are the private views of the authors and are not to be construed as official or reflecting the view of the US Department of the Army of the US Department of Defense

Conflict of Interest: None

Correspondence to: Yang Liu, MD, Internal Medicine Department, Brooke Army Medical Center, 3851 Roger Brooke Drive, Fort Sam Houston, TX 78234, USA, Tel.: +210 916 5910, e-mail: Yang.liu.1@us.af.mil

Received 28 February 2013; accepted 28 February 2013