

## Mucosal healing in ulcerative colitis: surveillance or colectomy?

Gianluca Andrisani, Alfredo Papa, Luisa Guidi, Alessandro Armuzzi

Complesso Integrato Columbus, Catholic University, Rome, Italy

A 38-year-old patient presented with bloody diarrhea (7 to 8 bowel movements per day), abdominal pain and weight loss. Blood tests showed moderate anemia and an increased C-reactive protein. Stool culture and *Clostridium difficile* toxin were negative. Ileocolonoscopy revealed moderate-severe pancolitis: the mucosa from rectum to cecum showed superficial and deep ulcers, friability and spontaneous bleeding of mucosa. Histology showed characteristic findings of ulcerative colitis (UC). He was treated for 5 days with i.v. methylprednisolone without improvement and then he started infliximab therapy. Intestinal symptoms significantly improved after induction. One-year colonoscopy showed mucosal healing (MH) with diffuse pseudopolyps (Fig. 1 A,B). MH has an important role in determining treatment effectiveness and long-term prognosis in patients with UC. MH in UC is linked with a lower risk of relapse, a reduced risk of colorectal cancer, a decreased need for surgery and improved quality of life [1]. Surveillance colonoscopy is strongly recommended to control the increased risk of colorectal carcinoma in patients with long-standing UC [2]. MH in UC is currently defined as “absence of friability, blood, erosions and ulcers in all the visualized segments” [3]. In this patient, the Mayo endoscopic score is 0, but the presence of numerous large pseudopolyps raises some questions: could the endoscopic findings be defined as complete MH? How does one implement and manage surveillance in this patient: colonoscopy or colectomy?

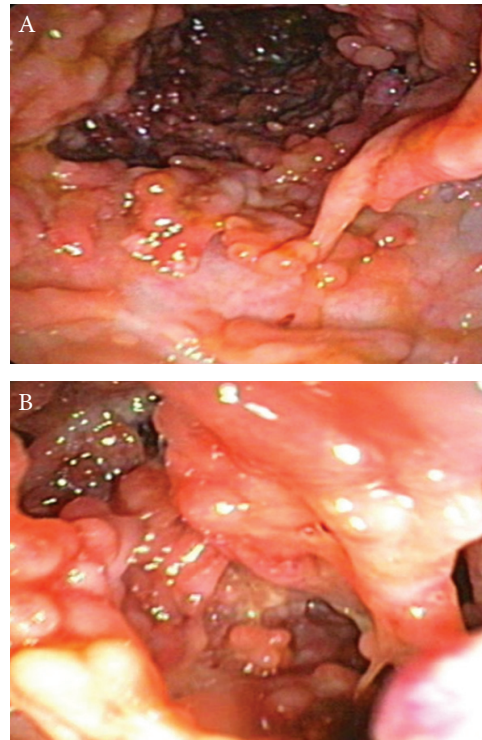


Figure 1 (A,B) Mucosal healing with diffuse pseudopolyps

Internal Medicine and Gastroenterology Unit, Complesso Integrato Columbus, Catholic University, Rome, Italy

Correspondence to: Dr. Alessandro Armuzzi, IBD Unit, Complesso Integrato Columbus, Università Cattolica del Sacro Cuore, Via Moscatti 31-33, 00168 Roma, Italy, e-mail: alearmuzzi@yahoo.com

Conflict of Interest: Luisa Guidi and Alessandro Armuzzi: educational grants and lecture fees from Abbott and MSD. Gianluca Andrisani and Alfredo Papa: None

Received 6 May 2013; accepted 8 May 2013

### References

1. Lichtenstein GR, Rutgeerts P. Importance of mucosal healing in ulcerative colitis. *Inflamm Bowel Dis* 2010;**16**:338-346.
2. Dyson JK, Rutter MD. Colorectal cancer in inflammatory bowel disease: what is the real magnitude of the risk? *World J Gastroenterol* 2012;**18**:3839-3848.
3. D'Haens G, Sandborn WJ, Feagan BG, et al. A review of activity indices and efficacy end points for clinical trials of medical therapy in adults with ulcerative colitis. *Gastroenterology* 2007;**32**:763-786.