

An educational intervention to improve the endoscopist's ability to correctly diagnose small gastric lesions using magnifying endoscopy with narrow-band imaging

Katsuhiko Mabe^a, Kenshi Yao^b, Masanori Nojima^{c,e}, Tokuma Tanuma^d, Mototsugu Kato^a

Hokkaido University Hospital; Fukuoka University Chikushi Hospital; Teine Keijinkai Hospital; Institute of Medical Science, University of Tokyo, Japan

Abstract

Background Magnifying endoscopy with narrow-band imaging (ME-NBI) and a simple and systematic classification system based on microvascular and microsurface patterns, the "VS" classification system (VSCS), have been shown to be useful for the diagnosis of early gastric cancer. The aim of this study was to clarify whether an educational lecture about the VSCS improves performance with ME-NBI.

Methods Sixty-four gastrointestinal endoscopists took the 1st exam before receiving the lecture about the VSCS, the 2nd exam immediately after the lecture, and the 3rd exam 2 months after the lecture. We compared the VSCS-based diagnostic accuracy among the participants before and after the lecture.

Results The proportion of correct diagnoses was significantly higher, at 70.8% in the 2nd exam than in the 1st exam, at 53.1% ($P < 0.001$). The correct diagnosis rate in the 3rd exam was significantly lower than that in the 2nd exam (60.9% vs. 70.8%; $P < 0.001$) but was still higher than that in the 1st exam (60.9% vs. 53.1%; $P < 0.001$). The difference in proportion of correct diagnosis between the 2nd and the 3rd exams was smaller among routine ME-NBI practitioners ($n=6$; 79.2% and 76.1%, respectively), compared to that among non-routine practitioners ($n=34$; 71.6% and 59.8%, respectively) or non-practitioners ($n=24$; 67.5% and 58.8%, respectively).

Conclusion This study revealed that an educational intervention increased correct diagnosis rate of small gastric lesions using the VSCS, diagnosis criteria based on ME-NBI and also showed that the routine use of the modality and the diagnosis criteria was necessary to maintain diagnostic skills.

Keywords Magnifying endoscopy, narrow-band imaging, gastric cancer, educational intervention, diagnostic performance

Ann Gastroenterol 2014; 27 (2): 149-155

^aDivision of Endoscopy, Hokkaido University Hospital, Sapporo city, Hokkaido (Katsuhiko Mabe, Mototsugu Kato); ^bDepartment of Endoscopy, Fukuoka University Chikushi Hospital, Chikushino city, Fukuoka (Kenshi Yao); ^cDepartment of Public Health, Sapporo Medical University, Sapporo city, Hokkaido (Masanori Nojima); ^dCenter for Gastroenterology, Teine Keijinkai Hospital, Sapporo city, Hokkaido (Tokuma Tanuma); ^eDivision of Advanced Medicine Promotion, The Advanced Clinical Research Center, Institute of Medical Science, University of Tokyo, Tokyo (Masanori Nojima), Japan

Conflict of Interest: None

Correspondence to: Katsuhiko Mabe, Division of Endoscopy, Hokkaido University Hospital, North 14, West-5, Kita-ku, Sapporo, Hokkaido 0608648, Japan, Tel.: +81 11 716 1169 (ext. 5920), Fax: +81 11 706 7867, e-mail: kmabe@med.hokudai.ac.jp

Received 16 July 2013; accepted 27 October 2013

Introduction

Gastric cancer represents the second leading cause of cancer death worldwide, with some 50,000 individuals dying annually from the disease in Japan, where early endoscopic detection of gastric cancer remains the cornerstone that contributes not only to a decrease in mortality from gastric cancer but also to optimization of care, with the use of endoscopic mucosal resection (EMR) or endoscopic submucosal dissection (ESD) being reserved for a subset of patients with early gastric cancer. However, endoscopic diagnosis of gastric lesions, particularly differential diagnosis of small benign versus malignant lesions in the stomach, remains far more difficult than that in the colon and rectum with colonoscopy, due to the background presence of chronic inflammation associated with *Helicobacter pylori* infection [1].

To date, various modalities and image enhancement techniques have been developed to improve the accuracy of endoscopy-based diagnosis. Briefly, in addition to chromoendoscopy [2-4], acetic acid spray [5], and magnifying endoscopy [6], recently, narrow-band imaging (NBI) [7], autofluorescence imaging [8], and endocytoscope with a 450-fold magnification power [9], have been reported to have great promise in improving diagnostic accuracy. However, the usefulness of these novel diagnostic modalities involving the use of cutting-edge equipment has mainly been reported from tertiary care centers, such as university hospitals, with most of these modalities remaining still less readily available for clinical use in general hospitals and clinics.

Of these, the NBI and magnifying endoscopy have recently become available in a considerable number of hospitals in Japan, where the NBI has become established as a modality that allows recognition of squamous epithelial lesions in the laryngopharynx and esophagus as "brownish areas", as well as detailed, qualitative studies of the intraepithelial papillary capillary loops of the squamous mucosa when combined with magnifying endoscopy [10].

As it involves the use of an optical filter with narrow-band transmission, however, the NBI is less well suited for detection of lesions in the stomach with wide lumens. On the other hand, the NBI combined with magnifying endoscopy (ME-NBI) allows differential diagnosis of gastric lesions [11-15] as well as determination of gastric cancer margins [16-17], although ME-NBI still remains less well established among endoscopists, with disparate diagnostic classifications proposed for ME-NBI-guided diagnosis [11-15]. Of the classifications reported to date, the VS classification system (VSCS) proposed by Yao *et al* [14,15] as a simple yet comprehensive classification, appears to have great potential for widespread use.

However, no study has been conducted, to date, to investigate whether an educational intervention may result in improvements in diagnostic accuracy.

We therefore aimed in this study to investigate whether an educational lecture on the VSCS-based, ME-NBI-guided diagnosis might contribute to improvement in the accuracy of ME-NBI-guided diagnosis of benign lesions versus early gastric cancers among endoscopists who received the lecture in this study.

Materials and methods

The present study included gastrointestinal endoscopists who consisted of Japan Gastroenterological Endoscopy Society board-certified (specialist) and non-board-certified (non-specialist) endoscopists including trainees from the Hokkaido area, Japan, to receive a lecture on the VSCS in order to compare the accuracy of ME-NBI-based diagnosis of random, sample ME-NBI images of gastric lesions among the participants before and after the lecture.

The ME-NBI images of gastric lesions used for simulated diagnosis had been taken by the original advocate of the VSCS (K.Y.) from patients treated at Fukuoka University Chikushi Hospital and affiliated hospitals by using magnifying endoscopy (GIF-H260Z, GIF-240Z; Olympus Corporation, Tokyo, Japan) at maximum magnification (approximately x80), equipped with a soft black hood (MB-162 for GIF-Q240Z, MB-46 for GIF-H260Z; Olympus Corporation, Tokyo, Japan) and a light source (CV-260SL; Olympus Corporation, Tokyo, Japan) (ME-NBI), and the diagnosis of each lesion depicted by the ME-NBI had earlier been histologically confirmed based on biopsy or resected specimens.

In conjunction with the use of the ME-NBI images, it was ensured that all personal information, such as patient name, ID number, sex, and age, by which an individual could be identified, was omitted from the images. Approval was obtained from the institutional review board of the Hokkaido University Hospital for this study using ME-NBI images from patients treated at another tertiary care center to compare diagnostic outcomes.

Three sets of questions were developed by the instructor with each involving a total of 20 ME-NBI images of small gastric mucosal lesions (10 non-cancerous and 10 cancerous lesions). The exams consisted of multiple-choice questions that had to do with: 1) the demarcation line (DL); 2) the microvascular pattern; 3) the microsurface pattern; and 4) endoscopic diagnosis (1. benign; 2. potentially benign; 3. potentially malignant; 4. malignant; and 5. unknown) (Fig. 1). The participants were blinded to the content of the exam questions and the histological diagnosis of each lesion used during the exams.

The educational lecture was given by the advocate of the VSCS (K.Y.) on January 12, 2011, in which still ME-NBI images were used to illustrate the VSCS-based, ME-NBI-guided diagnosis. Prior to the lecture, the participants were given instructions about the exams and how to answer the exam questions. Participants took the 1st exam before receiving the lecture about VSCS, the 2nd exam immediately after the lecture, and the 3rd exam 2 months later to compare the accuracy of VSCS-based diagnosis among the participants (Fig. 2). Gastric cancers were diagnosed in the exams in accordance with the VSCS, i.e., in terms of the presence of an irregular microvascular pattern with a demarcation line or the presence of an irregular microsurface pattern with a demarcation line. All completed answer sheets for each exam were collected from the participants at the completion of the study.

Statistical analysis

The main outcome measure was the improvement in the proportion of correct diagnosis after the lecture. A correct diagnosis was judged to have been made in accordance with the VSCS in the exams if the diagnosis made was consistent with the findings identified on the demarcation line, the

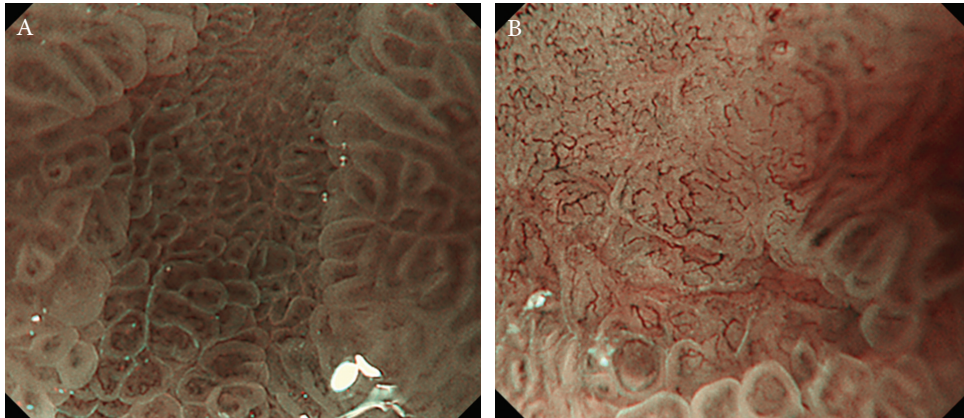


Figure 1 Examples of the magnifying endoscopy with narrow-band imaging images of gastric lesions used for the exams. (A) Non-cancerous lesion with a demarcation line but without an irregular microvascular or irregular microsurface pattern (intestinal mataplasia). (B) Gastric cancer with a demarcation line, irregular microvascular and microsurface patterns

microvascular pattern, and the microsurface pattern, which represented the major diagnostic components of the VSCS, and thus met the VSCS criteria. In addition, it was calculated separately in malignant lesions and benign lesions. In detail, the proportion of correct diagnosis was individually calculated as the number of the correct diagnosis divided by the number of questions, and then their means were calculated. The means were compared by using the *t*-test (between unpaired two groups), ANOVA with *post hoc* Tukey Kramer test (between more than two unpaired groups), paired *t*-test (between two paired groups), or multiple paired *t*-test with Bonferroni's correction (between more than two paired groups). Other continuous variables were also compared by using the *t*-test. Categorical variables were compared by using Fisher's exact test or chi-square test. Ordinal variables were compared by using Mann-Whitney test. All statistical analyses were performed by using SPSS 20 (IBM). *P* values of <0.05 were considered statistically significant.

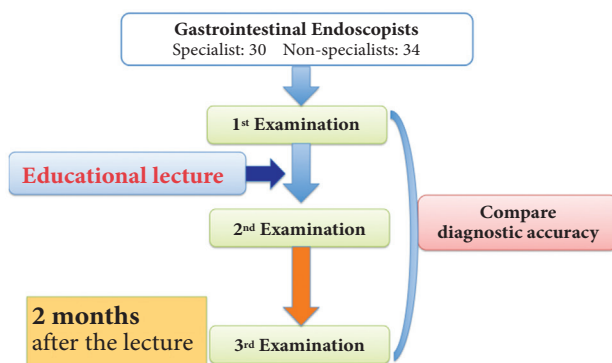


Figure 2 Protocol design of the study. A total of 64 endoscopists (34 specialists and 30 non-specialists) attended the lecture and completed all exams, and were eligible for analysis in this study. They took the 1st exam before receiving the lecture about the microvascular and microsurface classification system, the 2nd exam immediately after the lecture and the 3rd exam 2 months after the lecture

Results

A total of 64 endoscopists (34 specialists and 30 non-specialists) attended the lecture, completed all exams and were eligible for analysis in this study. The characteristics of participants are summarized in Table 1. There was a significant difference between the specialists and the non-specialists with regard to experience with endoscopy, magnifying endoscopy, and ESD. However, there was no difference between the groups with regard to their possession of textbooks describing the VSCS, participation in VSCS-related lectures, and frequency of use of magnifying endoscopy (Table 1).

The average proportion of correct diagnosis among the participants was significantly higher in the 2nd exam at 70.8% than in the 1st exam (before the lecture) at 53.1% ($P<0.001$), with significant improvement also noted in malignant lesions (2nd exam, 70.8%; 1st exam, 47.0%; $P<0.001$) and in benign lesions (2nd exam, 70.8%; 1st exam, 59.2%, $P<0.001$) (Table 2). A comparison of the diagnostic performance as stratified by board-certification status showed that the proportion of correct diagnosis in malignant and benign lesions were both significantly improved in the 2nd exam, compared to the 1st exam. Furthermore, although the proportion of correct diagnosis (total) was significantly different between the specialists (56.8%) and the non-specialists (49.0%) in the 1st exam ($P=0.009$), no significant difference was observed between the specialists (71.8%) and the non-specialists (69.7%) in the 2nd exam ($P=0.597$) (Table 2). Again, the proportion of correct diagnosis in the 3rd exam 2 months after the lecture was significantly lower at 60.9% than in the 2nd exam ($P<0.001$), but was higher than that in the 1st exam (53.1%) ($P<0.001$). No significant difference was observed between the specialists (60.4%) and the non-specialists (61.6%) in the 3rd exam ($P=0.752$) (Table 2, Fig. 3).

A comparison of the participants by frequency of use of magnifying endoscopy in their practice showed that there was a significant improvement among the participants in the 2nd exam, compared to the 1st exam, regardless of frequency of

Table 1 Characteristics of the participants in this study

	Non-specialists (n=30)	Specialists (n=34)	Total (n=64)	P value
Endoscopic experience (years)	4.9 ± 5.6	16.7 ± 6.9		<0.001*
Number of endoscopic procedures with magnifying endoscopy				
< 50	26	20	46	0.011†
51-100	2	4	6	
101-500	2	9	11	
> 501	0	1	1	
Experience with ESD				
No	17	10	27	0.042‡
Yes	13	24	37	
Possession of VSCS textbooks				
No	19	25	44	0.427‡
Yes	11	9	20	
Past participation in VSCS lectures				
No	13	10	23	0.301‡
Yes	17	24	41	
Frequency of use of magnifying endoscopy				
No, I do not use it	14	15	24	
Yes, I use it sometimes (for in-depth exams only)	15	19	34	
Yes, I routinely use it	1	5	6	0.080†

* *t*-test, † *Mann-Whitney test*, ‡ *Fisher's exact test*

ESD, endoscopic submucosal dissection; VSCS, microvascular and microsurface classification system

use of magnifying endoscopy, while there was a significant decrease in the correct diagnosis rate in the 3rd exam among the participants except for the routine ME-NBI users, compared to that in the 2nd exam. Furthermore, while there was no significant difference in the correct diagnosis rate among the participants in both the 1st and 2nd exams, there was a significant difference in the correct diagnosis rate between the routine ME-NBI users and the other endoscopists. Of note, the difference in the proportion of correct diagnosis between the 2nd exam and the 3rd exam was much smaller among the routine ME-NBI users ($n=6$; 79.2% to 76.1%), compared to that among the non-routine users ($n=34$; 71.6% to 59.8%) or the non-users ($n=24$; 67.5% to 58.8%) (Table 3, Fig. 4).

Discussion

Early endoscopic diagnosis of gastric mucosal lesions, particularly differential diagnosis between non-cancerous and cancerous lesions, is critically important in determining or obviating the need for endoscopic biopsy or therapy.

Novel diagnostic approaches involving the use of chromoendoscopy, magnifying endoscopy, and new spectrum endoscopy have been reported to be useful in improving the accuracy of endoscopic diagnosis. In this regard, the ME-NBI

has been reported to be useful in the diagnosis of gastric cancer [11-16], as well as in the recognition of gastric cancerous margins [17,18]. In a prospective study [19], the ME-NBI

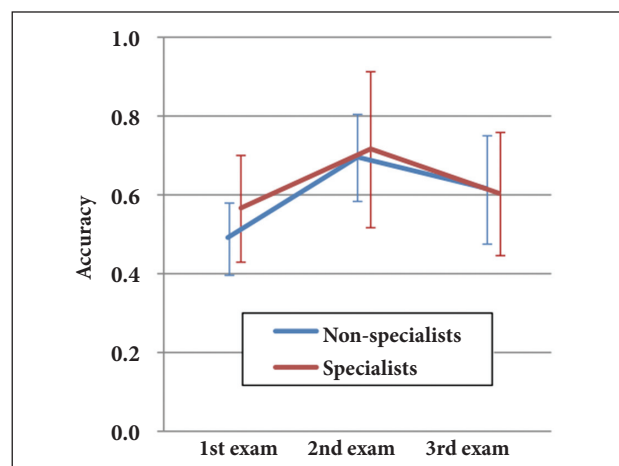


Figure 3 The difference of the accuracy between specialists and non-specialists before and after the lecture. This shows the accuracy as stratified by board-certification status. Accuracy was significantly different between the specialists (56.8%) and the non-specialists (49.0%) before the lecture but no significant difference was observed after the lecture

Table 2 The average proportion of correct diagnosis before and after the lecture

		1st		2nd		3rd		P value*			
		N	Mean	SD	Mean	SD	Mean	SD	1st vs. 2nd	1st vs. 3rd	2nd vs. 3rd
All endoscopists	Total	64	0.531	0.120	0.708	0.157	0.609	0.145	<0.001	0.001	<0.001
	In malignant lesions	64	0.470	0.183	0.708	0.226	0.618	0.220	<0.001	<0.001	0.002
	In benign lesions	64	0.592	0.204	0.708	0.197	0.601	0.177	0.002	1.000	<0.001
Non-specialists	Total	30	0.490	0.135	0.697	0.198	0.616	0.155	<0.001	0.002	0.004
	In malignant lesions	30	0.433	0.215	0.707	0.264	0.604	0.214	<0.001	0.004	0.010
	In benign lesions	30	0.547	0.224	0.687	0.229	0.627	0.181	0.028	0.360	0.286
Specialists	Total	34	0.568	0.091	0.718	0.110	0.604	0.138	<0.001	0.298	<0.001
	In malignant lesions	34	0.503	0.145	0.709	0.191	0.629	0.227	<0.001	0.023	0.158
	In benign lesions	34	0.632	0.179	0.726	0.166	0.578	0.173	0.072	0.470	<0.001
P value for difference between groups†	Total			0.009		0.597		0.752			
	In malignant lesions			0.130		0.970		0.654			
	In benign lesions			0.094		0.424		0.280			

* Multiple pairwise comparisons by paired t-test with Bonferroni's correction

† Comparison between non-specialists and specialists in each test
SD, standard deviation

has also been reported to be more useful in the diagnosis of small depressed gastric lesions than magnifying endoscopy with a regular light source.

Commercially available NBI systems allow the endoscopists to alternate readily between normal white-light and NBI viewing modes simply by pressing a button on the handle of the endoscope. However, the ME-NBI has remained less well established as a diagnostic modality among the endoscopists, with various diagnostic classifications proposed for ME-NBI-guided diagnosis [11-15].

In this regard, the VS classification system (VSCS) proposed by Yao *et al* [14,15] is of particular interest, in that it draws on a combination of findings on 1) the demarcation line; 2) the microvascular pattern; 3) the microsurface pattern, where any lesion with a demarcation line and an irregular microvascular pattern or/and an irregular microsurface pattern is diagnosed as gastric cancer, with all other lesions which fail to meet these criteria diagnosed as non-cancerous lesions. While some of the proposed classifications are intended for in-depth diagnosis including the histological type of tumor, the VSCS represents a simple yet comprehensive diagnostic classification system which is readily available for widespread use among specialist and non-specialist endoscopists alike.

Our study findings showed that educational lectures on the VSCS improve the ability of both specialist and non-specialist endoscopists to correctly diagnose small gastric lesions using ME-NBI and this improvement appears to have been accounted for by improvement in VSCS-based diagnosis, demonstrating both the utility of the VSCS in the diagnosis of gastric lesions and the usefulness of educational lectures on the VSCS in improving diagnostic accuracy. This study also revealed that

the routine use of ME-NBI and the VSCS was necessary to maintain high diagnostic accuracy after the educational lecture.

Although the VSCS and the ME-NBI were used for the differential diagnosis of small gastric lesions in this study, both the VSCS and the ME-NBI are also shown to be useful in the

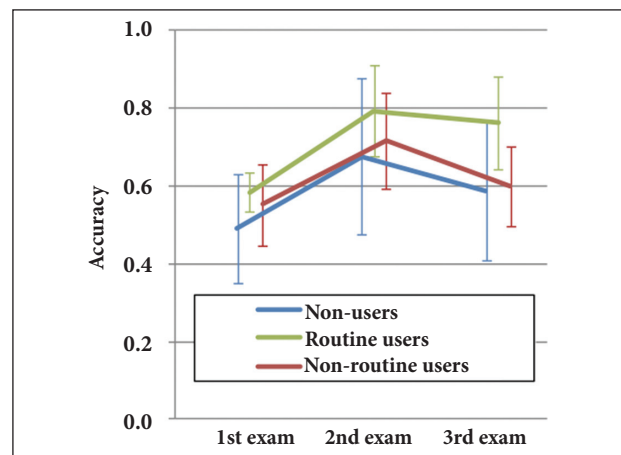


Figure 4 Proportion of correct diagnoses made in accordance with the VSCS by frequency of use of magnifying endoscopy in each exam. This figure shows the accuracy by frequency of use of magnifying endoscopy in each exam. The difference in diagnostic accuracy between the 2nd and the 3rd exams was smaller among routine magnifying endoscopy with narrow-band imaging practitioners (n=6; 79.2% and 76.1%, respectively), compared to that among non-routine practitioners (n=34; 71.6% and 59.8%, respectively) and non-practitioners (n=24; 67.5% and 58.8%, respectively)

Table 3 Diagnostic accuracy before and after the lecture by frequency of use of magnifying endoscopy in each exam

Frequency of use of magnifying endoscopy	1st		2nd		3rd		P value*			
	n	Mean	SD	Mean	SD	Mean	SD	1st vs. 2nd	1st vs. 3rd	2nd vs. 3rd
a. Non-users	24	0.490	0.141	0.675	0.199	0.588	0.180	<0.001	0.061	0.036
b. Non-routine users	34	0.551	0.104	0.716	0.122	0.598	0.103	<0.001	0.163	<0.001
c. Routine users	6	0.583	0.052	0.792	0.116	0.761	0.120	0.006	0.011	1.000
		Difference	P†	Difference	P†	Difference	P†			
a vs. b		0.062	0.123	0.041	0.540	0.011	0.956			
a vs. c		0.094	0.192	0.117	0.235	0.174	0.021			
b vs. c		0.032	0.812	0.075	0.520	0.163	0.027			

* Multiple pairwise comparisons by paired t-test with Bonferroni's correction

† Multiple comparisons between groups in each test by Tukey Kramer test
SD, standard deviation

recognition of gastric cancer demarcation lines [15,17,18], which is particularly important for *en bloc* resection in ESD which allows resection of large lesions. In this regard, the educational lecture on the VSCS-based, ME-NBI-guided diagnosis as it was given in this study was also thought to assist in determining gastric cancerous margins.

The present study has some limitations. It is not an *in vivo* study. The diagnostic process can be divided into two steps, detection and characterization [20]. While endoscopic diagnosis in a real-world, clinical setting calls for ME-NBI-based imaging techniques, as well as the ability to perform real-time detection technique and diagnoses, in addition to the diagnostic capabilities evaluated in this study, the study used only still images taken by an expert endoscopist in comparing diagnostic performance. Indeed, a tailored training program is required to enable endoscopists to perform accurate ME-NBI-guided diagnoses, as shown in the ME-NBI-guided diagnosis of colorectal lesions [21,22]. Thus, this limitation needs to be taken into account when considering the study and its contributions.

On-site educational lectures by expert endoscopists may also have limited contributions to improvement in diagnostic performance. In this regard, web-based training programs have been reported to be useful [23], suggesting that future educational lectures may have greater contributions when presented in media that provide a larger number of physicians with the benefit of repeated learning and testing, such as web-based programs or DVDs.

In conclusion, an educational lecture about the VSCS improved the accuracy of ME-NBI-guided diagnosis of gastric mucosal lesions. The routine use of VSCS-based ME-NBI may be required to maintain high diagnostic performance as well as to obviate the need for biopsies to rule out malignancies and allow safe and early diagnosis of gastric cancer.

Acknowledgments

The authors thank all endoscopists who attended the lecture and participated in the study

Summary Box

What is already known:

- Various modalities and image enhancement techniques have been developed to improve the accuracy of endoscopy-based gastric cancer diagnosis
- Magnifying endoscopy with narrow-band imaging (ME-NBI) has been shown to be useful for the differential diagnosis of gastric lesions as well as determination of gastric cancer margins
- The "VS" classification system (VSCS), one of the classifications for ME-NBI-guided diagnosis, has been shown to be useful for the diagnosis of early gastric cancer

What the new findings are:

- An educational intervention about the VSCS improved the accuracy of ME-NBI-based diagnosis among endoscopists, regardless of the board-certification status, suggesting that the VSCS may have potential for widespread use in conjunction with ME-NBI
- The routine use of VSCS-based ME-NBI may be required to maintain high diagnostic performance

References

1. Dinis-Reberio M, Areia M, De Vries AC, et al. Management of precancerous conditions and lesions in the stomach (MAPS): guideline from the European Society of Gastrointestinal Endoscopy (ESGE), European Helicobacter Study Group (EHSG), European Society of Pathology (ESP), and the Sociedade Portuguesa de Endoscopia Digestiva (SPED). *Endoscopy* 2012;44:74-94.

2. Ida K, Hashimoto Y, Takeda S, Murakami K, Kawai K. Endoscopic diagnosis of gastric cancer with dye scattering. *Am J Gastroenterol* 1975;**63**:316-320.
3. Szaloki T. Indigo carmine contrast staining in combination with high resolution endoscopy. *Orv Hetil* 2002;**143**:25-29.
4. Sakai Y, Eto R, Kasanuki J, et al. Chromoendoscopy with indigo carmine dye added to acetic acid in the diagnosis of gastric neoplasia: a prospective comparative study. *Gastrointest Endosc* 2008;**68**:635-641.
5. Longcroft-Wheaton G, Duku M, Mead R, Poller D, Bhandari P. Acetic acid spray is an effective tool for the endoscopic detection of neoplasia in patients with Barrett's esophagus. *Clin Gastroenterol Hepatol* 2010;**8**:843-847
6. Tajiri H, Doi T, Endo H, et al. Routine endoscopy using a magnifying endoscope for gastric cancer diagnosis. *Endoscopy* 2002;**34**:772-777.
7. Yao K, Oishi T, Matsui T, Yao T, Iwashita A. Novel magnifying endoscopic findings of microvascular architecture in intramucosal gastric cancer. *Gastrointest Endosc* 2002;**56**:279-284.
8. Uedo N, Iishi H, Tatsuta M, et al. A novel videoendoscopy system by using autofluorescence and reflectance imaging for diagnosis of esophagogastric cancers. *Gastrointest Endosc* 2005;**62**:521-528.
9. Inoue H, Sasajima K, Kaga M, et al. Endoscopic in vivo evaluation of tissue atypia in the esophagus using a newly designed integrated endocytoscope: a pilot trial. *Endoscopy* 2006;**38**:891-895.
10. Muto M, Minashi K, Yano T, et al. Early detection of superficial squamous cell carcinoma in the head and neck region and esophagus by Narrow band imaging: a multicenter randomized controlled trial. *J Clin Oncol* 2010;**28**:1566-1572.
11. Nakayoshi T, Tajiri H, Matsuda K, Kaise M, Ikegami M, Sasaki H. Magnifying endoscopy combined with narrow band imaging system for early gastric cancer: Correlation of vascular pattern with histology (including video). *Endoscopy* 2004;**36**:1080-1084.
12. Tanaka K, Toyoda H, Kadowaki H, et al. Surface pattern classification by enhanced-magnification endoscopy for identifying early gastric cancers. *Gastrointest Endosc* 2008;**67**:430-437.
13. Nakamura M, Shibata T, Tahara T, et al. The usefulness of magnifying endoscopy with narrow-band imaging to distinguish carcinoma in flat elevated lesions in the stomach diagnosed as adenoma by using biopsy samples. *Gastrointest Endosc* 2010;**71**:1070-1075.
14. Yao K, Takaki Y, Matsui T, Iwashita A, Anagnostopoulos GK, Kaye P, Ragunath K. Clinical application of magnification endoscopy and narrow band imaging in the upper gastrointestinal tract: new imaging techniques for detecting and characterizing GI neoplasia. *Gastrointest Endosc Clin N Am* 2008;**18**:415-433.
15. Yao K, Anagnostopoulos GK, Ragunath K. Magnifying endoscopy for diagnosing and delineating early gastric cancer. *Endoscopy* 2009;**41**:462-467.
16. Ezoe Y, Muto M, Uedo N, et al. Magnifying narrowband imaging is more accurate than conventional white light imaging in diagnosis of gastric mucosal cancer. *Gastroenterology* 2011;**141**:2017-2015.
17. Kadowaki S, Tanaka K, Toyoda H, et al. Ease of early gastric cancer demarcation recognition: A comparison of four magnifying endoscopy methods. *J Gastroenterol Hepatol* 2009;**24**:1625-1630.
18. Kiyotoki S, Nishikawa J, Satake M, et al. Usefulness of magnifying endoscopy for determining gastric tumor margin. *J Gastroenterol Hepatol* 2010;**25**:1636-1641.
19. Ezoe Y, Muto M, Horimatsu T, et al. Magnifying narrow-band imaging versus magnifying white-light imaging for the different diagnosis of gastric small depressive lesions: a prospective study. *Gastrointest Endosc* 2010;**71**:477-484.
20. Yao K. The endoscopic diagnosis of early gastric cancer. *Ann Gastroenterol* 2013;**26**:11-22.
21. Higashi R, Uraoka T, Kato J, et al. Diagnostic accuracy of narrow-band imaging and pit pattern analysis significantly improved for less-experienced endoscopists after an expanded training program. *Gastrointest Endosc* 2010;**72**:127-135.
22. Ignjatovic A, Thomas-Gibson S, East JE, et al. Development and validation of a training module on the use of narrow-band imaging in differentiation of small adenomas from hyperplastic colorectal polyps. *Gastrointest Endosc* 2011;**73**:128-133.
23. Dinis-Riberio M, Correia RC, Santos C, et al. Web-based system for training and dissemination of a magnification chromoendoscopy classification. *World J Gastroenterol* 2008;**14**:7086-7092.