

Two ileocecal valve lipomas

Mohamed Amine Benatta^a, Ariane Desjeux^b, Jean Charles Grimaud^b

University Military Hospital Oran, Algeria; Hopital Nord Marseille, France

A 68-year-old woman presented with a 4-year unexplained intermittent abdominal pain recently complicated with rapidly transient obstruction episodes. Physical examination, plain radiograph and ultrasound of the abdomen were normal. At colonoscopy, a submucosal tumor (Fig. 1A) 0.5 cm in diameter prolapsing through the ileocecal valve was found. On removal of the tumor, after endoloop placement, a second tumor with the same endoscopic features but of 1.5 cm length was discovered, overlying mucosa looking normal. The two tumors were removed by electro-surgical snare polypectomy, a yellowish color at the base of both tumors was noted (Fig. 1B). Regarding the valvular location of the double resection a preventive Endoclip was placed (Fig. 1C). At histology the two tumors were covered by normal mucosa and consisted of adipose tissue. The lipomas presumably had been prolapsing intermittently through the ileocecal valve causing transient obstruction [1]. In our case, as in a previously reported prolapsing terminal ileal lipoma [2], no further obstruction symptoms had been noted after endoscopic resection.

Lipoma is a benign tumor, more frequent after the age of 50 years with a female predominance. Ileal location is about 60% in all small intestine lipomas. Intestinal lipomas are asymptomatic in most cases; they may be responsible for abdominal pain, transit disorders or a König's syndrome. The diagnosis of ileal lipoma is often carried out by radiological or endoscopic exploration. Their most frequent complication is represented by ileo-ileal or ileocecal invaginations and degeneration is quite exceptional [3]. For symptomatic lipomas, surgery is the treatment of reference.

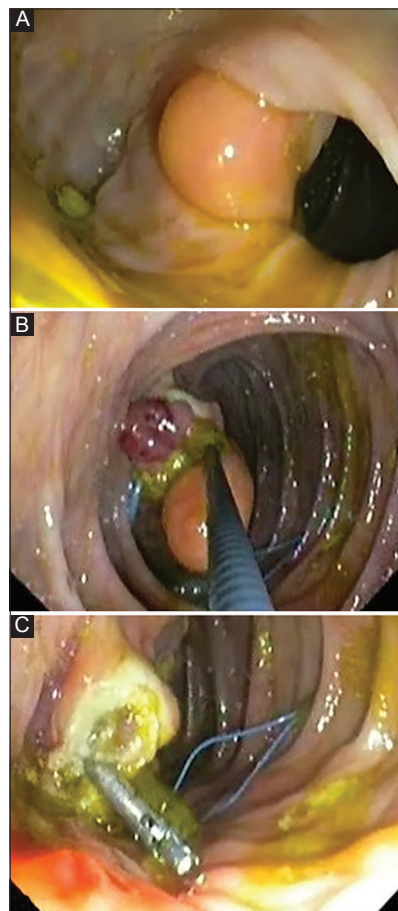


Figure 1 (A) The first ileocecal valve lipoma. (B) The two ileocecal valve lipomas with yellowish color at resection. (C) Endoclip at the double resection site

Gastroenterology Departments ^aUniversitary Military Hospital Oran Algeria (Mohamed Amine Benatta); ^bHospital Nord Marseille France (Ariane Desjeux, Jean Charles Grimaud)

Conflict of Interest: None

Correspondence to: Mohammed Amine Benatta, 156 Bakhti Noubia Oran, Algeria, e-mail: benattaamine@yahoo.fr

Received 15 February 2014; accepted 18 February 2014

References

1. Felig DM. Bowel obstruction due to a large ileal lipoma. *Gastrointest Endosc* 2001;**53**:342.
2. Ito K, Shiraki K, Okano H, Saitou Y, et al. Terminal ileal lipoma. *Gastrointest Endosc* 2004;**60**:260-261.
3. Gourcerol G, Hervé S, Gorla O, et al. Lower gastrointestinal bleeding due to ileal lipoma. Diagnosis contribution of contrast enhanced helical CT. *Gastroenterol Clin Biol* 2004;**28**:185-187.