

# The current and future role of endomicroscopy in the management of inflammatory bowel disease

Douglas L. Nguyen<sup>a</sup>, John G. Lee<sup>a</sup>, Nimisha K. Parekh<sup>a</sup>, Jason Samarasena<sup>a</sup>, Matthew L. Bechtold<sup>b</sup>, Kenneth Chang<sup>a</sup>

University of California-Irvine; University of Missouri-Columbia, USA

## Abstract

Confocal laser-induced endomicroscopy (CLE), first introduced in 2003, allows the capture of images of “virtual histology” of the gastrointestinal mucosa during endoscopy, providing the opportunity to retrieve real-time visualization of the pathology of the mucosal epithelium with its cellular and subcellular structures. This new endoscopic imaging technique serves as an adjunctive diagnostic tool to the traditional ileocolonoscopy in the management of inflammatory bowel disease (IBD) patients. In multiple clinical trials, CLE has been shown to improve detection of dysplasia, assess disease activity, predict future clinical relapses, and assess potential responsiveness to anti-tumor necrosis factor therapy. This review explores in depth the current and future role of CLE in the management of IBD patients.

**Keywords** Inflammatory bowel disease, endomicroscopy, mucosal healing

*Ann Gastroenterol 2015; 28 (3): 331-336*

## Introduction

Endoscopic evaluation of the mucosa of patients with inflammatory bowel disease (IBD) plays an important role in the diagnosis and ongoing management of these patients. Endoscopy allows for the assessment of disease activity, extent of disease, and long-term surveillance of dysplasia. Assessment of mucosal inflammation in IBD patients is important, particularly as the current treatment goal shifts away from clinical improvement towards optimization of medical therapies in order to achieve mucosal healing and preventing subsequent clinical relapses. Ileocolonoscopy with white light illumination has been the traditional gold standard to achieve these clinical purposes.

Confocal laser-induced endoscomicroscopy (CLE), a new and emerging imaging technique, is able to visualize in detail the surface architecture of the mucosa, the mucosal blood vessels, and cellular and subcellular structures in real time. Currently, CLE has been used in various gastrointestinal conditions including evaluation of dysplasia in Barrett's esophagus, colorectal neoplasia, and gastric intestinal

metaplasia [1,2]. Furthermore, this technology provides an important adjunctive tool to standard ileocolonoscopy in the clinical evaluation and management of IBD patients. This review will focus on reviewing the current and future roles of CLE in the management of IBD patients.

## Technical aspects of endomicroscopy

CLE, first introduced in 2003, is a procedure that allows the capture of images of “virtual histology” of the gastrointestinal mucosa during endoscopy, allowing the opportunity to obtain real-time microscopic images of the cellular and subcellular structures of the mucosal epithelium [3,4]. The technique is based on tissue illumination with low power laser light after application of fluorescent agents either systemically (i.e. intravenous fluorescein sodium) or topically (i.e. cresyl violet, acriflavin hydrochloride). Table 1 summarizes some of the current applications of CLE in the management of IBD patients.

Currently, there are two Food and Drug Administration-approved endomicroscopy devices available for clinical use. One is integrated into the distal tip of a standard high-resolution video gastroscop or colonoscop (eCLE; Pentax Medical, Tokyo, Japan) and one is probe-based, capable of passing through the working channel of a standard endoscop (pCLE; Cellvizio, Mauna Kea Technologies, Paris, France). Both systems use an incident 488-nm wavelength laser system. The laser light is reflected from the tissue and then refocused onto the detection system through a pinhole, decreasing the effect of scattered light resulting in the construction of two-dimensional grey-scale images.

The eCLE system collects images at 1000x magnification at a manually adjustable scan rate of 1.6 frames per second.

Departments of Medicine, <sup>a</sup>University of California-Irvine (Douglas L. Nguyen, John G. Lee, Nimisha K. Parekh, Jason Samarasena, Kenneth Chang); <sup>b</sup>University of Missouri-Columbia (Matthew L. Bechtold), USA

Conflict of Interest: Drs. Kenneth Chang and Jason Samarasena are Consultants to Mauna Kea Technologies

Correspondence to: Kenneth Chang, M.D., Clinical Professor of Medicine, Department of Medicine, UC Irvine School of Medicine, 333 City Blvd. West, Suite 400, Orange, CA 92868, USA, Tel.: +1 714 456 6745, Fax: +1 714 456 7753, e-mail: kchang@uci.edu

Received 4 November 2014; accepted 24 December 2014

The imaging field of view is 475  $\mu\text{m}$  in diameter with a lateral resolution of 0.7  $\mu\text{m}$ . With this specialized endoscope, the scanning depth can be dynamically adjusted from 0 to 250  $\mu\text{m}$ . The pCLE system also collects images at 1000x magnification but confocal images are streamed at a 12 frames per second, thereby obtaining real-time video imaging. The imaging field of view is 240  $\mu\text{m}$  with a lateral resolution of 1.0  $\mu\text{m}$ . In contrast to the eCLE system, pCLE has a fixed scanning depth of 55–65  $\mu\text{m}$  [5]. The advantage of the eCLE integrated system is its high resolution while pCLE probe allows for greater versatility given its ability to be used with almost all endoscopes and allows a dynamic examination of the vessels and microarchitecture. Unfortunately, Pentax is no longer manufacturing new endoscopes with eCLE, leaving pCLE the only available technology on the market. Fig. 1 depicts representative images on the pCLE system.

### Can CLE distinguish between Crohn's disease (CD) and ulcerative colitis (UC)?

The diagnostic differentiation between CD and UC remains challenging contemporary gut pathology, but the

**Table 1** Current applications of confocal laser-induced endoscopy (CLE) in the management of inflammatory bowel disease (IBD) patients

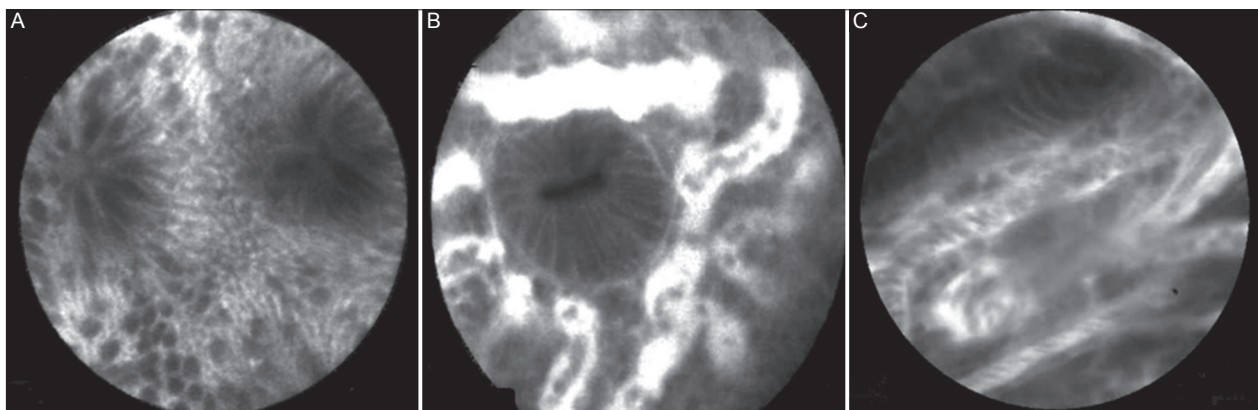
CLE can identify histological changes of Crohn's disease and ulcerative colitis <i>in vivo</i>
CLE can help acquire targeted biopsies during surveillance endoscopy for dysplasia
CLE can identify IBD-associated changes in macroscopically non-inflamed mucosa
CLE can identify predictors of future clinical relapses (i.e., increased epithelial gaps, dynamic vascular changes)
CLE may predict response to anti-tumor necrosis factor antibody therapy through novel labeling techniques
CLE may help clinician step up or step down to individualized therapies even before the development of clinical symptoms

differentiation is important for treatment strategy, surveillance, and surgical management. It often involves a diagnostic orchestration between clinical, endoscopic, radiographic, and histopathologic criteria. In cases where there is an immediate need for a rapid “endodiagnostic tool”, particularly when patients have impaired coagulation or have high perforation risk (i.e. fulminant colitis) where conventional biopsy excision is not possible, CLE can provide a practical alternative [6].

In personal clinical observations by Hundorfean *et al* [6], CLE-based criteria were proposed to help distinguish between CD and UC. In CD, mucosal fissures, focal cryptitis, granulomas, and microscopic inflammation of the terminal ileum were seen. In contrast, UC patients often had characteristic bifid crypts, shortened and branched crypts with a microscopically normal terminal ileum [6,7]. However, further studies are necessary to validate these CLE criteria in the differentiation between CD and UC. Additionally, with future technical refinement of CLE, deeper microscopic aspects beyond 250  $\mu\text{m}$  may allow for visualization of features such as submucosal granulomas or thickening of muscularis mucosae, which may allow for further refinement of these diagnostic features.

### Assessment of disease activity

Assessment of mucosal inflammation in IBD patients is important, particularly the current treatment goal being shifted away from clinical improvement towards optimization of medical therapies in order to achieve endoscopic and mucosal healing [8]. This shift in treatment paradigm has been shown to improve both short- and long-term outcomes [9]. Recent studies have demonstrated that IBD patients with mucosal healing have decreased need for hospitalization, active treatment surgical resections, and were associated with sustained clinical remission [9–11]. Current definition of mucosal healing is generally viewed as the absence of ulceration. However, the spectrum of intestinal healing, composed of not only endoscopic healing, but also histologic, transmural, and fistula healing [12].



**Figure 1** Representative probe-based confocal laser endomicroscopy images of normal colonic mucosa, active mucosal inflammation, and dysplasia. (A) Normal colonic epithelium: Columnar lined round regular crypts, dark mucin within goblet cells, narrow vessels. (B) Active ulcerative colitis: Irregular colonic architecture, dilated prominent branching vessels with dilated, and distorted crypt lumens. (C) Colonic dysplasia: Distorted glandular architecture with unequal gland size and spacing, epithelial cells of different shape and sizes

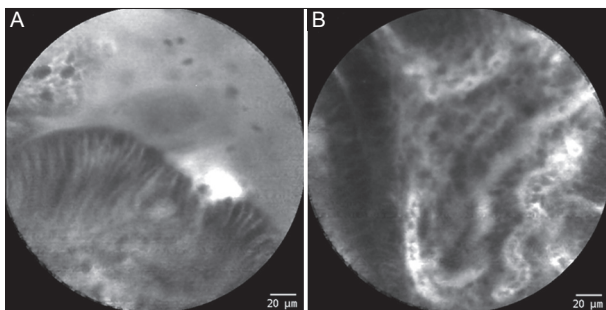
White light endoscopy can be an insensitive test for the assessment of mucosal healing or absence of mucosal ulcerations because of false negative in up to 50% of patients [13]. CLE allows for assessment of microscopic inflammation even in the case of macroscopic non-inflamed mucosa [7,13,14]. CLE has been proven to be efficient for real-time *in vivo* assessment of mucosal inflammation and requires only a short learning curve [15].

Neumann *et al* demonstrated the features of CLE on inflamed compared to non-inflamed mucosa, which had high agreement with standard histology [16]. It was shown that a significant higher proportion with active CD had increased colonic crypt tortuosity, enlarged crypt lumen, microerosions, and increased cellular infiltrates within the lamina propria. In a prospective clinical trial, Neumann *et al* validated the CD Endomicroscopic Activity Score based on six parameters to predict increased inflammatory activity: reduced crypt number; increased crypt distortion; microerosions; cellular infiltrate; increased vascularity; and decreased number of goblet cells [16].

Similarly, Watanabe *et al* has demonstrated that the colonic crypts of active ulcerative colitis showed large, irregular arrangement with numerous inflammatory cells and dilated capillaries were visible on the lamina propria, and fluorescein leakage [17] (Fig. 2). Li *et al* confirmed these early results in 73 consecutive UC patients [7]. Furthermore, the Li study showed that more than half of patients with reportedly normal mucosa on conventional white light revealed inflammation on CLE, confirmed by standard histology [7]. Therefore, CLE appears to be a more sensitive tool for real-time assessment of inflammatory activity which adds another dimension to the concept of mucosal healing in terms of deep remission beyond the absence of mucosal ulcerations.

### Assessment of cellular function and disease relapse

In the biologic era, mucosal healing has emerged as one of the most important predictor of disease relapse in both CD and UC [18,19]. Kiesslich *et al* first reported that the loss of intestinal cellular function in IBD patients can be identified using CLE in conjunction with intravenous administration of fluorescein [14]. Three important findings were identified:



**Figure 2** Probe-based confocal laser endomicroscopy images of active inflammation. (A) Moderate to severe colonic inflammation showing fluorescein leakage. (B) Moderate inflammation demonstrating dilated tortuous vessels

cell shedding; fluorescein effluxation through the epithelium; and microerosions as a local epithelial defect. Compromised epithelial barrier exposes the subepithelial immune system to microbes which induced secretion of pro-inflammatory cytokines, such as tumor necrosis factor (TNF)- $\alpha$  [20], which induces shedding of the epithelial cells from the intestines which further contributes to barrier dysfunction and promotes ongoing inflammation [21]. Other cytokines such as interleukin 6, 18, 1- $\beta$ , and TNF- $\alpha$  have been reported to be increased in active IBD and correlate consistently with endoscopic severity of inflammation [22,23].

Liu *et al* proposed a quantitative measure called epithelial gap density, defined as a total number of epithelial gaps counted on pCLE images, as a means to identify early mucosal barrier dysfunction and inflammation [24]. Increasing gap density and certain types of epithelial gaps were found to be predictive of aggressive disease and subsequent clinical relapses in IBD patients [14,25]. Kiesslich *et al* identified three important findings among IBD patients who were in clinical remission: active cell shedding; plumes of fluorescein effluxation through the epithelium; and development of microerosions as a local defect in IBD patients [14]. Combining these findings, a grading system was designed to summarize the severity of alteration of the mucosal barrier at confocal microscopy *in vivo*. Among IBD patients in clinical remission, increased cellular shedding with fluorescein leakage accurately predicted which patients developed subsequent clinical relapse within 12 months with sensitivity of 62.5%, specificity 91.2%, and accuracy 79%.

A major challenge in the management of IBD patients is that the clinical course of disease can be highly variable. There is little correlation between clinical activity, biological parameters, and endoscopic severity in IBD patients. CLE appears to be a useful tool in predicting early disease relapses in IBD patients, even prior to the presence of mucosal ulcerations on white light endoscopy and symptom relapses. CLE may have an important role in guiding practicing clinicians to step-up in medical therapy even before overt mucosal inflammation and clinical relapses are present. However, future studies will need to compare CLE to other currently available non-invasive modalities to assess mucosal inflammation such erythrocyte sedimentation rate, C-reactive protein, magnetic resonance enterography, and fecal calprotectin.

### Using CLE to individualize medical therapy for IBD patients

Emerging medical therapies in the management of IBD have branched out to targeting different inflammatory pathways and inflammatory cytokines. In a recent study Atreya *et al* created a fluorescent labeled antibody for molecular membrane-bound TNF (mTNF) imaging in CD patients. Topical antibody administration during colonoscopy examination followed by CLE led to detection of intestinal mTNF-positive immune cells. The group found that in patients with high amounts of mTNF-positive cells showed significantly higher short-term clinical response to anti-TNF therapy compared to patients with low amounts of mTNF cells (92% versus 15%). These results are extremely promising and offer an exciting potential to begin

more individualized therapy for patients using molecular imaging *in vivo* [26].

### Assessment of pouchitis

Total proctocolectomy with ileo-pouch anal anastomosis (IPAA) is a common procedure of choice for the management of patients with UC. Though good functional status and significant improvement in quality of life have been reported with IPAA, complications do develop. Pouchitis, a non-specific inflammation of the ileal reservoir, is the most frequent long-term complication after surgery [27,28]. Accurate diagnosis and classification of pouch disease is important for the appropriate management and surveillance of the pouch [29].

Trovato *et al* demonstrated in a case series of 18 patients that at standard endoscopy, the mucosal signs of pouchitis were only recorded in 7 of 18 patients (38.9%). However, using CLE, pathological features were found in 16/18 cases (88.9%) [30]. CLE detected villous atrophy, alteration of vessel loops, colonic metaplasia, capillary leakage, and presence of inflammatory cellular inflammation. The  $\kappa$ -value demonstrated a strong intraobserver agreement of 0.93. These findings suggest that we may be able to use CLE to predict IPAA patients who are at higher risk for development of pouchitis even prior to the onset of symptoms or gross mucosal changes.

### Assessment of dysplasia

#### Evaluation of colonic neoplasia

Patients with IBD are at an increased risk for the development intraepithelial neoplasia and colitis-associated cancer with risk being contingent on duration of IBD and extent of bowel disease. Currently, the standard recommendation is for patients to undergo colonoscopy annually with random four quadrant biopsies taken at every 10 cm of the colon. It has been demonstrated that 33 to 55 jumbo forceps biopsies are need to increase the detection of dysplasia or carcinoma with 90% confidence [31,32]. Despite this regimen, surveillance colonoscopy with white light endoscopy can miss flat multifocal lesions and has not been definitively shown to decrease colorectal cancer (CRC)-related mortality in IBD patients [12]. Therefore, a targeted biopsy approach may increase the diagnostic yield of intraepithelial neoplasia.

Chromoendoscopy using specialized dyes (methylene blue or indigo carmine) has been shown to enhance the detection of suspicious lesions in long-standing UC and CD by highlighting subtle mucosal changes [33,34]. Since CLE only covers a limited field of view, pan-CLE of the entire colonic mucosa may not be feasible. A prospective, randomized control trial evaluated the role of concurrent chromoendoscopy with CLE in 153 UC patients. It was demonstrated that using CLE in addition of chromoendoscopy improved the diagnostic yield of neoplasia by nearly 5-fold compared to conventional colonoscopy with random biopsies. Furthermore, nearly less than 50% of

pathologic specimens were required [35]. A recent meta-analysis of 15 studies using CLE for the detection of dysplasia showed that CLE could distinguish neoplasms from non-neoplasms in IBD patients undergoing routine surveillance with a sensitivity of 83% and specificity of 90% [36].

In the management of IBD, it is difficult to differentiate between sporadic adenoma and dysplasia-associated lesion or mass (DALM). Differentiation between these two distinct clinical entities is improvement in patient management (i.e. total proctocolectomy versus endoscopic resection). Hurlstone *et al* demonstrated a novel approach to using CLE for *in vivo* diagnosis and distinction between a sporadic adenoma and DALM. A total of 36 patients with 36 circumscribed lesions were enrolled. Using CLE, the *in vivo* diagnosis with sporadic adenoma and DALM showed a  $\kappa$  agreement between CLE and traditional histopathologic evaluation of 0.91 and an accuracy of 97% [37].

#### Evaluation of dysplasia in primary sclerosing cholangitis (PSC)

In particular, patients with concurrent diagnosis of PSC and IBD have a much higher risk of colitis-associated neoplasia, reflecting a different clinical phenotype and genotype. PSC-IBD is typically characterized by low inflammatory activity and right-sided colonic inflammation, but there is a high risk for CRC compared to patients with IBD alone [38]. Dlugosz *et al* demonstrated that pCLE was an important complementary tool to high definition white light endoscopy among PSC-IBD patients [39]. Initial results on 25 patients demonstrated a sensitivity of 93% and specificity of 100% of pCLE in detection of dysplasia in this high risk population, with 60% of the intraepithelial lesions being found in the right colon. This suggests that, at least among PSC-IBD patients, evaluation of at least the right colon with CLE may be indicated.

CLE has been also proposed as a diagnostic tool in biliary dysplasia in patients with PSC with dominant biliary strictures [40]. Standard biliary cytology from brushings of dominant strictures has a sensitivity of approximately 40% [41]. In a study of 21 dominant strictures, performing pCLE through the duodenoscope showed a sensitivity of 100% and specificity of 61% [40]. The negative predictive value was 100%, suggesting that pCLE may be used to exclude biliary neoplasia.

#### Future directions of endomicroscopy in IBD

The application of CLE currently is limited in general practice because of equipment and training limitations and need for extra time spent on routine endoscopic procedures (about 30 min). A recent report did demonstrate that among wide range of gastrointestinal specialists, the interpretation of neoplastic lesions can be learned rapidly [42]. Currently, CLE has not been applied to our current guidelines in the management of IBD patients and is only practiced at major, specialized academic centers.

There does appear to be important roles for the use of CLE in the detection of early inflammatory changes and dysplasia. It would be important to have multi-center studies evaluating if early detection of inflammation and early escalation of therapy, even prior to overt inflammation changes, will ultimately improve quality of life and alter the natural history of the disease. Emerging studies also suggest that endomicroscopy can be used to identify specific types of cytokines contributing to the patient's inflammatory cascade. This knowledge can allow clinicians to carefully select appropriate biologic therapies early in the disease course rather than an empiric initiation of anti-TNF and waiting for clinical failure.

### Concluding remarks

Endomicroscopy offers an important diagnostic advantage to the traditional white light endoscopy in the management of IBD patients. Table 1 summarizes current uses of endomicroscopy in the management of IBD patients. Endomicroscopy allows clinicians to detect early inflammatory changes allowing for early intervention and prevent subsequent clinical relapses. Furthermore, when combined with chromoendoscopy, endomicroscopy may improve the detection of colonic and biliary dysplasia. Future studies are warranted before the use of endomicroscopy can be fully incorporated into our guidelines in the routine management of IBD patients.

### References

- Choi KS, Jung HY. Confocal laser endomicroscopy and molecular imaging in Barrett esophagus and stomach. *Clin Endosc* 2014;**47**:23-30.
- Gupta A, Attar BM, Koduru P, Murali AR, Go BT, Agarwal R. Utility of confocal laser endomicroscopy in identifying high-grade dysplasia and adenocarcinoma in Barrett's esophagus: a systematic review and meta-analysis. *Eur J Gastroenterol Hepatol* 2014;**26**:369-377.
- Wallace MB, Fockens P. Probe-based confocal laser endomicroscopy. *Gastroenterology* 2009;**136**:1509-1513.
- Kiesslich R, Neurath MF. Endoscopic confocal imaging. *Clin Gastroenterol Hepatol* 2005;**3**:S58-60.
- Neumann H, Kiesslich R. Endomicroscopy and endocytoscopy in IBD. *Gastrointest Endosc Clin North Am* 2013;**23**:695-705.
- Hundorfean G, Chiriach MT, Mudter J, Neurath MF. Confocal laser endomicroscopy provides potential differentiation criteria between Crohn's disease and ulcerative colitis. *Inflamm Bowel Dis* 2013;**19**:E61-E64.
- Li CQ, Xie XJ, Yu T, et al. Classification of inflammation activity in ulcerative colitis by confocal laser endomicroscopy. *Am J Gastroenterol* 2010;**105**:1391-1396.
- Bouguen G, Levesque BG, Pola S, Evans E, Sandborn WJ. Endoscopic assessment and treating to target increase the likelihood of mucosal healing in patients with Crohn's disease. *Clin Gastroenterol Hepatol* 2014;**12**:978-985.
- Neurath MF, Travis SP. Mucosal healing in inflammatory bowel diseases: a systematic review. *Gut* 2012;**61**:1619-1635.
- Baert F, Moortgat L, Van Assche G, et al. Mucosal healing predicts sustained clinical remission in patients with early-stage Crohn's disease. *Gastroenterology* 2010;**138**:463-8; quiz e10-e11.
- Stidham RW, Higgins PD. Value of mucosal assessment and biomarkers in inflammatory bowel disease. *Exp Rev Gastroenterol Hepatol* 2010;**4**:285-291.
- Iacucci M, Panaccione R, Ghosh S. Advances in novel diagnostic endoscopic imaging techniques in inflammatory bowel disease. *Inflamm Bowel Dis* 2013;**19**:873-880.
- Liu J, Dlugosz A, Neumann H. Beyond white light endoscopy: the role of optical biopsy in inflammatory bowel disease. *World J Gastroenterol* 2013;**19**:7544-7551.
- Kiesslich R, Duckworth CA, Moussata D, et al. Local barrier dysfunction identified by confocal laser endomicroscopy predicts relapse in inflammatory bowel disease. *Gut* 2012;**61**:1146-1153.
- Neumann H, Vieth M, Atreya R, Neurath MF, Mudter J. Prospective evaluation of the learning curve of confocal laser endomicroscopy in patients with IBD. *Histol Histopathol* 2011;**26**:867-872.
- Neumann H, Vieth M, Atreya R, et al. Assessment of Crohn's disease activity by confocal laser endomicroscopy. *Inflamm Bowel Dis* 2012;**18**:2261-2269.
- Watanabe O, Ando T, Maeda O, et al. Confocal endomicroscopy in patients with ulcerative colitis. *J Gastroenterol Hepatol* 2008;**23** (Suppl 2):S286-S290.
- Colombel JF, Rutgeerts P, Reinisch W, et al. Early mucosal healing with infliximab is associated with improved long-term clinical outcomes in ulcerative colitis. *Gastroenterology* 2011;**141**:1194-1201.
- Vaughn BP, Shah S, Cheifetz AS. The role of mucosal healing in the treatment of patients with inflammatory bowel disease. *Curr Treat Options Gastroenterol* 2014;**12**:103-117.
- Neish AS. Microbes in gastrointestinal health and disease. *Gastroenterology* 2009;**136**:65-80.
- Watson AJ, Duckworth CA, Guan Y, Montrose MH. Mechanisms of epithelial cell shedding in the Mammalian intestine and maintenance of barrier function. *Ann N Y Acad Sci* 2009;**1165**:135-142.
- Monteleone G, Trapasso F, Parrello T, et al. Bioactive IL-18 expression is up-regulated in Crohn's disease. *J Immunol* 1999;**163**:143-147.
- Ishiguro Y. Mucosal proinflammatory cytokine production correlates with endoscopic activity of ulcerative colitis. *J Gastroenterol* 1999;**34**:66-74.
- Liu JJ, Madsen KL, Boulanger P, Dieleman LA, Meddings J, Fedorak RN. Mind the gaps: confocal endomicroscopy showed increased density of small bowel epithelial gaps in inflammatory bowel disease. *J Clin Gastroenterol* 2011;**45**:240-245.
- Turcotte JF, Wong K, Mah SJ, et al. Increased epithelial gaps in the small intestine are predictive of hospitalization and surgery in patients with inflammatory bowel disease. *Clin Transl Gastroenterol* 2012;**3**:e19.
- Atreya R, Neumann H, Neufert C, et al. *In vivo* imaging using fluorescent antibodies to tumor necrosis factor predicts therapeutic response in Crohn's disease. *Nat Med* 2014;**20**:313-318.
- Nessar G, Fazio VW, Tekkis P, et al. Long-term outcome and quality of life after continent ileostomy. *Dis Colon Rectum* 2006;**49**:336-344.
- Shen B. Pouchitis: what every gastroenterologist needs to know. *Clin Gastroenterol Hepatol* 2013;**11**:1538-1549.
- Pardi DS, Sandborn WJ. Systematic review: the management of pouchitis. *Aliment Pharmacol Ther* 2006;**23**:1087-1096.
- Trovato C, Sonzogni A, Fiori G, et al. Confocal laser endomicroscopy for the detection of mucosal changes in ileal pouch after restorative proctocolectomy. *Dig Liver Dis* 2009;**41**:578-585.
- Karlen P, Kornfeld D, Brostrom O, Lofberg R, Persson PG, Ekblom A. Is colonoscopic surveillance reducing colorectal cancer

- mortality in ulcerative colitis? A population based case control study. *Gut* 1998;**42**:711-714.
32. Rutter MD, Saunders BP, Wilkinson KH, et al. Thirty-year analysis of a colonoscopic surveillance program for neoplasia in ulcerative colitis. *Gastroenterology* 2006;**130**:1030-1038.
  33. Barkin JA, Sussman DA, Abreu MT. Chromoendoscopy and Advanced Imaging Technologies for Surveillance of Patients with IBD. *Gastroenterol Hepatol* 2012;**8**:796-802.
  34. Soetikno R, Subramanian V, Kaltenbach T, et al. The detection of nonpolypoid (flat and depressed) colorectal neoplasms in patients with inflammatory bowel disease. *Gastroenterology* 2013;**144**:1349-1352, 52 e1-6.
  35. Kiesslich R, Goetz M, Lammersdorf K, et al. Chromoscopy-guided endomicroscopy increases the diagnostic yield of intraepithelial neoplasia in ulcerative colitis. *Gastroenterology* 2007;**132**:874-882.
  36. Su P, Liu Y, Lin S, et al. Efficacy of confocal laser endomicroscopy for discriminating colorectal neoplasms from non-neoplasms: a systematic review and meta-analysis. *Colorectal Dis* 2013;**15**:e1-e12.
  37. Hurlstone DP, Thomson M, Brown S, Tiffin N, Cross SS, Hunter MD. Confocal endomicroscopy in ulcerative colitis: differentiating dysplasia-associated lesion mass and adenoma-like mass. *Clin Gastroenterol Hepatol* 2007;**5**:1235-1241.
  38. Jorgensen KK, Grzyb K, Lundin KE, et al. Inflammatory bowel disease in patients with primary sclerosing cholangitis: clinical characterization in liver transplanted and nontransplanted patients. *Inflamm Bowel Dis* 2012;**18**:536-545.
  39. Dlugosz A, Barakat A, Ost A, Bergquist A. Probe-based confocal laser endomicroscopy in colonoscopic surveillance of patients with PSC-IBD. *United European Gastroenterology J* 2013;**1**(Suppl 1):A473.
  40. Heif M, Yen RD, Shah RJ. ERCP with probe-based confocal laser endomicroscopy for the evaluation of dominant biliary stenoses in primary sclerosing cholangitis patients. *Dig Dis Sci* 2013;**58**:2068-2074.
  41. Trikudanathan G, Navaneethan U, Njei B, Vargo JJ, Parsi MA. Diagnostic yield of bile duct brushings for cholangiocarcinoma in primary sclerosing cholangitis: a systematic review and meta-analysis. *Gastrointest Endosc* 2014;**79**:783-789.
  42. Buchner AM, Gomez V, Heckman MG, et al. The learning curve of in vivo probe-based confocal laser endomicroscopy for prediction of colorectal neoplasia. *Gastrointest Endosc* 2011;**73**:556-560.