

## Case report

## Synchronous Adenocarcinomas of the small (Jejunum) and large (Transverse and Sigmoid Colon) bowel. A Case Study

V. Penopoulos<sup>1</sup>, N. Gougoulis<sup>1</sup>, J. Walonga<sup>1</sup>, G. Christianopoulos<sup>1</sup>,  
K. Pistevou-Gobaki<sup>3</sup>, G. Kokozidis<sup>2</sup>, G. Kitis<sup>2</sup>

### SUMMARY

A case of synchronous primary adenocarcinomas of the small and large bowel in a patient, thoroughly investigated for abdominal discomfort, is presented. Primary tumors of the small bowel are rare, and the diagnosis of primary adenocarcinoma of the small bowel in the presence of primary adenocarcinomas of the large bowel requires a high degree of suspicion and may well modify the prognostic outcome if detected early.

**Key Words:** synchronous, adenocarcinoma, large bowel, small bowel, diagnosis, treatment.

### INTRODUCTION

Primary adenocarcinomas of the small intestine are rare and malignant tumors of the small bowel account for less than 1% of the intestinal malignancies, despite the fact that the small bowel represents 75% of the length and over 90% of the mucosal surface of the intestinal tract<sup>1,2</sup>. Because of their rarity, non-specific symptoms and diagnostic difficulty, small bowel tumors are often diagnosed and treated late in their course. The diagnostic difficulty is increased when these tumors arise in association with primary synchronous tumors of the colon. The incidence of synchronous adenocarcinomas of the large

bowel ranges from 0.6% to 11% in the international literature.<sup>1</sup> Despite a thorough search we were unable to find a similar case, where the primary adenocarcinomas of the large bowel developed 'synchronously', with one primary small bowel adenocarcinoma and were all treated surgically on the same occasion.

### CASE REPORT

A 70 year old white male was admitted to the Gastroenterology clinic with a six-month history of asthenia, weight loss and changes in bowel habits. Prior to that, he had been meticulously investigated for various atypical abdominal complaints, but no pathology - abnormality - was detected. He was carrying with him a whole pile of repeatedly done investigations, such as blood tests, gastroscopies, small bowel enemas, large bowel enemas, colonoscopies, CT scans, MRI's etc. The patient mentioned that his last series of investigations had been done about ten months before but for the previous six months he had developed devastating anorexia, - lost 10 Kgrs - diarrhea and extreme weakness.

His past medical history was clear of any serious health problems and there was no significant family history. He was receiving no medication and was free of any allergies. He had stopped smoking twenty years previously and he drunk alcoholic beverages rarely.

Physical examination revealed a fully alert, well hydrated patient with a soft abdomen. No masses could be felt on palpation - despite his thin abdominal walls - his bowel sounds were normal and rectal examination was negative. His vital signs were within normal limits and laboratory findings including enteric peptides and cancer antigens - CA 19-9, CEA, CA 72-4, CA-50, - were unremarkable. His chest x-ray was normal, plain abdominal

<sup>1</sup>B' Surgical Department and <sup>2</sup>Gastroenterology Department, "G. Papanikolaou" Regional General Hospital, Exohi, 57010 Thessaloniki, Greece, <sup>3</sup>Department of Radiation Oncology, Aristoteles University of Thessaloniki, AHEPA Hospital, 54636 Thessaloniki, Greece

#### Author for correspondence:

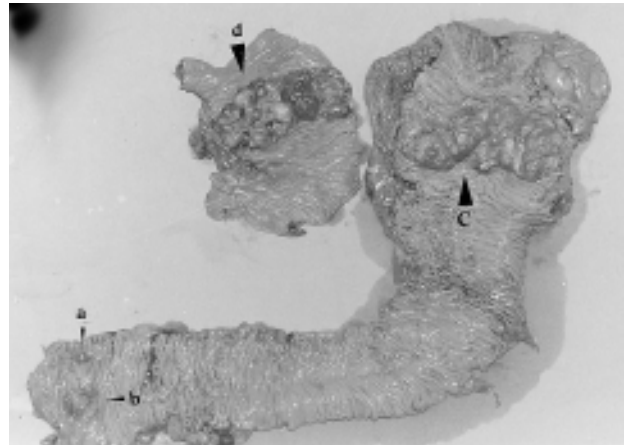
V. Penopoulos, 4 Panormou str., Kalamaria, 551 33 Thessaloniki, Greece, Tel.: 2310-440883, e-mail: baspen@otenet.gr

films were free of any pathology and ECG was normal.

Due to the peculiar sequence of the referring symptoms he was investigated initially with an upper abdominal U/S which revealed no serious abnormalities apart from bilaterally situated simple renal cysts and a calcified lesion in the right lobe of the liver, suggestive of an old calcified hydatid cyst. Following that, an endoscopy was carried out which showed a normal esophagus, an intense patchy gastritis with red, edematous pylorus and positive CLO test and a rather mild duodenitis. No sign of neoplastic growth was seen. A full length colonoscopy was performed which showed: 1) A small pedunculated polyp at 20 cm together with a located nearby ulcerative lesion suggestive of a cancerous growth, 2) further up, at 65 cm, a cauliflower malignant tumor partially obstructing the lumen of the large bowel was detected. The rest of the colon was clear of any pathology. Multiple biopsies were taken but since the diagnosis was rather obvious the patient was taken to the theatre for surgery.

Surprisingly, at laparotomy, apart from the previously mentioned growths in the large bowel, another one partially obstructing the jejunum - 40 cm from the ligament of Treitz - was discovered. At that time the decision was taken to excise all tumors as radically as possible. Initially an extended left hemicolectomy with lymphadenectomy and omentectomy was carried out with an end-to-side anastomosis using EEA - 33 mm and TA - 60 for the colonic stump. In total 55 cm of left colon were resected. The cancerous lesions and the benign polyp are clearly seen in Figure 1. Following that, a generous enterectomy with lymphadenectomy was carried out with a side-to-side anastomosis using GIA - 33 and TA 60 for the enteric stump. In total 40 cm of jejunum were resected (Figure 1).

Histological examination of the excised lesions revealed: 1) The pedunculated polyp to be a tubular - villous adenoma with moderate degree of dysplasia but nothing sinister in the examined sections (Figure 1a). 2) The nearby ulcerated lesion was a poorly differentiated primary adenocarcinoma of the sigmoid colon - glandular in type - partially infiltrating the colonic wall (Figure 1b). 3) The cauliflower ulcerated lesion of the transverse colon (Figure 1c), proved to be a full thickness moderately differentiated primary adenocarcinoma which was extending into the surrounding mesocolic adipose tissue. The extended left hemicolectomy specimen included in total 21 regional lymph nodes, 3 of which were found to be totally occupied by metastatic adenocarcinoma. The surgical excisional margins were free of cancer (Figure 1). 4) The jejunal cauliflower ulcerated lesion proved to



**Figure 1.** Panoramic view of excised large and small bowels. For artistic purposes only part of the excised small bowel is seen here. The synchronous adenocarcinomas of the large (b, c) and small (d) bowel are clearly seen.

be a primary, poorly differentiated adenocarcinoma mucinous in type, with areas of necrosis. Mucinous lakes were found to be more than 50%. Histologically this tumor was clearly different from those seen in the large bowel, showing abundant mucin production with formation of mucinous lakes. It was diffusely infiltrating - full thickness - the jejunal wall with focal expansion into the surrounding mesenteric adipose tissue. Two out of the 19 regional lymph nodes examined were found to be totally occupied by metastatic adenocarcinoma. The surgical excisional margins were free of cancer (Figure 1).

The patient had an uneventful recovery from the operation and was discharged home on the 10<sup>th</sup> postoperative day with the provision to receive six courses of standard chemotherapy in the near future. He was recently seen in our outpatient clinic 8 months after surgery and 2<sup>1/2</sup> months following the completion of his chemotherapy courses, with no clinical or radiological findings - CT scan included - suggestive of local recurrence or distal spread of his disease. Recent repeat full length colonoscopy and enteroscopy up to 40 cm beyond the anastomosis were also negative for local recurrences of the disease.

## DISCUSSION

An unusual case of synchronous small and large bowel adenocarcinomas in a neurotic patient, is presented. The rarity of the small bowel tumors and their non-specific symptomatology render their preoperative diagnosis difficult. The liquid contents of the small bowel, low bacterial counts, short transit time, alkaline Ph and high con-

centration of immunoglobulin IgA are some of the factors which might account for the low incidence of small bowel tumors.<sup>2</sup>

The role of 'apoptosis' (programmed cellular death) is becoming increasingly recognisable as regards its contribution to the carcinogenesis process. Apoptosis plays a major role against the possible development – creation of a tumor, because of the cellular 'drop'. It is quite interesting to note that proto-oncogene Bcl-2 (anti – apoptosis action) is not expressed in the small bowel's epithelium, while the Bax gene, which stimulates the apoptosis is present. Additionally, it should be stressed that the apoptosis zone in the small bowel was found to coincide with the level of reproduction zone in the lower third of the enteric crypt, in comparison with the large bowel where it was found to be situated at a higher level of the crypt. It is therefore suggested that the above mentioned genetic differences 'protect' the small bowel from cancerous growth, despite the rapid cellular proliferation seen in its epithelium<sup>4</sup>. They are also difficult to diagnose radiologically and are often missed.<sup>3</sup>

The distribution of primary adenocarcinomas within the small intestine varies in different studies, primarily depending on inclusion or exclusion of carcinoma of the ampulla of Vater. Bridge and Perzin<sup>5</sup> in their study of 43 cases of primary adenocarcinoma of the small intestine excluding duodenal carcinomas, described 32 cases involving the jejunum and 11 cases involving the ileum. Most other studies show that the distribution of these tumors is highest proximally with decreasing frequency in the more distal segments of the small bowel. Results of 1050 case reports collected by Reiner in 1976 show the same kind of decreasing aboral gradient: 40% duodenal, 38% jejunal, 22% ileal.<sup>6</sup>

Adenocarcinoma is the most common type of small bowel cancer, constituting 32%-54% of all malignant enteric tumors or 41%-70% if carcinoids are excluded.<sup>7</sup>

Multiple primary malignancies were found in 20%-25% of enteric cancers.<sup>6</sup> Ouiriel and Adams<sup>8</sup> reviewed a series of 65 patients with adenocarcinoma of the small intestine and found that associated malignancies were present in 16 patients (25%), the malignancy being colonic adenocarcinoma in 12 patients. There is a high frequency of secondary synchronous and metachronous neoplasms associated with small intestinal carcinoma.<sup>9</sup> However they are often misdiagnosed as metastatic or recurrent colonic carcinomas when present in association with a colorectal carcinoma.

Another possible causal factor of synchronous small

and large bowel carcinomas, is thought to be therapeutic irradiation, subsequent to bowel malignancy.<sup>10</sup>

## CONCLUSIONS

We decided to report our case since we were unable to locate a similar case of three synchronous primary adenocarcinomas - two in the large bowel (Sigmoid and Transverse colon) and one in the jejunum, with different histological characteristics, and finally not associated with any of the etiopathogenic factors described before. The incidence of synchronous colonic carcinomas is increasing as well as the coexistence of small bowel adenocarcinomas with other malignancies. Reddy et al,<sup>11</sup> described a case of synchronous appearance of adenocarcinomas of jejunum and cecum, in a patient previously treated with transverse colectomy for cancerous polyps. Iamurov et al,<sup>12</sup> reported the coincidence of a large bowel tumor with a leiomyoblastoma of the small intestine.

The surgeon should always be alert for the possibility of multiple malignancies in the abdomen during laparotomies. Radical resection and lymphadenectomy is the only way to prolong the patient's life. In this case we added adjuvant chemotherapy in the hope of improving prognosis and survival.

The absolutely wrong non-scientific impression of giving up further examination of the large bowel after one neoplasm has been detected should be abandoned. When two synchronous carcinomas in the large bowel are detected we suggest that the small bowel should also be investigated with enteroscopy. The prognosis of synchronous primary adenocarcinomas of the large and small bowel correlates better with the depth of invasion, tumor size and lymph node metastasis. It should be stressed that primary synchronous adenocarcinomas - two in the large bowel and one in the small bowel - are not previously reported and that radical colectomy plus radical enterectomy and lymphadenectomy in combination with chemotherapy are the only tools in surgeon's hands to deal with the problem. The future course of this case deserves careful study.

## REFERENCES

1. Langevin JM, Nivatongs S. The true incidence of synchronous cancer of the large bowel. A prospective study. *Am J Surg* 1984; 330:147-151.
2. Lowelfels AB. Why are small bowel tumors so rare? *Lancet* 1973; 1:24-29.
3. Williamson RCN, Welch CE, Malt RA. Adenocarcino-

- ma and lymphoma of the small intestine. Distribution and etiologic associations. *Ann Surg* 1983; 197:172-178.
4. Potten CS, li YQ, O'Connor PJ, et al. A possible explanation for the differential cancer incidence in the intestine, based on distribution of the cytotoxic effects of carcinogens in the murine large bowel. *Carcinogenesis* 1992; 13:2305-2312.
  5. Bridge MF and Perzin KH. Primary adenocarcinoma of the jejunum and ileum. *Cancer* 1975; 36:1876-1887.
  6. Reiner MA. Primary malignant neoplasms of the small bowel. *Mt Sinai J Med* 1976; 43:274-280.
  7. Treadwell TA, White RR. Primary tumors of the small bowel. *Am J Surg* 1975; 130:749-755.
  8. Ouriel K, Adams JT. Adenocarcinoma of the small intestine. *Am J Surg* 1984; 147:66-71.
  9. Alexander JW, Altmeier WA. Association of primary neoplasms of the small intestine with other neoplastic growths. *Ann Surg* 1986; 167:938-964.
  10. Gajraj H, Davies DR, Jackson BT. Synchronous small and large bowel cancer developing after pelvic irradiation. *Gut* 1988; 29:126-128.
  11. Reddy VB, Husain AN, Gattuso P, Abraham K, Castelli MJ. Synchronous adenocarcinomas of jejunum and cecum following transverse colon carcinoma. A case study. *Mt Sinai Med* 1990; 57:34-36.
  12. Iamurov N, Petkov K, Penchev P, Vasiliev N, Ivanov A. [A case of a synchronous tumor of the large intestine combined with a leiomyoblastoma of the small intestine with a course of subileus]. *Khirurgiia (Sofia)* 1997; 50:49-51.