

*Special topic by C. Dervenis*

## Can we predict resectability in pancreatic cancer?

J.H. Balcom, C. Fernandez-del Castillo

### INTRODUCTION

Ductal adenocarcinoma of the pancreas is the fourth leading cause of cancer-related death in the United States.<sup>1</sup> It is a devastating disease which remains difficult to detect and treat.<sup>2</sup> The importance of continued improvement in diagnostic speed and accuracy, staging of the disease, and treatment can not be overstated as pancreatic carcinoma remains a major cause of cancer mortality despite decreasing in incidence in the past 25 years.<sup>1,3</sup>

Preoperative staging provides information concerning prognosis and can also help in identifying patients who are likely to be resectable and those who will benefit from chemotherapy and radiation.<sup>4</sup> The increasing availability of a wide variety of radiographic and laparoscopic techniques to practicing surgeons and gastroenterologists requires a rational approach to staging which much be individually applied to each patient.<sup>5</sup>

### *Resectability and Staging*

Historically, most patients who were suspected of having pancreatic cancer underwent exploratory laparotomy. At the time of the operation, the surgeon examined the abdomen for evidence of metastases and, if none were present, made a decision regarding the resectability of the primary tumor. If the tumor was found to be unresectable, surgical palliation would be performed. Proponents of this strategy claimed that with this approach no patient was denied a chance for curative resection. What, then, is the purpose and advantage of pre-

operative staging? The most compelling reason from the standpoint of surgical treatment is that the likelihood of an attempt at curative resection is elevated from about 25% to over 75% when thorough preoperative staging studies are performed.<sup>6-8</sup> Thus, patients in whom an operation will not provide a survival advantage are spared the morbidity of exploratory laparotomy.<sup>4</sup> Patients who are candidates for curative resection benefit from staging efforts, in that they may be referred to specialized centers where the morbidity and mortality of pancreatic resection are low.<sup>9</sup> In identifying patients with locally unresectable or metastatic disease, preoperative staging designates these patients for less invasive palliative procedures such as endoscopic or percutaneous biliary stenting.<sup>10</sup> These patients are also spared a purely diagnostic laparotomy since the techniques of percutaneous and endoscopic fine needle aspiration (FNA) have become safer and more widely utilized.<sup>11</sup> Lastly, patients who are candidates for intensive adjuvant and neoadjuvant treatment with chemotherapy and radiation require extensive preoperative assessment in the form of radiographic and laparoscopic staging.<sup>4,10</sup>

### *Clinical Contributions to Staging*

Most patients who are diagnosed with pancreatic carcinoma are symptomatic. Usually, some combination of jaundice, pain, weight loss, anorexia, and nausea with or without vomiting prompt the patient to seek medical attention. Our experience shows that jaundice and/or pain are present in more than 90% of patients at presentation.<sup>12</sup> Some studies have shown that certain symptoms and signs are more indicative of early disease.<sup>13-15</sup> Perhaps the most significant of these is jaundice. Kalser et al found that jaundiced patients were nine times more likely to have resectable lesions than non-jaundiced patients diagnosed with pancreatic carcinoma, and Moosa et al stated that, in their experience, 45% of jaundiced patients were resectable vs. 10% of non-jaundiced patients.<sup>5,13</sup> This phenomenon can be explained by the fact

*Department of Surgery, Massachusetts General Hospital and Harvard Medical School, Boston, MA 02114*

*Author for correspondence:*

Carlos Fernandez-del Castillo, Mass. General Hospital – WACC  
336, Fruit Street, Boston, MA 02114, Tel.: (617)7265644, Fax:  
(617)7243383, e-mail: [cfernandez@partners.org](mailto:cfernandez@partners.org)

that most patients presenting with jaundice have lesions located in the head of the pancreas. Because of their proximity to the bile duct and ampulla, these lesions may become symptomatic earlier in the course of illness relative to lesions in the body and tail of the gland. Jaundice in patients with carcinoma of the left pancreas is always a late sign, usually associated with liver metastases. Thus, jaundice should always be treated as a “potentially early” sign of carcinoma in the head of the pancreas.<sup>5</sup>

Pain is present in about 80% of patients with pancreatic carcinoma and can have several contributing etiologies.<sup>10</sup> Perineural spread or invasion by tumor, capsular stretching, and pancreatic ductal obstruction have all been proposed as mechanisms.<sup>5</sup> Some have suggested that pain may be a late symptom, and there is evidence that the presence of pain denotes advanced carcinomas that may be associated with decreased survival.<sup>16</sup> Back pain in particular may be associated with decreased survival as it can frequently represent tumors of the pancreatic body and tail.<sup>1,14</sup>

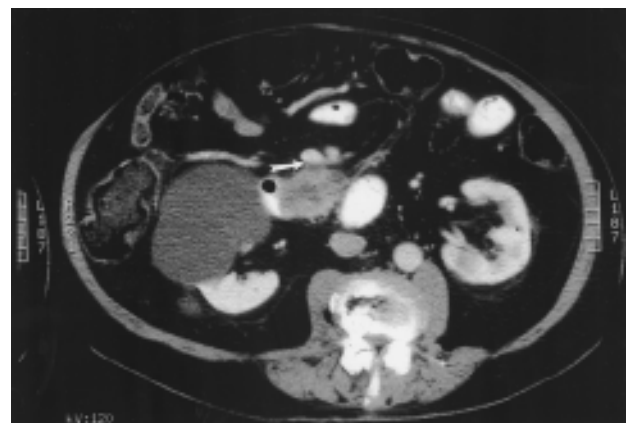
Early pancreatic cancer is notoriously difficult if not impossible to detect on physical examination; however, it should be noted that there are several signs which are consistent with locally advanced (unresectable) or metastatic disease. Objective weight loss may correlate with higher stage disease.<sup>15</sup> The presence of a palpable abdominal mass is associated with advanced stage carcinoma, as is the presence of ascites.<sup>4</sup> Remote lymphadenopathy such as “Virchow’s node” (left supraclavicular node) or migrating thrombophlebitis (“Trousseau’s sign”) are signs of late, advanced carcinoma.<sup>5</sup>

### Computed Tomography

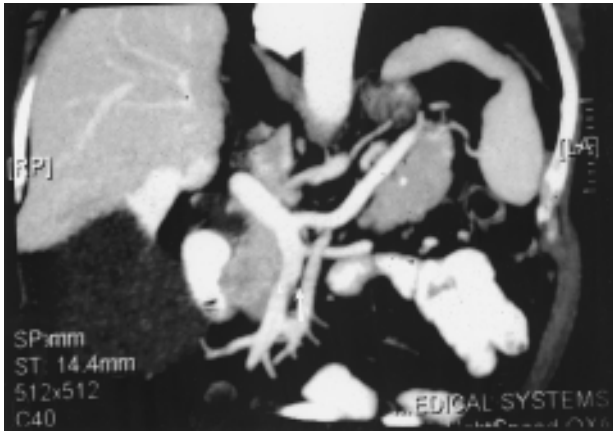
Computed tomography (CT) is currently the most important single test for the staging of pancreatic carcinoma.<sup>1,4,10,17-20</sup> Conventional CT scan with intravenous (IV) contrast enhancement can provide detailed images of the pancreas and surrounding tissues and can yield information concerning tumor size and location, extension to surrounding viscera, invasion of visceral arteries or the portal venous system, and the presence of hepatic or large regional lymph node metastases.<sup>4,21</sup> Certainly, metastatic disease to the liver or other distant organs is a sign of unresectability. Other criteria of unresectability are somewhat institutionally dependent; for instance, not all centers consider some degree of portal or superior mesenteric vein involvement to be an absolute contraindication for surgery.<sup>2,22</sup> Studies of the efficacy of imaging modalities in staging, however, consider most forms of vascular involvement to be indicative of unresectability.

Conventional CT seems to have a positive predictive value of between 60 and 80% in determining resectability.<sup>23,24</sup> In their review of several studies of CT and staging, Andersen et al found an average negative predictive value of 94% when examining resectability (i.e., conventional CT was very good at demonstrating signs of unresectability – invasion of vasculature or other local invasion; it was not as good at demonstrating a definite absence of those findings – resectability).<sup>24</sup>

The advent of dual phase helical CT has improved the accuracy of preoperative staging pancreatic carcinoma. This technique generates images after an IV bolus of contrast material during the phase of arterial perfusion of the pancreas, and again (after about 20 seconds) during the phase of portal venous system enhancement.<sup>17</sup> Additionally, the rapid acquisition of data with the helical technique decreases patient motion artifact and provides data for the construction of three-dimensional images.<sup>21</sup> These images better define the relationship of the tumor to the surrounding vasculature and peripancreatic tissues and provide a detailed “roadmap” of the arterial anatomy in the upper abdomen (Figures 1 and 2). Several studies give excellent evidence for the superiority of dual phase helical CT. Freeny et al reported a positive predictive value of 72% for resectability in a series of 213 patients. They gave a positive predictive value of 100% for unresectability,<sup>18</sup> although the true positive predictive value for CT unresectability in this study may be 89% since 6 patients with CT unresectable tumors underwent palliative resections. Bluemke et al found a positive predictive value of 88% for CT resectable tu-



**Figure 1.** Axial computed tomography (CT) of an adenocarcinoma of the uncinate process of the pancreas. The tumor contains typical areas of hypodensity. It abuts the superior mesenteric vein with loss of the fat plane next to the vessel and partially deforms its posterior contour (white arrow).



**Figure 2.** Computer-generated coronal reconstruction of the CT images obtained in Figure 1. There is slight indentation of the right side of the superior mesenteric vein by tumor (white arrowhead). The adjacent superior mesenteric artery appears to be surrounded by normal-density fat (white arrow).

mors.<sup>20</sup> Recently, Lu et al developed a grading system for vessel involvement using dual phase helical CT.<sup>17</sup> They used 50% circumferential tumor encasement of any vessel (celiac axis, hepatic artery, superior mesenteric artery, portal vein or superior mesenteric vein) as CT evidence of unresectability and found a positive value of 95% and a negative predictive value of 93%.<sup>17</sup>

The studies described above clearly demonstrate the importance of CT in the staging of pancreatic carcinoma. It is noteworthy that in nearly all the reports of CT efficacy, the positive predictive value for unresectability exceeds that of resectability. In other words, the presence of findings such as extensive local invasion or vessel invasion are more reliable than the absence of such findings.<sup>4,8</sup> We use dual phase helical CT as the initial imaging technique in the staging of pancreatic carcinoma. CT gives information about the resectability of the primary tumor, may show hepatic metastases, and provides detailed images of arterial and portal venous anatomy. Although CT is an excellent initial staging modality, other studies should usually be considered. Specifically, it should be noted that CT scan fails to identify small liver metastases and peritoneal tumor implants which can only be detected laparoscopically through visual inspection or peritoneal washings.<sup>25,25</sup>

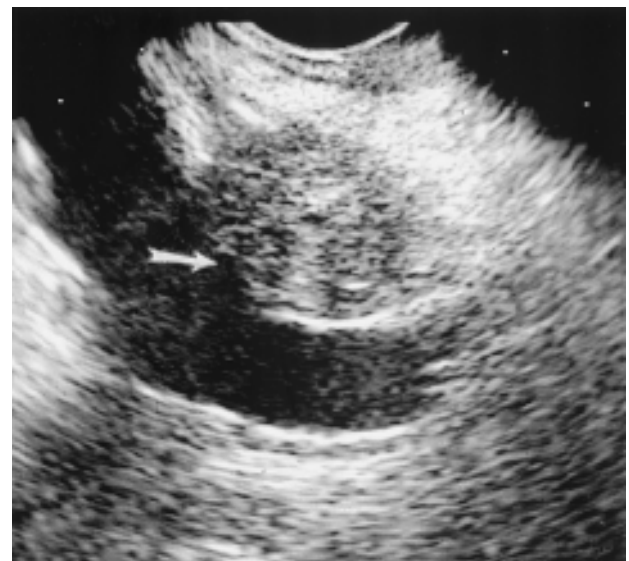
### **Endoscopic Ultrasound**

In the past few years, endoscopic ultrasound (EUS) has emerged as an extremely powerful and versatile pancreatic imaging modality.<sup>23,27</sup> Certainly one of the greatest strengths of EUS is its ability to identify small pan-

creatic tumors (less than 2cm). In a series by Yasuda et al, EUS correctly identified a pancreatic mass less than 2cm in 100% of patients compared with 57% by ERCP, 29% with conventional CT, and 29% with abdominal ultrasound (US).<sup>28</sup> Rosch et al found similarly superior results for EUS in the detection of small pancreatic tumors.<sup>29</sup>

EUS is also an excellent modality for staging, and may be as useful as late-generation CT in experienced hands.<sup>27</sup> In separate series, Rosch and Tio found that the tumor (T) and lymph node (N) staging of pancreatic carcinoma can be predicted with excellent accuracy using EUS.<sup>30,31</sup> EUS is perhaps best at identifying peripancreatic vessel invasion, specifically of the portal vein (Figure 3).<sup>32,33</sup> Rosch et al found that the accuracy of assessing portal vein invasion by EUS was 95%, considerably greater than the ability of conventional CT, US, and angiography.<sup>30</sup> The other advantage of EUS is that suspected carcinomas may be biopsied with a fine needle introduced through the endoscope. The needle tract is short and, in the case of pancreatic head masses, involves only tissues that would be resected via a classic Whipple operation.<sup>27</sup> Regional lymph nodes suspected of malignant involvement may also be biopsied via EUS.<sup>34</sup>

The limitations of EUS in local staging center around the fact that its ability to interpret blood vessel invasion or encasement other than the portal vein is somewhat restricted. Specifically, EUS may not be as accurate in



**Figure 3.** Endoscopic ultrasound (EUS) of large mass in the head of the pancreas. The tumor clearly extends through the border of the portal vein (white arrow).

viewing superior mesenteric vein involvement.<sup>32</sup>

### **Laparoscopy**

In the last 10 to 15 years, diagnostic laparoscopy has emerged as an integral part of the staging of pancreatic cancer. As discussed previously, the biggest problem with the existing radiographic staging techniques (i.e. dual phase helical CT) is their inability to detect small peritoneal tumor implants and liver metastases. This problem is well recognized; studies report the presence of metastases in 10 to 40% of patients who underwent exploratory laparotomy.<sup>18,35,36</sup> In a recent study at the Massachusetts General Hospital, Jimenez et al showed that 31% of patients (n=39 of 125 total patients) with radiographic stage II and III disease who underwent staging laparoscopy had unsuspected metastases. Almost one-fourth of those patients had micrometastases detected only by peritoneal washings performed during the procedure.<sup>25</sup>

Diagnostic laparoscopy may be indicated for any patient strongly suspected of having pancreatic adenocarcinoma and for whom preoperative radiographic studies show: 1) tumor larger than 2cm (we have found that tumors <2cm have a very low incidence of occult metastases<sup>25</sup>) and 2) no prior evidence of metastatic disease.<sup>25,36,37</sup> It is also indicated to establish the absence of metastatic disease in patients who may be enrolled in aggressive preoperative chemotherapy and radiation treatment protocols.<sup>25,36</sup> We perform laparoscopy as a separate procedure under general anesthesia in order to efficiently plan each patient's treatment and to ensure sufficient time for the processing of cytology specimens. A 10mm trocar is introduced through or below the umbilicus after the establishment of pneumoperitoneum, and the scope is introduced through this port. The peritoneal surfaces are carefully examined, including the undersurface of the liver; this is facilitated through the use of a rod introduced through a second trocar site in the right upper quadrant. Peritoneal washings are then performed prior to any biopsies. We feel that washings are critically important to the procedure as one-fourth of patients will have evidence of occult metastases (free-floating tumor cells) by lavage only.<sup>25,38</sup> Lastly, suspicious nodules are biopsied with forceps or, in the liver, with a

Tru-Cut needle (Travenol Laboratories, Deerfield, IL). The procedure takes 20 to 30 minutes and is performed on an outpatient or 23 hour observation basis.<sup>25</sup>

Contraindications for diagnostic laparoscopy include clear radiographic evidence of distant metastases and duodenal obstruction.<sup>36</sup> Patients with duodenal obstruction and patients in whom surgical palliation is required need not have diagnostic laparoscopy, since gastroenterostomy should be performed. Relative contraindications include extensive upper abdominal adhesions and large hiatal hernias.<sup>36</sup>

### **Intraoperative Staging**

The surgeon ultimately makes the final decision regarding the resectability of a pancreatic carcinoma in the operating room. At laparotomy, all peritoneal surfaces are closely inspected and suspicious nodules are sent for frozen section. If there is no evidence of metastatic disease, the surgeon proceeds with removal of the gallbladder and division of the common bile duct. A wide Kocher maneuver is performed, and the gastroduodenal artery can be ligated to gain access to the superior mesenteric vein/portal vein junction. If there is no invasion of the portal venous system and the pancreatic neck can be separated from the vasculature, the operation proceeds with excision of the specimen. Depending on the surgeon's experience, limited portal vein resection may be considered if tumor involvement is minimal and reconstruction can be performed.<sup>22,39</sup> Because a negative biopsy will not rule out cancer, routine intraoperative biopsy or needle aspiration of the mass is not appropriate unless it is determined to be unresectable, in which case a confirming tissue diagnosis should be obtained.<sup>5</sup>

### **Approach to Preoperative Staging**

An algorithmic outline to the preoperative staging of pancreatic carcinoma at the Massachusetts General Hospital is presented in Figure 4. We emphasize the importance of individualizing the approach to each patient, the use of dual phase helical CT as an initial imaging modality, and the use of diagnostic laparoscopy in all patients considered for resection or aggressive chemotherapy and radiation.

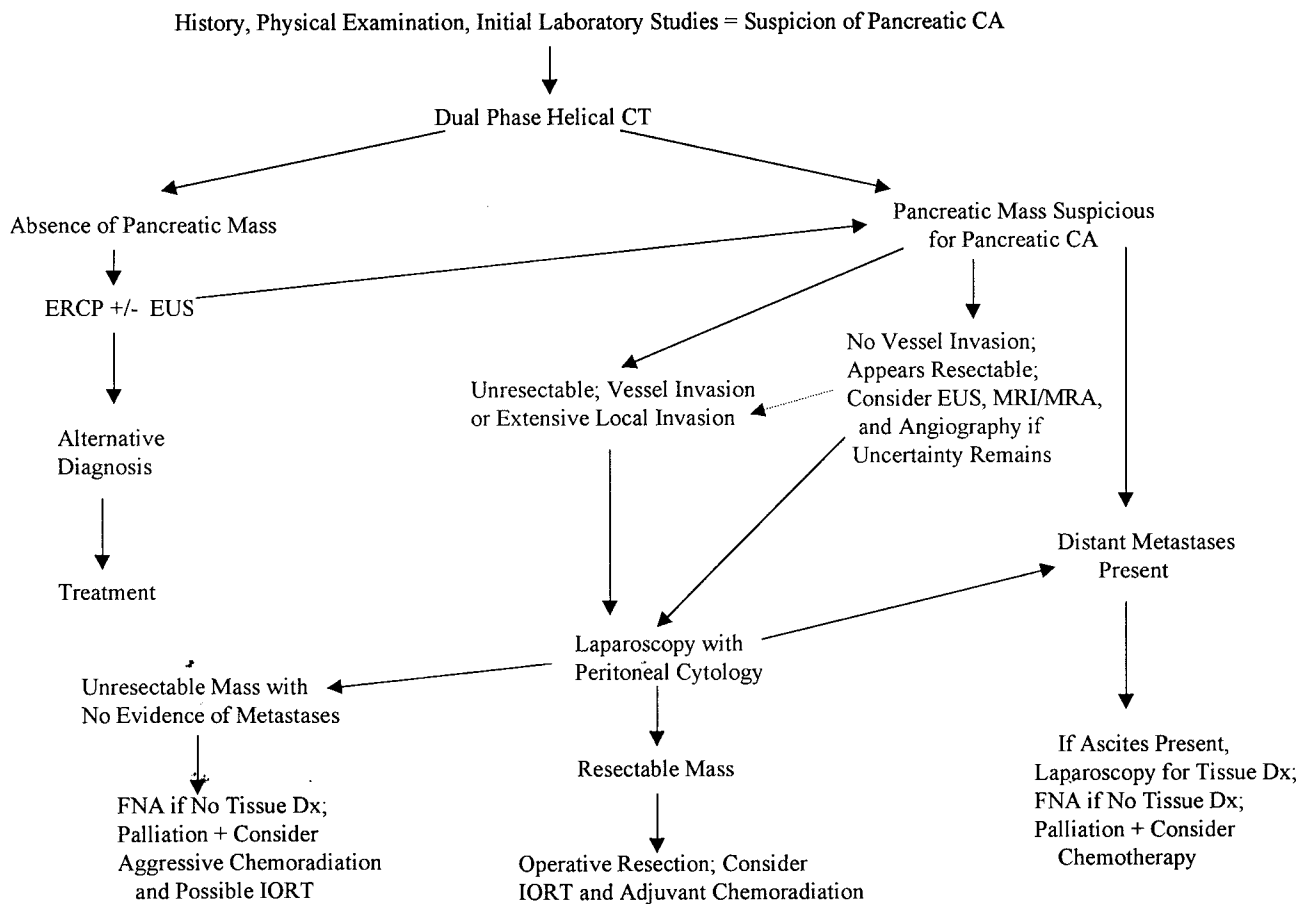


Figure 4.

## REFERENCES

- Barkin J, Goldstein J. Diagnostic approach to pancreatic cancer. In: Barkin J, Lankisch PG, editors. *Pancreas Update: Gastroenterology Clinics of North America*. Philadelphia: W.B. Saunders Company, 1999:709-722.
- Warshaw AL, Fernandez-del Castillo C. Pancreatic carcinoma. *N Engl J Med* 1992; 326:455-465.
- Pancreas Cancer (Invasive): Trends in SEER incidence and U.S. mortality using the joinpoint regression program, 1973-1997 (Table XXI-1). 1997; Washington, D.C.: National Cancer Institute. *SEER Cancer Statistics Review 1973-1997*.
- Rivera JA, Fernandez-del Castillo C, Warshaw AL. The preoperative staging of pancreatic adenocarcinoma. In: Cameron JL, editor. *Advances in Surgery*. Boston: Mosby-Year Book, Inc., 1996:97-122.
- Moosa AR, Gamagami RA. Diagnosis and staging of pancreatic neoplasms. In: Cameron JL, editor. *Pancreatic neoplasms: Surgical clinics of North America*. Philadelphia: W.B. Saunders Company, 1995:871-890.
- Connolly MM, Dawson PJ, Michelassi F, Moosa AR, Lowenstein F. Survival in 1001 patients with carcinoma of the pancreas. *Annals of Surgery* 1987; 206:366-373.
- Rosenberg JM, Welch JP, Macaulay WP. Cancer of the head of the pancreas: An institutional review with emphasis on surgical therapy. *J Surg Oncol* 1985; 28:217-221.
- Warshaw AL, Gu Z, Wittenberg J, Waltman AC. Preoperative staging and assessment of resectability of pancreatic cancer. *Arch Surg* 1990; 125:230-233.
- Fernandez-del Castillo C, Rattner DW, Warshaw AL. Standards for pancreatic resection in the 1990s. *Archives of Surgery* 1995; 130:295-300.
- DiMagno EP, Reber HA, Tempero MA. AGA technical review on the epidemiology, diagnosis, and treatment of pancreatic ductal adenocarcinoma. *Gastroenterology* 1999; 117:1464-1484.
- Al-Kaisi N, Siegler EE. Fine needle aspiration cytology of the pancreas. *Acta Cytologica* 1989; 33:145-152.
- Fernandez-del Castillo C, Warshaw AL. Preoperative evaluation of adenocarcinoma of the pancreas: Massachusetts General Hospital Experience. *The Cancer Bulletin* 1994; 46:492-498.
- Kalser MH, Barkin J, MacIntyre JM. Pancreatic cancer. Assessment of prognosis by clinical presentation. *Cancer* 1985; 56:397-402.
- Mannell A, van Heerden JA, Weiland LH, Ilstrup DM.

- Factors influencing survival after resection for ductal adenocarcinoma of the pancreas. *Annals of Surgery* 1986; 203:403-407.
15. Bakkevoid KE, Arnesjo B, Kambestad B. Carcinoma of the pancreas and papilla of vater: presenting symptoms, signs, and diagnosis related to stage and tumor site. A prospective multicentre trial in 472 patients. Norwegian pancreatic cancer trial. *Scand J Gastroenterology* 1992; 27:317-325.
  16. Kelsen DP, Portenoy R, Thaler H, Tao Y, Brennan MF. Pain as a predictor of outcome in patients with operable pancreatic carcinoma. *Surgery* 1997; 122:53-59.
  17. Lu DS, Reber HA, Krasny RM, Kadell BM, Sayre J. Local staging of pancreatic cancer: Criteria for unresectability of major vessels as revealed by pancreatic-phase, thin-sectioned helical CT. *AJR* 1997; 168:1439-1443.
  18. Freeny PC, Traverso LW, Ryan JA. Diagnosis and staging of pancreatic adenocarcinoma with dynamic computed tomography. *Am J Surg* 1993; 165:600-606.
  19. Fuhrman GM, Charnsangavej C, Abbruzzese JL, Cleary KR, Marin RG, Fenoglio CJ, et al. Thin-section contrast-enhanced computed tomography accurately predicts the resectability of malignant pancreatic neoplasms. *Am J Surg* 1994; 167:104-113.
  20. Bluemke DA, Cameron JL, Gruban RH, Pitt HA, Siegelman SS, Soyer P, et al. Potentially resectable pancreatic adenocarcinoma: Spiral CT assessment with surgical and pathologic correlation. *Radiology* 1995; 197:381-385.
  21. Freeny PC. Computed tomography in the diagnosis and staging of cholangiocarcinoma and pancreatic carcinoma. *Annals of Oncology* 1999; 10:12-17.
  22. Fortner JG. Regional pancreatectomy for cancer of the pancreas, ampulla, and other related sites. Tumor staging and results. *Annals of Surgery* 1984; 199:418-425.
  23. Rosch T, Lorenz R, Braig C, Classen M. Endoscopic ultrasonography in diagnosis and staging of pancreatic and biliary tumors. *Endoscopy* 1992; 24:304-308.
  24. Andersen HB, Effersoe H, Tjalve E, Burcharth F. CT for assessment of pancreatic and periampullary cancer. *Acta Radiologica* 1993; 34:569-572.
  25. Jimenez RE, Warshaw AL, Rattner DW, Willett CG, McGrath D, Fernandez-del Castillo C. Impact of laparoscopic staging in the treatment of pancreatic cancer. *Archives of Surgery* 2000; 135:409-415.
  26. Fernandez-del Castillo C, Rattner DW, Warshaw AL. Further experience with laparoscopy and peritoneal cytology in the staging of pancreatic cancer. *Br J Surg* 1995; 82:1127-1129.
  27. Bhutani MS. Endoscopic ultrasound in pancreatic diseases. Indications, limitations and the future. In: Barkin J, Lankisch PG, editors. *Pancreas update: Gastroenterology Clinics of North America*. Philadelphia: W.B. Saunders Company, 1999: 747-770.
  28. Yasuda K, Mukai H, Fujimoto S, Nakajima M, Kawai K. The diagnosis of pancreatic cancer by endoscopic ultrasonography. *Gastrointestinal Endoscopy* 1988; 34:1-8.
  29. Rosch T, Lorenz R, Braig C, Feurbach S, Siewert JR, Schudziarra V, et al. Endoscopic ultrasound in pancreatic tumor diagnosis. *Gastrointestinal Endoscopy* 1991; 37:347-352.
  30. Rosch T, Braig C, Gain T, Feubach S, Siewert JR, Schudziarra V, et al. Staging of pancreatic and ampullary carcinoma by endoscopic ultrasonography. Comparison with conventional sonography, computed tomography, and angiography. *Gastroenterology* 1992; 102:188-199.
  31. Tio TL, Sie HL, Kallimanis G, Luiken GJ, Kimmings AN, Huibregtse K, et al. Staging of ampullary and pancreatic carcinoma: comparison between endosonography and surgery. *Gastrointestinal Endoscopy* 1996; 44:706-713.
  32. Brugge WR, Lee MJ, Kelsey PB, Schapiro RH, Warshaw AL. The use of EUS to diagnose malignant portal venous system invasion by pancreatic cancer. *Gastrointestinal Endoscopy* 1996; 43:561-567.
  33. Snady H, Bruckner H, Siegel J, Cooperman A, Neff R, Kiefer L. Endoscopic ultrasonographic criteria of vascular invasion by potentially resectable pancreatic tumors. *Gastrointestinal Endoscopy* 1994; 40:326-333.
  34. Bhutani MS, Hawes RH, Hoffman BJ. A comparison of the accuracy of echo features during endoscopic ultrasound (EUS) and EUS-Guided fine needle aspiration for diagnosis of malignant lymph nodes invasion. *Gastrointestinal Endoscopy* 1997; 45:474-479.
  35. Warshaw AL, Tepper JE, Shipley WU. Laparoscopy in the staging and planning of therapy for pancreatic cancer. *Am J Surg* 1986; 151:76-80.
  36. Gouma DJ, Nieveen van Dijkum E, de Wit L, Obertop H. Laparoscopic staging of biliopancreatic malignancy. *Annals of Oncology* 1999; 10:33-36.
  37. Conlon KC, Dougherty E, Klimstra DS, Coit DG, Turnbull A, Brennan MF. The value of minimal access surgery in the staging of patients with potentially resectable peripancreatic malignancy. *Annals of Surgery* 1996; 223:134-140.
  38. Nieveen van Dijkum E, Sturm PD, de Wit LT, Offerhaus J, Obertop H, Gouma DJ. Cytology of peritoneal lavage performed during staging laparoscopy for gastrointestinal malignancies: Is it useful? *Annals of Surgery* 1998; 228:728-733.
  39. Ishikawa O, Ohigashi H, Imaoka S, Furukawa H, Sasaki Y, Fujita M, et al. Preoperative indications for extended pancreatectomy for locally advanced pancreas cancer involving the portal vein. *Annals of Surgery* 1992; 215:231-236.