

Buried bumper syndrome presenting with hematemesis two weeks after percutaneous endoscopic gastrostomy placement

Haris Papafragkakis^a, Mel A. Ona^a, Sury Anand^a, Yitzchak Moshenyat^b

The Brooklyn Hospital Center; NYU Lutheran Medical Center, Brooklyn, NY, USA

A 63-year-old woman with recent cerebrovascular accident, presented with hematemesis 15 days after placement of a percutaneous endoscopic gastrostomy (PEG) for dysphagia. She was afebrile, had no abdominal pain, and white blood cell count was normal. Urgent upper endoscopy showed that the PEG bumper was embedded within the gastric mucosa and eroded into the abdominal wall. There was significant ulceration, erythema, and exudate. The endoscopic findings are seen in Fig. 1 and 2. The PEG was cut and endoscopically removed through the mouth with a snare. The patient was made nil per os for 48 h and kept on a proton pump inhibitor infusion. Subsequently, a nasogastric tube was placed for feedings with plan for new PEG placement at a different site.

Buried bumper syndrome occurs in approximately 0.3-2.4% of the patients [1]. Lee and colleagues reported an incidence of 8.8% occurring on average 18 months after PEG placement [2]. It is a complication of PEG placement due to inordinate pressure and traction of the internal PEG bumper on the gastric wall and, albeit rare, is associated with significant morbidity. Patients with buried bumper may manifest with difficulty to infuse feedings through the PEG, abdominal wall abscess, peritonitis or necrotizing fasciitis among others [3].

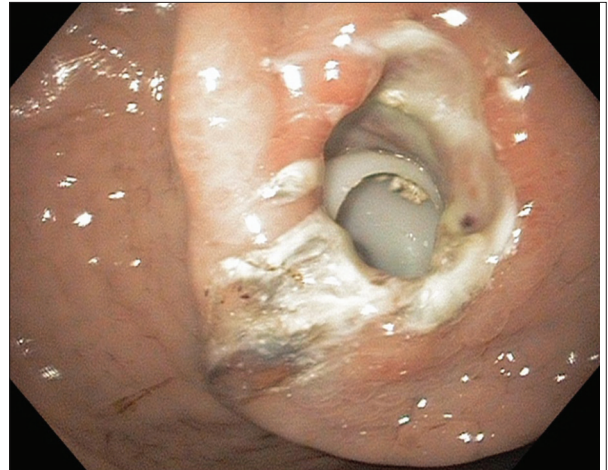

Figure 1 Percutaneous endoscopic gastrostomy bumper buried within gastric wall

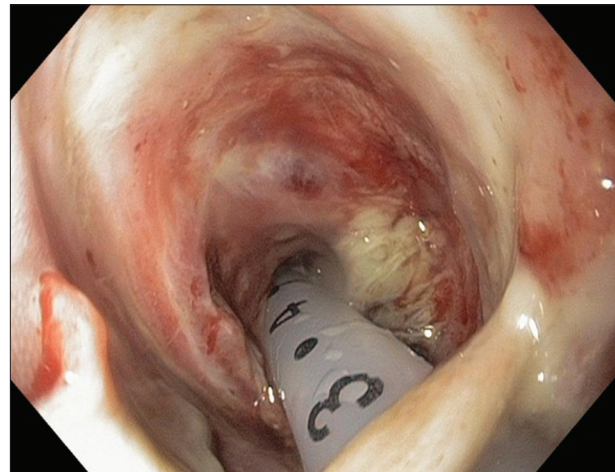


Figure 2 Endoscopic view from within the stomach showing the percutaneous endoscopic gastrostomy pushed into the gastric lumen revealing ulceration, erythema, and exudate

References

1. Venu RP, Brown RD, Pastika BJ, Erikson, LW Jr. The buried bumper syndrome: a simple management approach in two patients. *Gastrointest Endosc* 2002;**56**:582-584.
2. Lee TH, Lin JT. Clinical manifestations and management of buried bumper syndrome in patients with percutaneous endoscopic gastrostomy. *Gastrointest Endosc* 2008;**68**:580-584.
3. Tenenbaum D, Inayat F, Rubin M. Necrotizing fasciitis secondary to acute buried bumper syndrome. *Clin Gastroenterol Hepatol* 2015;**13**:A17-A18.

Departments of Gastroenterology and Hepatology, ^aThe Brooklyn Hospital Center (Haris Papafragkakis, Mel A. Ona, Sury Anand); ^bNYU Lutheran Medical Center (Yitzchak Moshenyat), Brooklyn, NY, USA

Conflict of Interest: None

Correspondence to: Haris Papafragkakis, The Brooklyn Hospital Center, 121 DeKalb Avenue, Brooklyn, NY 11201 USA, e-mail: papafgakish@gmail.com

Received 15 April 2015; accepted 19 April 2015