

Diagnostic yield of secretin-enhanced magnetic resonance cholangiopancreatography in the investigation of patients with acalculous biliary pain

Shridhar Dronamraju^a, John Scott^b, Kofi Oppong^c, Manu Nayar^c

Freeman Hospital, Newcastle Upon Tyne, UK

Abstract

Background Secretin-enhanced magnetic resonance cholangiopancreatography (S-MRCP) facilitates better visualization of the pancreaticobiliary ductal system but its role in patients with acalculous biliary pain (ABP) is yet to be established. The aim of this study was to assess the diagnostic yield and the role of S-MRCP in the investigation of ABP patients.

Methods This is a retrospective analysis of patients who had S-MRCP to investigate ABP over a 5-year period from June 2008 to May 2013. The findings and diagnosis as reported in the S-MRCP were compared with the findings on MRCP. The primary endpoint was the diagnostic yield of S-MRCP in ABP patients.

Results A total of 117 patients with ABP [28 (24%) male] had S-MRCP during the study period. The most common abnormality identified was obstruction at the level of ampulla or in the proximal pancreatic duct. S-MRCP was able to identify significant pathological findings in 8 of 34 (22%) patients in whom MRCP did not detect any abnormality. Endoscopic ultrasound (EUS) was performed in 67% of patients. S-MRCP identified abnormalities in 21 of 41 (54%) patients who had a normal EUS.

Conclusions We conclude that the diagnostic yield of S-MRCP for recognizing anatomical variants of the pancreatic ductal system, in particular ampullary or proximal pancreatic duct stricture, is better than MRCP and EUS. These findings reflect the dynamic nature of S-MRCP and its complementary role alongside MRCP, EUS and endoscopic retrograde cholangiopancreatography in ABP patients.

Keywords MRCP, secretin, abdominal pain, visceral pain, endosonography

Ann Gastroenterol 2016; 29 (3): 367-372

Introduction

Acalculous biliary pain (ABP) is a well-described clinical entity and describes patients with biliary colic-type abdominal pain in the absence of gallstones [1]. The diagnostic work-up of patients with ABP can be challenging, time-consuming,

expensive and frustrating to both patients and clinicians. There are a number of imaging modalities that can be used after an initial non-diagnostic abdominal ultrasound. These include computed tomography (CT) scan, magnetic resonance cholangiopancreatography (MRCP) and more recently endoscopic ultrasound (EUS) [2-4]. EUS is increasingly used as a second-line investigation after cross-sectional imaging. Endoscopic retrograde cholangiopancreatography (ERCP) originated as a diagnostic procedure but is associated with small but significant morbidity and mortality and its use should be reserved for therapeutic intervention. Secretin-enhanced MRCP (S-MRCP) which is MRCP performed after administering intravenous secretin, provides a dynamic assessment and better visualization of the pancreaticobiliary ductal system than conventional MRCP and may identify abnormalities that might otherwise go undetected on a conventional MRCP [5-16]. The aim of this study was to assess the additional diagnostic yield of S-MRCP if any among patients with ABP who also underwent MRCP and/or EUS.

Departments of ^aSurgery (Shridhar Dronamraju); ^bGI Radiology (John Scott); ^cGastroenterology (Kofi Oppong, Manu Nayar), Freeman Hospital, Newcastle upon Tyne, UK

Conflict of Interest: None

Correspondence to: Dr Manu K. Nayar, MBBS, MD, FRCP, Consultant Gastroenterologist, Freeman Hospital, Freeman Road, High Heaton, Newcastle upon Tyne, NE7 7DN, UK, Tel.: +44 191 2448755, Fax: +44 1912231249, e-mail: Manu.Nayar@nuth.nhs.uk

Received 20 November 2015; accepted 13 March 2016; published online 19 April 2016

DOI: <http://dx.doi.org/10.20524/aog.2016.0035>

Patients and methods

The study was done in a regional high-volume tertiary Hepato-Biliary and Pancreas Unit in North-East England which caters to a population of 3 million and receives referrals from 16 surrounding hospital trusts. This is a retrospective analysis of all patients with ABP in whom S-MRCP was requested over a 5-year period from June 2008 to May 2013. Patients were considered to have ABP if the clinical description of their abdominal symptoms were consistent with biliary type of abdominal pain and if baseline investigations including ultrasound scan of abdomen and/or MRCP did not show any evidence of gallstones. All patients had a normal upper gastrointestinal endoscopy. Patients with post-cholecystectomy biliary-type pain were also included in the study. Patients who had a previous sphincterotomy, bile duct exploration or any pancreatic surgery were excluded from this analysis. Patient demographics, details of symptoms, results of investigations including liver function tests, serum amylase, ultrasound scan of abdomen, CT of abdomen, MRCP, S-MRCP, EUS and ERCP were entered in to a Excel spreadsheet and analysed using SPSS[®] (version 19). The findings and diagnosis as reported in the S-MRCP were compared with the final working diagnosis to assess the usefulness of S-MRCP in the diagnostic work up of a patient presenting with ABP.

S-MRCP

S-MRCP was performed using 1.5 T Symphony and Avanto magnets (Siemens, Erlangen, Germany) with phased-array body coils. Patients were routinely starved for 4 h prior to the examination. A pre-S-MRCP examination was performed in all patients as previous imaging was often suboptimal or unavailable. Axial and coronal fast imaging with steady-state precession (FISP) and axial gradient echo in and out of phase T1 imaging of the upper abdomen were obtained. 3 mm thin slice heavily T2-weighted 2D breath-hold half-Fourier acquisition single-shot turbo spin-echo (HASTE) with fat suppression were performed in coronal, axial oblique and coronal oblique planes to optimally image the pancreatic duct and a coronal oblique 3D respiratory-triggered heavily T2-weighted FSE sequences with fat suppression was performed (1.5 mm slice and thick slab maximum intensity projection reconstructions) to image the biliary system and pancreatic ducts prior to secretin. T2-weighted slab MRCP images obtained from our MRI units were felt to be of inadequate quality for detecting subtle pancreatic duct abnormalities and were not used in this study. The baseline diameter of the main pancreatic duct was measured at the level of the body of the gland, and then secretin (Secrelux; Goldham Pharma GmbH, Zusmarshausen, Germany) was injected as an intravenous bolus (1 IU/kg). Basal main pancreatic duct diameter was considered normal when it was 3 mm or less. Following secretin, alternate axial oblique and coronal oblique thin

slice HASTE imaging was performed at 1-min intervals through the pancreatic duct for 15 min in the same plane and using the same parameters as the pre-secretin imaging. At 15 min post secretin, the coronal oblique fat suppressed 3D respiratory-triggered heavily T2-weighted FSE sequence was repeated. The diameter of the main pancreatic duct was recorded for each post secretin sequence and compared with the basal main pancreatic duct measurement.

All S-MRCP procedures were reported by a single specialist radiologist (JS). The S-MRCP examination was considered abnormal when main pancreatic duct diameter on the final sequence remained dilated by greater than 1 mm compared with the baseline measurement [4].

EUS and ERCP

EUS was performed under conscious sedation. Hitachi EUB-7500 or Preirus US workstations (Hitachi Medical Systems, Wellingborough, UK) and Pentax linear echoendoscopes (Pentax, Slough, UK) were used to carry out a standard EUS assessment. All procedures in the current study were done by experienced endosonographers (KO/MN) who have each performed >2000 pancreaticobiliary EUSs. ERCP was performed in select patients requiring therapeutic intervention.

The results of MRCP, S-MRCP, EUS and ERCP were analyzed and the diagnosis suggested in these investigations was compared with the final clinical diagnosis for each individual patient. As currently there is no gold standard investigation in the work-up of the patients presenting with ABP, the final diagnosis was made by the treating clinician after taking into consideration the patient's symptoms, clinical findings and the results of all the relevant investigations. Using these observations the diagnostic yield of S-MRCP (proportion of patients in whom S-MRCP diagnosis correlated with the final diagnosis) was estimated and the subgroup of patients with ABP in whom S-MRCP would be more useful was identified. A diagnostic algorithm for patients presenting with ABP has been proposed.

Ethics

All procedures were done as a part of standard patient care and not to a research protocol. Data collection was performed as part of our ongoing quality monitoring. In accordance with the U.K. National Research Ethics Service guidelines formal ethical review was not required.

Results

A total of 117 patients with ABP were referred for S-MRCP during the study period. There were 28 (24%) male and 89 (76%) female patients with a mean age of 48 years (range

18-82). The suspected clinical diagnoses in the initial referral letter of these patients are enumerated in Table 1. Fifty (43%) patients had more than one diagnoses. All patients had normal blood tests including serum amylase and liver function tests at the time of referral to the Unit. 86 (74%) patients had cholecystectomy prior to presentation.

All patients at the point of referral had an ultrasound scan of the abdomen which did not suggest any abnormality to explain their symptoms. All patients in our cohort had a MRCP performed either at another institution prior to referral. However as the MRCP was suboptimal or unavailable in some cases; a control film was always performed prior to administering secretin. S-MRCP findings were compared to the control MRCP findings before arriving at the final diagnosis. The diagnoses suggested on MRCP are shown in Table 2. In 37 (32%) patients more than one diagnoses were suggested. Chronic pancreatitis was the most common suggested diagnoses on MRCP. No patients had bile duct or gallbladder stones detected either on EUS or MRCP.

A total of 114 (97.4%) patients successfully completed S-MRCP test. Secretin was not administered in two patients as their baseline MRCP showed features of acute pancreatitis in one and definite evidence of complete pancreatic duct obstruction in the other. One patient could not complete the S-MRCP test due to claustrophobia. No patients developed pain after the injection of secretin, no immediate adverse reactions were identified and there were no recorded cases of post-secretin pancreatitis. The diagnoses based on S-MRCP findings are enumerated in Table 2.

The most common abnormality identified on S-MRCP in this group of patients was obstruction at the level of ampulla or in the proximal pancreatic duct. On comparing the results of S-MRCP with that of MRCP, in 40 (35%) patients S-MRCP provided additional information and/or suggested alternate diagnosis. Of the 37 patients in whom MRCP was reported normal, performing S-MRCP was able to identify significant pathological findings in 8 (22%) patients (Table 3). Of this subgroup comprising 8 patients, 5 patients had obstruction at level of ampulla or proximal pancreatic duct and they all had ERCP and sphincterotomy.

In the present study, only 78 (67%) patients had EUS. Table 2 shows the details of EUS diagnosis. In 53 (68%) patients S-MRCP findings differed from those of EUS whilst in 25 (32%) patients findings were similar. Of the 41 patients who had a normal EUS, S-MRCP was also reported as normal in 19, and in 21 (54%) patients it identified abnormalities. In one patient comparison could not be made due to poor quality scan. In 14 (34%) of these patients S-MRCP suggested an obstruction at the level of ampulla or in the proximal pancreatic duct. All 14 patients with suspected ampullary/pancreatic duct stenosis went on to have ERCP and 13 of them had sphincterotomy. In one patient sphincterotomy was unsuccessful due to failed cannulation. In the 58 patients reported to have a normal S-MRCP, the majority either had a normal EUS (19 patients) or EUS was not performed (24 patients).

Table 1 Suspected diagnosis at referral

Diagnosis at referral	Total number (190)
Suspected sphincter of Oddi dysfunction	
Type 1	2
Type 2	16
Type 3	35
Recurrent pancreatitis	41
Chronic pancreatitis	21
Pancreas divisum	39
NSAP/IBS/neuropathic pain	14
Others (microlithiasis, gallbladder dyskinesia, IPMN)	22

NSAP, nonspecific abdominal pain; IBS, irritable bowel syndrome; IPMN, intraductal papillary mucinous neoplasm

Table 2 Diagnosis based on different imaging modalities

Diagnosis	MRCP (n=117)*	S-MRCP (n=114)	EUS (n=78)
Normal	37 (31.6)	58 (50.8)	41 (53)
Obstruction at ampulla	17 (14.5)	26 (22.8)	4 (5.5)
Chronic pancreatitis	28 (23.9)	8 (7)	18 (25)
Pancreatic duct stricture	8 (6.8)	7 (6.1)	-
Pancreas divisum/partial divisum	13 (11.1)	15 (14)	10 (14)
Cysts/IPMN	4 (3.4)	3 (2.7)	4 (5.5)
Santorinicoele	4 (3.4)	1 (0.9)	-
Others	6 (3.3)	5 (4.4)	1 (1.4)

Numbers in parenthesis are percentages; *some patients had more than one suggested diagnoses

MRCP, magnetic resonance cholangiopancreatography; S-MRCP, secretin-enhanced MRCP; IPMN, intraductal papillary mucinous neoplasm

Table 3 S-MRCP findings in patients with reported normal MRCP

S-MRCP findings	Normal MRCP [N=37 (%)]
Normal	29 (78)
Obstruction at ampulla/ proximal pancreatic duct	5 (13)
Cyst/IPMN	1 (3)
Pancreas divisum	1 (3)
Santorinicoele	-
Pancreatic duct stricture	1 (3)
Chronic pancreatitis	-
Poor quality scan	-

MRCP, magnetic resonance cholangiopancreatography; S-MRCP, secretin-enhanced MRCP; IPMN, intraductal papillary mucinous neoplasm

Sphincter of Oddi dysfunction (SOD) subgroup

SOD patients are a difficult group of patients presenting with post-cholecystectomy pain. We provide

a tertiary referral service to a large population in the North-East of England. These patients usually have extensive investigations at the referring hospital before they are referred to our service for further management. The definitive investigation is biliary manometry \pm sphincterotomy. However, this investigation is associated with a high morbidity and mortality. Therefore, most Units providing this service will pursue less invasive investigations before proceeding to ERCP [8].

During this study period 53/117 patients were referred to the service with a suspected diagnosis of SOD; 49 (92%) had a normal MRCP. The other diagnosis was chronic pancreatitis (n=2), pancreas divisum (n=1) and dilated common bile duct/pancreatic duct (n=1). 47 (89%) patients had normal S-MRCP. The other diagnosis was stricture either at the ampulla or common bile duct/pancreatic duct [5]. One patient had a poor quality scan. 20/53 had manometry as part of further investigation and treatment of the pain. In this subgroup 15/20 had a normal S-MRCP. In addition, 11/12 with high ampullary pressures had a normal SMRCP. 5/8 with normal pressures had a normal S-MRCP. Of the 33 patients who did not proceed to ERCP and manometry; 29/33 had a normal S-MRCP. These patients did not have an ERCP. However, the other 4 patients had ERCP for suspected ampullary strictures.

Follow up of the remaining group of patients

The final clinical diagnosis was made based on the initial presentation, results of the investigations, response to the interventions and 12-month follow up. The final diagnosis in this cohort of patients is shown in Table 4. Patients were followed up for at least one year (range 13-36 months; median 16 months). Of the 78 (67%) patients who reported improvement in symptoms, 58 (50%) had endoscopic intervention. Twenty two (19%) patients had persistent symptoms, 7 (6%) had recurrence of symptoms after a transient symptom relief, and 10 (9%) were lost to follow up.

Table 4 Final diagnosis

Final clinical diagnoses	No. of patients
Sphincter of Oddi dysfunction	
Type 1	2
Type 2	5
Type 3	14
Recurrent pancreatitis	17
Chronic pancreatitis	28
Pancreas divisum	11
NSAP/IBS/Neuropathic pain	29
Others (microlithiasis, gallbladder dyskinesia, IPMN)	9

NSAP, nonspecific abdominal pain; IBS, irritable bowel syndrome; IPMN, intraductal papillary mucinous neoplasm

Discussion

ABP comprises a heterogeneous group of patients with similar symptoms but wide spectrum of underlying pathology, sometimes very difficult to diagnose and treat. These patients are generally young with a female preponderance [1]. ABP can be a symptom of biliary stricture, pancreatic duct stricture, recurrent acute pancreatitis, chronic pancreatitis, and pancreatic divisum, cysts in pancreas, santorinicele, biliary dyskinesia, SOD, visceral hypersensitivity (duodenal hyperalgesia) and functional hepatobiliary disease. From the time of referral to final diagnoses, the diagnostic work up in these patients is time consuming, expensive and frustrating both for the patient and the clinician.

Recent advances in the technology have given the clinicians a broader armamentarium of investigations which include ultrasound, high resolution CT scan, MRCP/S-MRCP, EUS and ERCP. In most situations the results of these investigations may be discordant and the clinicians have to make a balanced judgement to come up with an appropriate management plan. S-MRCP is a dynamic form of cross sectional imaging with an excellent safety profile [17,18]. There are published studies comparing the diagnostic accuracy of S-MRCP, EUS and ERCP in investigating patients with recurrent pancreatitis, chronic pancreatitis and SOD but there are no studies comparing these diagnostic modalities in patients with ABP [5,8]. This study, which is a retrospective analysis of all patients who had S-MRCP at a high-volume tertiary hepato-pancreato-biliary referral center, showed that S-MRCP provides additional diagnostic information over MRCP and EUS. In 40 (35%) patients S-MRCP suggested a diagnosis different from that reported on MRCP. S-MRCP also helps in either confirming or ruling out some of the findings suspected on MRCP. In the current study, S-MRCP helped rule out anatomical pancreatic ductal abnormalities reported on MRCP in 21 (18%) patients. More importantly, performing S-MRCP helped identify a significant abnormality in 8 of 37 (22%) patients who had a normal MRCP. Five of these 8 patients had obstruction at the ampulla. Likewise, Matos *et al* also reported that S-MRCP improved the visualization of the pancreatic ducts and helped detect pancreas divisum in an additional 23% of patients [19].

The diagnostic discrepancies identified in this study between MRCP and EUS with regards to identifying pancreatic ductal abnormalities have been reported previously. One study reported a 40% discordance between S-MRCP and secretin enhanced findings [5]. This high rate of discordance in these two different diagnostic modalities can be partially explained by differences in the imaging modalities. Whilst MRCP images the entire pancreatic ductal system at the same time; EUS gives better enhanced morphology of sections of the pancreatic duct where the endoscope can be kept in the same position to allow accurate repeat measurements of the pancreatic duct diameter.

In the current cohort, in patients who had a normal EUS, S-MRCP was able to identify significant pathology in 54% of patients with over half of these having obstruction at the level of ampulla or in the proximal pancreatic duct. On the contrary in patients who had a normal S-MRCP (n=58), whilst a majority

had either a normal EUS or EUS not performed (n=43), the most common abnormality reported on EUS was pancreatitis or cysts (n=10). This again gives an indication that S-MRCP has a good negative predictive value for pancreatic duct abnormalities but EUS is better than S-MRCP in identifying parenchymal abnormalities within the pancreas [20].

In the subgroup of patients with SOD, 49 patients with a normal MRCP; 47 (98%) had a normal S-MRCP. The majority of our patients were Type III SOD (14/21=67%). In addition, the manometry findings in 20/49 patients did not coincide with a significant finding on S-MRCP. Therefore S-MRCP did not add further information compared to both MRCP and EUS in our study. This is in contrast to the retrospective data by Pereira *et al* [8] which highlighted the concordance with Type II SOD in 63% patients.

ABP is a complex condition to diagnose and treat and therefore no single investigation or intervention will provide an accurate final diagnosis in all cases. In the context of the current study, it was important to assess if and how the findings on the S-MRCP influenced patient management and outcomes. In 21 (54%) patients who had normal EUS, S-MRCP identified an abnormality and the majority of these patients had ampullary obstruction. S-MRCP aided clinical management in this group of patients by clarifying the next intervention which in most cases was an ERCP and sphincterotomy. Eighteen of 21 (86%) patients had improvement in their symptoms at their last follow up while 3 patients had persistent symptoms. Similarly, in patients with features of chronic pancreatitis or a stricture in the mid or distal pancreatic duct on the S-MRCP, ERCP and sphincterotomy was generally avoided. However, EUS would not necessarily pick up evidence of ampullary obstruction (unless there is a clear structural abnormality) as it is not a dynamic investigation like S-MRCP. S-MRCP in these situations complements EUS and helps in the decision making process.

Studies comparing the outcomes of two or more different modalities of investigations need to ensure that the investigations are performed according to a standardized protocol and reported by adequately experienced staff. Performing S-MRCP and interpreting the results of this dynamic imaging needs experience and expertise which at present are predominately available only in certain tertiary referral centers in the U.K. Likewise, EUS is also an observer dependent highly specialized investigation performed by experienced endosonographers at select centers. Both endosonographers in this study (KO and MN) have performed >5000 pancreato-biliary EUSs and the radiologist performing S-MRCP (JS) is a senior hepatobiliary radiologist who has been performing these investigations for over 10 years.

There are several limitations in this study. First, this is a retrospective study of a cohort of patients who all had S-MRCP as part of their investigative work-up for ABP. Hence, patients with ABP who did not have S-MRCP have not been included in the study. However, as patients with ABP have a wide spectrum of clinical presentation it will be extremely difficult if not impossible to include all patients with ABP in a clinical study of this nature. The other potential drawback of this study

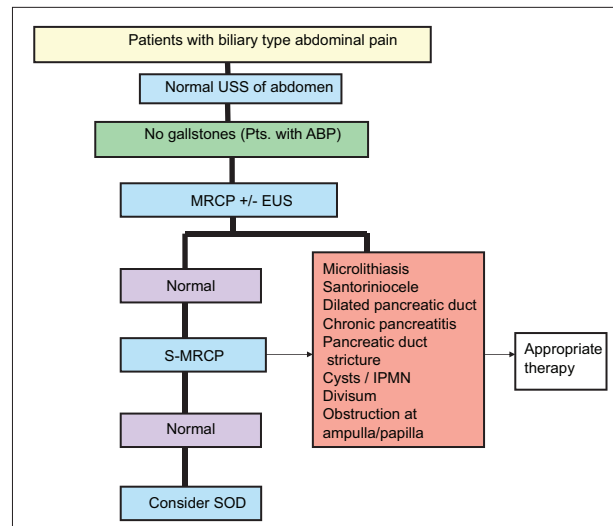


Figure 1 Algorithm for investigating a patient with acalculous biliary-type pain (ABP)

USS, ultrasound scan; MRCP, magnetic resonance cholangiopancreatography; S-MRCP, secretin-enhanced MRCP; SOD, sphincter of Oddi dysfunction

Summary Box

What is already known:

- The diagnostic work-up of patients with acalculous biliary pain (ABP) can be challenging, time-consuming, expensive and frustrating to both patients and clinicians
- After an initial non-diagnostic abdominal ultrasound, secretin-enhanced magnetic resonance cholangiopancreatography (S-MRCP) provides a dynamic assessment and better visualization of the pancreaticobiliary ductal system than conventional MRCP and may identify abnormalities that might otherwise go undetected on a conventional MRC

What the new findings are:

- S-MRCP has a definite role in the diagnostic algorithm investigating patients presenting with ABP
- S-MRCP is very safe and complements the role of endoscopic ultrasound (EUS) and endoscopic retrograde cholangiopancreatography but is superior to MRCP alone
- S-MRCP is not useful in patients with suspected sphincter of Oddi dysfunction following a normal EUS and MRCP

is that only a proportion of the study cohort had EUS. This is mainly because EUS is an invasive investigation associated

with a small but significant risk of complications subsequently it is difficult to justify its use routinely in all patients with ABP. However, the intent of the study was not to compare S-MRCP with EUS but was to assess the diagnostic yield of S-MRCP in this group of patients.

In conclusion, the current study indicates that S-MRCP has a definite role in the diagnostic algorithm to investigate patients presenting with ABP. It complements the role of EUS and ERCP but is superior to MRCP alone. It has the advantage of being a non-invasive investigation unlike the EUS and ERCP and is very safe. We also reported that S-MRCP is not useful in patients with suspected SOD following a normal EUS and MRCP. Finally, we propose an algorithm (Fig. 1) to help clinicians investigate patients presenting with ABP. Following this algorithm may enable better utilization of the resources and minimize the risk to patients.

References

- Shaffer E. Acalculous biliary pain: new concepts for an old entity. *Dig Liver Dis* 2003;**35**(Suppl 3):S20-S25.
- Siddiqui AA, Tholey D, Kedika R, Loren DE, Kowalski TE, Eloubeidi MA. Low but significant yield of endosonography in patients with suspected Sphincter of Oddi dysfunction type III with normal imaging studies. *J Gastrointest Liver Dis* 2012;**21**:271-275.
- Kondo S, Isayama H, Akahane M, et al. Detection of common bile duct stones: comparison between endoscopic ultrasonography, magnetic resonance cholangiography, and helical-computed-tomographic cholangiography. *Eur J Radiol* 2005;**54**:271-275.
- Fusaroli P, Kypraios D, Caletti G, Eloubeidi MA. Pancreaticobiliary endoscopic ultrasound: a systematic review of the levels of evidence, performance and outcomes. *World J Gastroenterol* 2012;**18**:4243-4256.
- Mariani A, Arcidiacono PG, Curioni S, Giussani A, Testoni PA. Diagnostic yield of ERCP and secretin-enhanced MRCP and EUS in patients with acute recurrent pancreatitis of unknown aetiology. *Dig Liver Dis* 2009;**41**:753-758.
- Matos C, Metens T, Deviere J, et al. Pancreatic duct: morphologic and functional evaluation with dynamic MR pancreatography after secretin stimulation. *Radiology* 1997;**203**:435-441.
- Mariani A, Curioni S, Zanella A, et al. Secretin MRCP and endoscopic pancreatic manometry in the evaluation of sphincter of Oddi function: a comparative pilot study in patients with idiopathic recurrent pancreatitis. *Gastrointest Endosc* 2003;**58**:847-852.
- Pereira SP, Gillams A, Sgouros SN, Webster GJ, Hatfield AR. Prospective comparison of secretin-stimulated magnetic resonance cholangiopancreatography with Manometry in the diagnosis of sphincter of Oddi dysfunction types II and III. *Gut* 2007;**56**:809-813.
- Donati F, Boraschi P, Gigoni R et al. Secretin-stimulated MR cholangio-pancreatography in the evaluation of asymptomatic patients with non-specific pancreatic hyperenzymemia. *Eur J Radiol* 2010;**75**:e38-e44.
- Amodio A, Manfredi R, Katsotourchi AM, et al. Prospective evaluation of subjects with chronic asymptomatic pancreatic hyperenzymemia. *Am J Gastroenterol* 2012;**107**:1089-1095.
- Bret PM, Reinhold C, Taourel P, et al. Pancreas divisum: evaluation with MR cholangiopancreatography. *Radiology* 1996;**199**:99-103.
- Pezzilli R. Pancreatitis. Secretin increases the diagnostic yield of MRCP. *Nat Rev Gastroenterol Hepatol* 2014;**11**:519-520.
- Sherman S, Freeman ML, Tarnasky PR, et al. Administration of secretin (RG1068) increases the sensitivity of detection of duct abnormalities by magnetic resonance cholangiopancreatography in patients with pancreatitis. *Gastroenterology* 2014;**147**:646-654 e2.
- Sandrasegaran K, Cote GA, Tahir B, et al. The utility of secretin-enhanced MRCP in diagnosing congenital anomalies. *Abdom Imaging* 2014;**39**:979-987.
- Rustagi T, Njei B. Magnetic resonance cholangiopancreatography in the diagnosis of pancreas divisum: a systematic review and meta-analysis. *Pancreas* 2014;**43**:823-828.
- Hansen TM, Nilsson M, Gram M, Frøkjær JB. Morphological and functional evaluation of chronic pancreatitis with magnetic resonance imaging. *World J Gastroenterol* 2013;**19**:7241-7346.
- Mensel B, Messner P, Mayerle J, et al. Secretin-stimulated MRCP in volunteers: assessment of safety, duct visualization, and pancreatic exocrine function. *AJR Am J Roentgenol* 2014;**202**:102-108.
- Tirkes T, Menias CO, Sandrasegaran K. MR imaging techniques for pancreas. *Radiol Clin North Am* 2012;**50**:379-393.
- Matos C, Metens T, Deviere J, Delhaye M, Le Moine O, Cremer M. Pancreas divisum: evaluation with secretin enhanced magnetic resonance cholangiopancreatography. *Gastrointest Endosc* 2001;**53**:728-733.
- Katanuma A, Isayama H, Bapaye A. Endoscopic ultrasonography using new functions for pancreatobiliary diseases: current status and future perspectives. *Dig Endosc* 2015;**27**(Suppl 1):47-54.