

Original article

Primary laparoscopic button gastrostomy in infants and children

M. Ververidis, T. Tsang

SUMMARY

Aim: Laparoscopic gastrostomy in children has recently become an established minimally invasive alternative to endoscopic insertion. The authors describe a method of primary laparoscopic button gastrostomy, in order to emphasize certain technical modifications that make it safer, simpler and more effective than previously reported techniques.

Materials and methods: The medical records of 17 children who underwent primary laparoscopic button gastrostomy are reviewed. The Seldinger technique was used for the button insertion and the stomach was fixed to the epigastrium with two U-sutures. The modifications of our technique as compared to others are: 1) the tract is minimally dilated to permit a snug fit of the button, 2) a size 12 Fr button is used in all cases and 3) a Tuohy needle stabilizes the device to negotiate the tight gastric tract.

Results: The mean age at operation was 25 months (range 3 months to 13 years). The main indication for gastrostomy was inability to swallow secondary to neurological impairment (82%). Four patients had concomitant laparoscopic antireflux procedure. The mean hospital stay for gastrostomy alone was three days. The mean follow-up was six months. There was no perioperative mortality or major life-threatening complications associated with the gastrostomy. No complication was serious enough to require removal of the button or hospitalization. There were no leaks. The nutritional status improved remarkably in the majority of patients.

Conclusions: A primary button gastrostomy can be performed safely under laparoscopic guidance via a single umbilical port with minimal morbidity. The use of a Tuohy needle for the stabilization of the button facilitates the introduction of even the smallest size of gastrostomy device.

Key words: Gastrostomy, Button, Laparoscopy, Children

INTRODUCTION

A feeding gastrostomy in children can be performed by a variety of open, percutaneous endoscopic and laparoscopic methods.¹ Percutaneous fluoroscopic methods have also been used.² Although percutaneous endoscopic gastrostomy (PEG) was initially claimed to reduce the morbidity and mortality of open techniques,³ its advantage over surgical gastrostomy was later reported to be minimal.⁴ In addition, PEG in children is associated with significant morbidity and life-threatening complications, particularly in neurologically impaired children.⁵ Several laparoscopic variations of gastrostomy insertion have recently been widely applied in children as a minimally invasive alternative to endoscopic methods, and the procedure is claimed to be safer.⁶⁻¹¹

We describe the technique of laparoscopic button gastrostomy that we adopted, with emphasis on certain modifications and benefits to patients.

Abbreviations

PEG = Percutaneous Endoscopic Gastrostomy

Acknowledgements for financial support

The authors express their thanks to the State Scholarship Foundation of Greece (IKY) for funding the research.

Department of Paediatric Surgery, Norfolk and Norwich University Hospital, University of East Anglia, United Kingdom

Author for correspondence:

Moschos Ververidis, 1 Marathonomachon, 151 24 Athens, Greece, Tel/Fax: 210-6107060, e-mail: lentza@otenet.gr

MATERIALS AND METHODS

We reviewed the notes of 17 children who underwent primary laparoscopic button gastrostomy with the proposed technique at the Norfolk and Norwich University Hospital from June 2001 to January 2003. The patients' characteristics (underlying disease, indications, and preoperative investigations) were recorded. Gastroesophageal reflux was not routinely investigated prior to gastrostomy unless there were symptoms. A 24-hour Ph study was performed when indicated in children more than one year of age. All patients underwent regular follow-up by the surgeons, the attending physicians and a specialist nurse. A dietician also reviewed most cases. The details of the operative procedure and the postoperative complications were registered, with emphasis on the ones related to gastrostomy device. A complication was defined as major if it was life threatening or required hospitalization or surgery for treatment.

Surgical Technique

The procedure is carried out under general anaesthetic with full muscle relaxation. In the cases of concomitant fundoplication the button is placed at the end of the procedure. One intravenous dose of Cefuroxime is administered at induction. Laparoscopy is performed through a 5mm umbilical port inserted by open technique. The pneumoperitoneum is set to a maximum pressure of 8 to 10 mm Hg. The anterior stomach wall is identified and the site of gastrostomy is marked on the skin of the left upper quadrant, keeping well away from the costal margin. The stomach is inflated with air via a nasogastric tube, until the anterior surface comes under the gastrostomy site.

A stab wound is created in the epigastrium to penetrate the abdominal wall and the wound is dilated appropriately. A 3.5mm laparoscopic grasper is inserted through the stab wound to hold the gastric wall at the site of the proposed gastrostomy tract. This is aimed at the anterior surface of the stomach near the greater curvature and away from the pylorus, in order to prevent gastric outlet obstruction.

The gastric wall near the grasper is anchored on the anterior abdominal wall by two strong non-absorbable monofilament U stitches (Ethilon No 0 or 1 metric). A long curved cutting needle is used to pass the stitch through the skin surface and the full thickness of the gastric wall. The sutures are secured with haemostatic forceps and the grasper is removed.

A needle (a 12 G Kendell intravenous cannula) is

inserted to puncture the gastric wall in an appropriate avascular position, a guide wire is passed into the stomach and the needle is removed.

The tract of the abdominal and gastric wall is dilated by passage of graduated dilators (X-ray dilators, PBN Medical, Denmark A/S) along the guide wire. The size of maximal dilatation is 2 Fr higher than the diameter of the button (eg. up to 14 Fr size for a 12 Fr button). The thickness of the abdominal wall is estimated for the choice of the appropriate length of gastrostomy button (AMT mini button, Applied Medical Technology, Cleveland, USA). A Tuohy needle with a 16G lumen (SIMS Portex Ltd, UK) is passed into the button to enable it to go over the guide wire and slide into the stomach (Fig 1). Traction is applied via the U-stitches to the anterior gastric wall to facilitate this step (Fig 2). The needle and the guide wire are removed. The balloon is inflated and the anchor stitches are tightened and tied over the wings of the button. The initial volume of inflation (3ml) is less than the recommended to allow for oedema of abdominal wall to develop during the first few postoperative days. The proper approximation of the stomach on the anterior abdominal wall is verified prior to removal of the laparoscope (Fig 3). The umbilical



Figure 1. A Tuohy needle is used to stabilize the small and flexible button for insertion through a tight gastric tract.

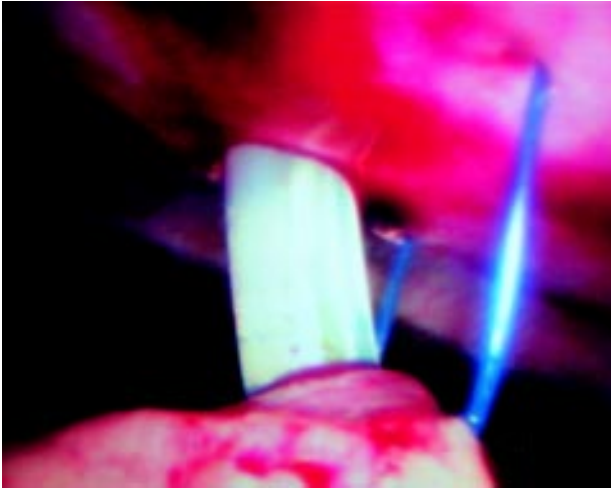


Figure 2. Laparoscopic view: The anterior stomach wall is secured with U-stitches and drawn up against the abdominal wall.

wound is closed in layers with absorbable sutures. Local anaesthesia with levobupivacaine 0.25% at appropriate dose (2ml/kg) for body weight is injected around the umbilical wound and the gastrostomy at the end of the procedure. An extension feeding tube is connected to the button and supported on the abdominal wall.

Postoperative care

The gastrostomy is left on free drainage and is used after 6 hours. Glucose and electrolyte solution (Dioralyte) is started initially in 3 hourly bolus infusion in gradually increasing volume. Milk is administered on the first postoperative day. If there is concomitant fundoplication, the gastrostomy is used on the second postoperative day. Small bolus infusions at more frequent intervals are used for the first week to avoid over-distention of stomach. The patient's hospital stay is extended until the 3rd postoperative day for the caregivers to be taught the technique of gastrostomy feeding and become familiar with the button care. The patient is reviewed on the seventh postoperative day. The integrity of the balloon is verified, it is inflated up to the recommended volume (5ml) and the holding stitches are removed. The button is changed after 4 to 5 months.

RESULTS

Seventeen children underwent primary laparoscopic button gastrostomy with the described technique during an 18 month period. The mean age at operation was 25 months (range 3 months to 13 years) and the mean weight 10,3 kg (range 4,3 to 47,7 kg). Six patients (35%) were

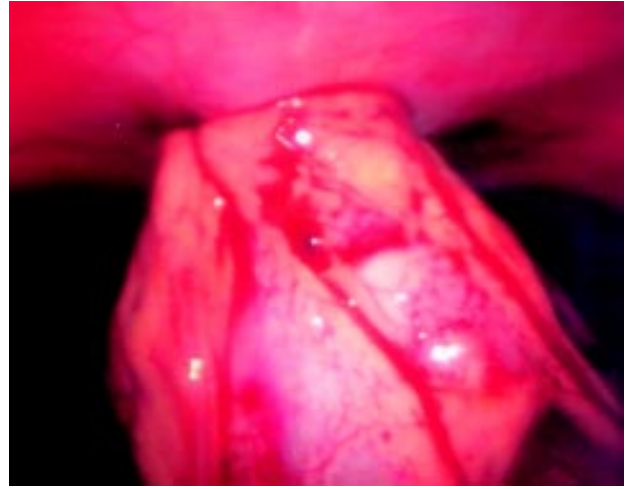


Figure 3. Laparoscopic view: The final position of the stomach on the anterior abdominal wall is verified.

less than one year of age at operation. The main indications for gastrostomy were inability to swallow in 14 patients (most of them with neurological impairment of varying aetiology) and inadequate calorie intake in three patients (all with cystic fibrosis). All children were dependent on NG tube feeding in part or in total (50%) for varying periods of time prior to gastrostomy. An upper gastrointestinal study was performed in 7 patients with symptoms suggestive of gastro-esophageal reflux (vomiting, aspiration, and recurrent chest infections). It was normal in four. Positive findings included a sliding hernia, poor propulsion with aspiration and malrotation. Four children underwent a 24-hour Ph study. It was positive for reflux in two cases (oesophageal Ph of 4 or less during at least of 4% of time measured). Three patients underwent oesophagogastrosopy with normal findings at the time of the laparoscopic procedure (for diagnostic purposes in two, and to confirm the position of button in one). A concomitant laparoscopic Nissen fundoplication was performed in four cases (one with sliding hernia, two with pathological reflux in Ph study and one with almost sudden infant death syndrome due to aspiration). One patient with non-functioning symptomatic gallbladder and malrotation had concomitant laparoscopic cholecystectomy and open Ladd's procedure.

The mean hospital stay was five days (range 2 to 90 days). The mean stay in the cases with fundoplication was six days (range 5 to 7). In two patients with gastrostomy the postoperative hospital stay was extended for several weeks for reasons not related to the procedure (one for rehabilitation after head trauma with tetraplegia,

and the second for protection after non-accidental head injury). The mean hospital stay for the rest was three days (range 2 to 7). The mean follow up was six months (range one to 20 months).

There were no intraoperative complications and no postoperative life-threatening complications with any definite association to laparoscopy or the gastrostomy. Two patients developed serious late complications, possibly related to the procedure. One neurologically impaired patient died suddenly, at five months, after Nissen fundoplication with gastrostomy. The indication for antireflux procedure was respiratory arrest due to airway obstruction and the initial postoperative course had been uneventful. The postmortem examination revealed bronchopneumonia and hypoplastic nasopharynx/larynx, possibly contributing to the recurrent preoperative airway obstruction. There were no comments about the integrity of fundoplication. A second patient who had gastrostomy for palliation of a terminal neurological condition (Leigh's encephalopathy) developed symptoms of gastroesophageal reflux one year after the operation. The symptoms improved with antireflux medication, but he developed recurrent chest infections and respiratory arrest.

The majority of patients had one or more minor complications related to the stoma (Table 1). None was serious enough to require removal of the button or hospitalization. Seven patients (41%) were complicated by wound infection, which was peristomal in six of them. In two patients, the infection also involved one of the ports and in another one the supporting stitch tract. They were minor, without any systemic symptoms or abscess formation, and were managed successfully with a course of oral antibiotics. There was recurrent infection in one case.

Ten children (59%) developed over-granulation tissue around the gastrostomy wound. Surgical excision was not required in any case and they were managed with

local measures (application of Terra-cortil steroid cream). It tended to be persistent or recurrent in some cases, creating an intermittently erythematous and murky gastrostomy wound.

There was button dislodgement in four cases (23%), which occurred several weeks after the operation. The button was repositioned without need of general anaesthetic. The balloon was faulty in one, and burst in another case. One child with dysphagia and gagging after fundoplication required frequent and repeated balloon replacement until antacid medication was started.

Three patients had transient gastrostomy wound pain in the early postoperative period. In one case this was attributed to the supporting stitches and was managed successfully with earlier removal. Two children developed minor upper gastrointestinal bleeding, probably due to gastritis, which stopped with H2 blockers.

Two patients had persistent gagging at a mean follow up of six months after fundoplication. Four children with severe neurological impairment developed symptoms suggestive of secondary reflux (persistent vomiting and recurrent chest infections). The symptoms appeared at varying times after the gastrostomy (one week to one year) and improved remarkably in all but one case, with antireflux medication and modification of the mode of food administration. One child continues to vomit occasionally during the night. None was investigated further or required antireflux surgery at follow-up.

Parents and carers were satisfied with gastrostomy feeding in all cases. The nutritional status improved remarkably in the majority of patients. One child had poor weight gain at follow-up. Six patients were unable to tolerate boluses and required long term continuous overnight feeding. Nine patients are able to receive varying amounts of oral food, with improvement in two cases after the gastrostomy. A child with posttraumatic tetraplegia recovered remarkably enough to returned to full oral intake two months after the gastrostomy.

Table 1. Complications in 17 patients with primary laparoscopic button gastrostomy

Complication	Number of patients	%
Infection	7	41
Granulation tissue	10	59
Wound pain	3	18
Minor gastric bleeding	2	12
Button dislodgement	4	23
Secondary reflux	4	23

DISCUSSION

Comments on the advantages of button over percutaneous endoscopic gastrostomy

The minimally invasive technique of PEG was introduced by Gauderer³ and has been applied extensively to the paediatric population since 1980.^{12,5} Placement of button gastrostomy was initially a secondary procedure following an initial open or percutaneous endoscopic tube gastrostomy. The main aim of primary button

insertion was to avoid the complications of leakage, tissue reaction, image problems with the use of tube gastrostomy¹² and, in particular, the gastric separation and peritonitis associated with the interval procedure.¹³ Primary button endoscopic gastrostomy was first reported in children by Treem *et al*¹⁴ and soon claimed to be a safe and effective way to eliminate the need for tube gastrostomy and minimize the associated complications.¹⁵ Primary laparoscopic methods of button insertion became standard and proved the simplicity, functional and cosmetic superiority over the gastrostomy tube.¹⁰ We recommend a gastrostomy button as primary feeding method in most cases because it is durable enough and has the least possible bulk. Nevertheless a PEG tube, which is always introduced under laparoscopic control, is preferable to a button in cases where regular follow up and proper catheter care cannot be guaranteed, as well as in anatomically deformed patients in whom the stomach is deeply situated under the rib cage.

Comments on the advantages of laparoscopic over endoscopic gastrostomy

The laparoscopically guided technique for gastrostomy was initially recommended for patients with previous abdominal surgery or abnormal visceral orientation.¹⁶ It was soon applied in children for insertion of tube¹⁷ or button.¹⁸ The technique has been expanded further, as it claims to combine the advantages of PEG with the safety of an open procedure.^{19,6,7,10} All authors agree that the most important merit of laparoscopically guided gastrostomy as compared with the PEG, is that it reduces the risk of intrabdominal organ damage. Other complications, like laceration of a major gastric vessel and mal-positioning of the gastrostomy site, are also less likely to occur with laparoscopy. We did not encounter any of the major life-threatening complications that have been reported after PEG, such as bowel perforation and major bleeding.^{20,5,21} We were able to confirm the observation, also made by others,¹⁷ that the stomach rotates anteriorly during insufflation, bringing the colon in between the stomach and abdominal wall, and thus increasing the risk of gastrocolic fistula.

Randomized controlled trials to compare laparoscopic with PEG gastrostomy have not been reported. Nevertheless, the authors are convinced that, if a minimally invasive approach is selected, the safest way to perform feeding gastrostomy is under the direct vision of a laparoscope. By this means, the risk of the inadvertent puncture of the colon, one of the major complications of the blind procedure included in PEG, is almost eliminated. Furthermore, in order to minimize the risk of visceral or

major vascular injury, we apply the open modified Hasson's technique for the laparoscopic trocar insertion.²² In the case of doubt about the identity of the visualized hollow organ, the laparoscope can be advanced under the left liver lobe, where the stomach is confidently recognized and its anterior wall is followed down to the greater curvature.

Comments on the advantages and disadvantages of other laparoscopic techniques.

Various laparoscopic methods have been proposed to ensure safe insertion and secure fixation of the stomach to the gastrostomy site. Two or more secondary ports were initially used, depending on the size and shape of the patient, the presence of scarring, and concomitant laparoscopic fundoplication.⁶ Purse string sutures on the stomach around the stoma site were inserted to reduce leak. If additional security was required, the stitches were pulled through the abdominal entry site to be hitched around the flange, or the stomach was hitched to the abdominal wall by interrupted intra- or extra-corporeal stitches.

A two port technique that was described by Anderson *et al*,⁷ involves a 1.5 cm incision on the anterior abdominal wall, through which the stomach wall is temporarily exteriorized for the insertion of gastrostomy. A modification of this method involves a single puncture and endoscopy through the gastrostomy exit site.²³ A high incidence (48%) of minor complications with these techniques was reported, most commonly granulation tissue and leakage around the device.²⁴ A second 5-mm port at the button site and exteriorization of the stomach for a purse-string application is also advocated by Rothenberg *et al*,¹⁰ with minimal complication rate (2,1%), mostly wound infections. The advantage of all these methods is the secure gastric fixation on the abdominal wall.

Georgeson⁸ used a 3mm laparoscopic clamp through a stab wound to stabilize the stomach and applied the Seldinger technique for the button insertion. He recommended the fixation of the stomach with two U-sutures. The stitches are placed from outside, through the abdominal wall, and are removed after 48 hours. The Seldinger technique – applied only in some cases under laparoscopic control - has also been described by Hament *et al* with 31% PEG related complication rate.²⁵ This method used T-fasteners to anchor the stomach on the abdominal wall, a technique initially introduced by Duh and Way²⁶ and recommended for paediatric patients by Stylianos *et al*.¹⁸ The threads fixing the anchors were

thought to be the main responsible factors for the high incidence of peristomal infection and abscess of this series. Another modification of the Seldinger technique involves the insertion of a 5-mm telescope through a peel-away sheath prior to button, in order to confirm intragastric position and recognize any inadvertent perforation of the posterior gastric wall.¹¹ Several authors recommend that the correct position of the button be confirmed by gastroscopy, provided that the oesophagus is patent.^{15,6,24}

The earliest primary endoscopic buttons in children were of a large size (18 Fr) and had a high incidence of migration out of the gastric lumen and into the abdominal wall tract (24%).¹⁴ These authors recommended bigger sizes (24 Fr), even in small infants, to reduce the incidence of this complication, while others suggested inadequate shaft length as a possible cause of tissue ischaemia that may have been responsible for the migration.¹⁵ Dislodgment of gastrostomy device does not seem to be a problem any more, with the new generation of buttons currently used in the laparoscopic methods.^{10,24} The smallest button that has been used by all reported techniques is size 14 Fr. For the very small infant, insertion of a 10 Fr or 12 Fr Foley catheter has been recommended.²⁷

Comments on technical points of our method

We have modified Georgeson technique as follows: 1) in small infants, we use a 12 F button instead of the Foley catheter, 2) the tract is minimally dilated, 3) a Tuohy needle is used to stabilize the small button for insertion and 4) the holding stitches are removed after 7 days.

The minimal degree of tract dilatation requires a very small skin incision and leads to the snug fit of the button on the gastric wall. By this means leakage is minimized. In fact, a large incision and tract may have been responsible for the high reported incidence of leakage around the device with other techniques.²⁴ Careful puncture of the anterior gastric wall (in fact the stomach is allowed to gradually poke on to the needle during inflation) minimizes the risk of inadvertent damage of the posterior wall that is reported by others.¹¹ The site of insertion on the stomach is aimed to be near the greater curvature and away from the pylorus, in order to prevent gastric outlet obstruction especially in small infants.²⁵

According to the authors' experience, it is difficult to negotiate the flexible tube of a small size button through a tight tract of the abdominal and gastric walls. The placement of an 8F Cook dilator through appropriately

sized Mic-Key buttons has recently been described.⁹ We introduce the Tuohy needle to stiffen the tube of the button and facilitate its passage using the Seldinger technique. This is an epidural needle with a bevelled tip, which, in addition, reduces the trauma to the gastric wall. It matches perfectly with the smallest available size of button (12 F AMT mini button, Applied Medical Technology, Cleveland, USA), which is suitable for infants.

Perforation of the posterior gastric wall by a button device (Mic-Key, Medical Innovations Corporation, Ballard Medical Products, Draper, UT, USA) has been reported in a patient following fundoplication.²⁸ Although adhesions around the stomach may have contributed to this complication, it was also suggested that the tip of this type of button, distal to the balloon, might have caused the perforation. The button that we use does not have a projection, thus making this complication less likely.

We do not perform gastroscopy to confirm the position of the button, unless examination of the oesophagus is necessary for diagnostic purposes. Aspiration of the gastric air after the procedure makes the outline and the exact position of the balloon visible, as it is surrounded by the collapsed gastric wall.

A big curved needle allows easy placement of the U-stitch. A cutting needle is preferable, as compared with the a-traumatic one, because it facilitates the repeated insertion (in and out) through all the layers of the abdominal wall. The insertion under laparoscopic direct vision minimizes the risk of vascular trauma to the stomach.

This study showed that a feeding button gastrostomy can safely be performed as a primary procedure under laparoscopic guidance via a single umbilical port with minimal morbidity. The factors, which contributed towards nil leakage with our method include close approximation of the gastrostomy site to the abdominal wall using the U-stitches, small gastrostomy button and minimal tract dilatation.

Acknowledgements

The authors express their thanks to Mrs Julia Shirliff, Paediatric Surgery Nurse Specialist at Norfolk and Norwich University Hospital for her invaluable help in the evaluation of the results of this study and to the State Scholarship Foundation of Greece (IKY) for funding the research.

REFERENCES

1. Georgeson KF. Laparoscopic versus open procedures for long term enteral access. *Nutr Clin Pract* 1997; 12 (Suppl): S7-S8
2. Marx MV, Hernandez RJ. Pediatric interventional radiology: an overview. In: Spitz L, Coran A, Rob and Smith's Pediatric Surgery, 5th edition, Chapman and Hall, 1995:887-900
3. Gauderer MWL, Ponsky JL, Izant RJ. Gastrostomy without laparotomy: A percutaneous endoscopic technique. *J Pediatr Surg* 1980; 15: 872-875
4. Stiegman G, Goff J, Silas D, Pearlman N, Sun J Norton N. Endoscopic versus operative gastrostomy. Final results of a prospective randomized trial. *Gastrointest Endosc* 1990; 36: 1-5
5. Khattak IU, Kimber C, Kiely EM, Spitz L. Percutaneous endoscopic gastrostomy in paediatric practice. *J Pediatr Surg* 1998; 33: 67-72
6. Humphrey G, Najmaldin AS. Laparoscopic gastrostomy in children. *Pediatr Surg Int* 1997; 12: 501-504
7. Andersson L, Mikaelsson C, Arnbjornsson E, Larsson LT. Laparoscopy aided gastrostomy in children. *Ann Chir Gynaecol* 1997; 86:19-22
8. Georgeson KE. Laparoscopic fundoplication and gastrostomy. *Semin Laparosc Surg* 1998; 5: 25-30.
9. Ostie DJ, Holcomb GW. Laparoscopic fundoplication and gastrostomy. *Semin Pediatr Surg* 2002; 11: 196-204
10. Rothenberg SS, Bealer JF, Chang JHT. Primary laparoscopic placement of gastrostomy buttons for feeding tubes. A safer and simpler technique. *Surg Endosc* 1999; 13: 995-997
11. Tomicic JT, Luks FI, Shalon L, Tract TF. Laparoscopic gastrostomy in infants and children. *Eur J Pediatr Surg* 2002; 12: 107-110
12. Gauderer MWL. Percutaneous endoscopic gastrostomy: A 10 year experience with 220 children. *J Pediatr Surg* 1991; 26 : 288-294
13. Benkof KJ. When buttoning up is not sound advice. *J Pediatr Gastroenterol Nutr* 1993; 17: 358-360
14. Treem WR, Etienne NL, Hymans JS. Percutaneous endoscopic placement of the button gastrostomy tube as initial procedure in infants and children. *J Pediatr Gastroenterol Nutr* 1993; 17: 382-386
15. Stylianos S, Flanigan LM. Primary button gastrostomy: a simplified percutaneous, open, laparoscopy guided technique. *J Pediatr Surg* 1995; 30: 219-220
16. Raaf JH, Manney M, Okafor E, *et al*. Laparoscopic placement of percutaneous endoscopic gastrostomy feeding tube. *J Laparoendosc Surg* 1993; 3: 411-414
17. Croaker GDH, Najmaldin AS. Laparoscopically assisted percutaneous endoscopic gastrostomy. *Pediatr Surg Int* 1997; 12: 130-131
18. Stylianos S, Flanigan M. Laparoscopy-guided percutaneous button gastrostomy in children after previous abdominal surgery. *J laparoendosc Surg* 1995; 5: 199-201
19. Sampson LK, Georgeson KE, Winters DC. Laparoscopic gastrostomy as an adjunct procedure to laparoscopic fundoplication in children. *Surg Endosc* 1996; 10: 1106-1110
20. Behrens R, Lang T, Muschweck H, Richter T, Hofbeck M. Percutaneous endoscopic gastrostomy in children and adolescents. *J Pediatr Gastroenterol Nutr* 1997; 25: 487-491
21. Kimber C, Beasley S. Limitations of percutaneous endoscopic gastrostomy in facilitating enteral nutrition in children: review and shortcomings of a new technique. *J Paediatr Child Health* 1999; 35: 427-431
22. Humphrey G, Najmaldin AS. Modification of Hasson's technique in paediatric laparoscopy. *B J Surg* 1994; 81: 1319
23. Mikaelsson C, Arnbjornsson E. Single puncture laparoscopic gastrostomy in children. *Pediatr Surg Intern* 1998; 14: 43-44
24. Arnbjuornsson E, Larsson LT, Linthagen T. Complications of Laparoscopy-aided gastrostomies in pediatric practice. *J Pediatr Surg* 1999; 34 (12): 1843-1846
25. Hament JM, Bax NMA, van der Zee DC, De Schyver J, Nesselaaar C. Complications of percutaneous endoscopic gastrostomy with or without concomitant antireflux surgery in 96 children. *J Pediatr Surg* 2001; 36: 1412-1415
26. Duh QY, Way LW. Laparoscopic gastrostomy using T-fasteners as retractors and anchors. *Surg Endosc* 1993; 7: 60-63
27. Chung DH, Georgeson KE. Fundoplication and gastrostomy. *Semin Pediatr Surg* 1998; 7: 213-219
28. Arnbjuornsson E, Jakobsson I, Larsson LT, Mikaelsson C. Gastrostomy button causing perforation of the posterior gastric wall. *Acta Paediatr* 1998; 87: 1203-1204