

A new mechanism of gastroesophageal reflux in hiatal hernia documented by high-resolution impedance manometry: a case report

Francesco Torresan, Daniele Mandolesi, Alexandros Ioannou, Simone Nicoletti, Leonardo Henry Eusebi, Franco Bazzoli

University of Bologna, Italy

Abstract

Gastroesophageal reflux disease (GERD) is recognized to be a multifactorial disease and several mechanisms leading to reflux have been described, nevertheless its pathophysiology has not been fully clarified. Hiatus hernia is a known risk factor for GERD since it impairs the esophagogastric junction, leading to: reduction in lower esophageal sphincter pressure; increase in the frequency of the transient lower esophageal sphincter relaxation; and impairment of esophageal clearance. Last generation diagnostic techniques have improved the understanding of these mechanisms. A 72-year-old woman with hiatus hernia and GERD underwent a high resolution impedance manometry (HRIM) after a partial response to treatment with pantoprazole. None of the proposed pathophysiological mechanisms for GERD could explain the presence of reflux: HRIM showed normal lower esophageal sphincter (LES) pressure and contractile integral, complete bolus clearance in all test swallows, and absence of transient LES relaxation. However, after the end of each peristaltic wave, as the LES pressure returned to resting values, a gastroesophageal reflux was detected until the following swallow. We describe an interesting case of a patient with a sliding hiatus hernia, with symptoms suggestive of GERD, in which HRIM revealed a new possible mechanism through which hiatus hernia may lead to GERD.

Keywords Gastroesophageal reflux disease, hiatus hernia, high resolution impedance manometry

Ann Gastroenterol 2016; 29 (4): 548-550

Introduction

Hiatus hernia (HH) interferes with the anatomy and physiology of the normal anti-reflux barrier through several mechanisms, such as: reduction in lower esophageal sphincter (LES) pressure; increase in the frequency of the transient LES relaxation (TLESR); and impairment of esophageal clearance [1]. Another proposed mechanism by which HH leads to GERD is that gastric content gets trapped in the hernial sac (between LES and crural diaphragm, CD), and subsequently refluxes during swallow-induced relaxations of the LES [2]. Recently, high resolution impedance manometry (HRIM) has been introduced to combine the benefits of high resolution manometry and impedance-based bolus transit assessment.

Gastroenterology Unit, Department of Medical and Surgical Sciences, University of Bologna, Italy

Conflict of Interest: None

Correspondence to: Dr. Daniele Mandolesi, Department of Medical and Surgical Sciences, Policlinico S. Orsola, Via Massarenti 9, 40138 Bologna, Italy, Tel./Fax: +39 0516363376, e-mail: dani.mandolesi@gmail.com

Received 24 March 2016; accepted 19 May 2016; published online 10 June 2016

DOI: <http://dx.doi.org/10.20524/aog.2016.0055>

We herein report the case of a patient presenting with heartburn, acid regurgitation and hoarseness, in which HRIM revealed a new possible mechanism by which HH leads to GERD even with normal basal LES pressure, without TLESRs and normal esophageal clearance.

Case report

A 72-year-old woman was referred to our clinic due to heartburn, acid regurgitation and hoarseness during the last year. One year before the admission, at the beginning of her symptoms, the patient underwent an upper endoscopy and a barium esophagogram, showing a 4-cm long sliding HH, with a grade B esophagitis according to Los Angeles classification. Her primary care physician started treatment with pantoprazole 40 mg b.i.d. with only partial symptom improvement. Thus, before considering HH surgical repair, she was sent to our center for further investigations.

A HRIM was performed using a solid-state manometric assembly with 36 circumferential sensors spaced at 1 cm with an intraluminal impedance monitoring (Sierra Scientific Instruments Inc., Los Angeles, CA.) and 18 impedance segments at 2-cm intervals. The study was performed after at least 6-h fasting and according to the standard procedure based on

10 water swallows in supine position, including a 30-sec period to assess basal sphincter pressure. The results of HRIM are summarized in Table 1. Manometric study showed that basal LES pressure was 23.7 mmHg (normal values: 13-43 mmHg). The integrated relaxation pressure (6.9 mmHg; N: <15 mmHg) and the mean distal contractile integral (3272.1 mmHg-cm-sec; N: 500-5000 mmHg-cm-sec) were normal. The study of esophageal motility demonstrated peristaltic waves in 9/10 swallows (90%); double-peaked waves were detected in 3/10 (30%; N: ≤15). The intrabolus pressure was significantly higher than the normal value (41 mmHg - N: <17). No TLESRs were detected.

Impedance results demonstrated an effective peristalsis, with 100% swallowing with complete bolus transit (10/10 swallows) and confirmed a complete bolus clearance in each swallow. All the swallow phases were studied: at first the synchronized opening of both the upper and lower esophageal sphincters, which provided the complete clearance of the esophagus, then the peristaltic progression of the bolus through the esophageal body and finally the closure of the LES, once the bolus was passed in the gastric compartment.

In our patient, few seconds after the end of each peristaltic wave, as the LES pressure recovered its resting value and after the complete esophageal clearance, a gastroesophageal reflux was detected until the following swallow, which provided the complete clearance of the esophagus after the swallow-induced opening of the LES (Fig. 1,2).

Table 1 High-resolution impedance manometry findings

Parameter	Value	Normal values
Lower esophageal sphincter		
LES length (cm)	1.7	2.7-4.8
LES pressure (mmHg)	13.7	13-43
Integrated relaxation pressure (mmHg)	6.9	<15
Body peristalsis		
Peristaltic contractions (speed ≥6.25 cm/sec) (%)	90	≥80
Simultaneous contractions (speed ≥6.25 cm/sec) (%)	10	≤20
Aperistalsis	0	0
Ineffective	0	0
Wave mean duration (sec)	5.4	2.7-5.4
Double-peaked waves (%)	30	≤15
High resolution parameters		
Distal contractile integral (mean) (mmHg-cm-sec)	3272,1	500-5000
Intrabolus pressure (mean max) (mmHg)	41	<17
Distal latency (sec)	6.3	>4.5
Swallows with compartmentalized pressurization (%)	0	
Impedance analysis		
Incomplete bolus clearance (n)	0	-

LES, lower esophageal sphincter

Discussion

HH causes an anatomical and physiological interference in the normal anti-reflux barrier with several mechanisms: it reduces LES length and pressure, impairs the augmenting effects of the diaphragmatic crus, is associated with decreased esophageal peristalsis, increases the cross-sectional area of the esophagogastric junction (EGJ), and acts as a reservoir allowing reflux from the hernial sac into the esophagus during swallowing [1]. All these mechanisms lead to: reduction in LES competence; increase in the frequency of the acid-associated TLESRs; and impairment of esophageal clearance [3-5].

However, the relation between TLESRs and reflux has been already redefined in the last years: several studies showed that TLESRs are not more frequent in patients with GERD than in age- and sex-matched asymptomatic volunteers, however, when TLESRs occur in patients, they are twice as likely to be associated with acid reflux [9]. Moreover, Van Herwaarden *et al* showed that the majority of the reflux episodes occur during a TLESR in patients without HH, while in the presence of HH other mechanisms may play a determinant role [8,10].

HRIM studies introduced interesting data about EGJ morphology, highlighting a possible axial separation between LES and CD. This event can be interpreted as the presence of HH, or, more precisely, as an anatomical disruption of EGJ, leading to a reduction in its physiological anti-reflux barrier activity. On this basis, EGJ was classified into three types: type I (no LES-CD separation); type II (LES and CD are spatially separated such that there is a double-peaked pressure profile); and type III (the separation between peaks is >2 cm). Recently, Tolone *et al* demonstrated that the increasing separation between LES and CD, from type I to type III EGJ, is associated with a significant increase in reflux episodes, esophageal acid exposure time and positive reflux-symptom association [11,12]. These considerations have been applied in the evaluation of the LES contractile integral, whose defective values seem to show a gradual and significant increase in reflux. However, further studies are needed to explore its utility in the management of GERD [6,7].

It has been supposed, but never demonstrated, that the increasing pressure in the hernial sac could also be another important component; Mittal *et al* [2] proposed that gastric content trapped in the HH sac could reflux during subsequent swallow-induced relaxations of the LES.

The case we described is particularly interesting since none of the proposed mechanisms could explain the presence of reflux showed by the use of HRIM. Not only the LES pressure, but also the contractile integral was normal. The HRIM evaluation also showed complete bolus clearance in all test swallows and the absence of TLESRs. However, after the end of each peristaltic wave, as the LES pressure returned to resting values, a gastroesophageal reflux was detected until the following swallow.

The most probable hypothesis could be that reflux is due to a transient increase in hernial sac pressure: the hernial sac acts as a reservoir increasing its pressure to overcome the basal LES pressure. As a consequence, the gastric content could reflux from the hernial sac into the esophagus, not during swallowing phase like Gordon *et al* [1] proposed, but after the end of each peristaltic wave until the following swallow. The mechanism

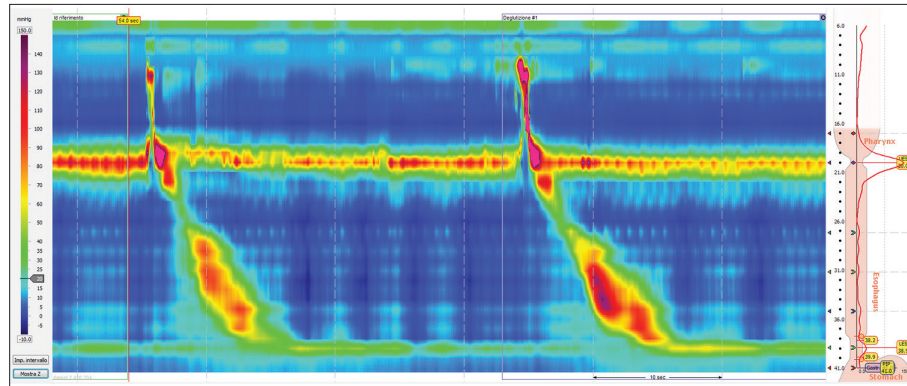


Figure 1 High resolution manometry shows normal basal lower esophageal sphincter (LES) pressure, normal esophageal peristalsis waves and no transient LES relaxations

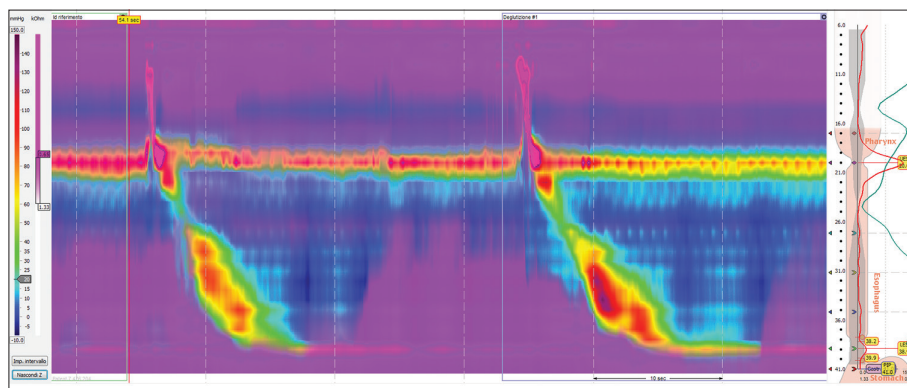


Figure 2 The impedance study shows the complete bolus clearance and the gastroesophageal reflux until the following swallow

we have described may be similar to what happens in the acid pocket of patients with HH, with the difference that in our case reflux occurs even in absence of TLESRs and with a perfectly working LES, despite HH. The advent of new generation technologies, like HRM, has allowed a more accurate and precise assessment of the EGJ and its increasing use could open to new considerations on the pathophysiology of GERD.

References

- Gordon C, Kang JY, Neild PJ, Maxwell JD. The role of the hiatus hernia in gastro-oesophageal reflux disease. *Aliment Pharmacol Ther* 2004;**20**:719-732.
- Mittal RK, Lange RC, McCallum RW. Identification and mechanism of delayed esophageal acid clearance in subjects with hiatus hernia. *Gastroenterology* 1987;**92**:130-135.
- Sifrim D, Holloway R, Silny J, Tack J, Lerut A, Janssens J. Composition of the postprandial refluxate in patients with gastroesophageal reflux disease. *Am J Gastroenterol* 2001;**96**:647-655.
- Trudgill NJ, Riley SA. Transient lower esophageal sphincter relaxations are no more frequent in patients with gastroesophageal reflux disease than in asymptomatic volunteers. *Am J Gastroenterol* 2001;**96**:2569-2574.
- Jones MP, Sloan SS, Jovanovic B, Kahrilas PJ. Impaired egress rather than increased access: an important independent predictor of erosive esophagitis. *Neurogastroenterol Motil* 2002;**14**:625-631.
- Nicodeme F, Pipa-Muniz M, Khanna K, Kahrilas PJ, Pandolfino JE. Quantifying esophagogastric junction contractility with a novel HRM topographic metric, the EGJ-Contractile Integral: normative values and preliminary evaluation in PPI non-responders. *Neurogastroenterol Motil* 2014;**26**:353-360.
- Hoshino M, Sundaram A, Mittal SK. Role of the lower esophageal sphincter on acid exposure revisited with high-resolution manometry. *J Am Coll Surg* 2011;**213**:743-750.
- Bredenoord AJ, Weusten BL, Timmer R, Smout AJ. Intermittent spatial separation of diaphragm and lower esophageal sphincter favors acidic and weakly acidic reflux. *Gastroenterology* 2006;**130**:334-340.
- Herregods TV, Bredenoord AJ, Smout AJ. Pathophysiology of gastroesophageal reflux disease: new understanding in a new era. *Neurogastroenterol Motil* 2015;**27**:1202-1213.
- Van Herwaarden MA, Samsom M, Smout AJ. Excess gastroesophageal reflux in patients with hiatus hernia is caused by mechanisms other than transient LES relaxations. *Gastroenterology* 2000;**119**:1439-1446.
- Tolone S, De Bortoli N, Marabotto E, et al. Esophagogastric junction contractility for clinical assessment in patients with GERD: a real added value? *Neurogastroenterol Motil* 2015;**27**:1423-1431.
- Tolone S, De Cassan C, De Bortoli N, et al. Esophagogastric junction morphology is associated with positive impedance-pH monitoring in patients with GERD. *Neurogastroenterol Motil* 2015;**27**:1175-1182.