

Pathology of nonalcoholic fatty liver disease

D.G. Tiniakos, Ch. Kittas

SUMMARY

Nonalcoholic fatty liver disease (NAFLD) may be the most common cause of chronic liver disease in Western countries, with an estimated prevalence of up to 24% in the general population. NAFLD is considered the hepatic manifestation of the metabolic syndrome and has been etiologically correlated with insulin resistance. The histopathological spectrum of NAFLD ranges from simple steatosis to nonalcoholic steatohepatitis (NASH), with or without fibrosis, and cirrhosis. Liver biopsy is the "gold standard" for diagnosing NASH in a patient with clinical features of NAFLD, image detected steatosis and chronically elevated liver enzymes. This review discusses the histopathological findings of NAFLD in adults and children, including features representing resolution of NASH following treatment and features of prognostic information. Additionally, current systems of semiquantitative assessment in NAFLD and NASH are reviewed and the concurrence of NAFLD and NASH with other chronic liver diseases, mainly hepatitis C, is discussed.

Key words: steatosis, steatohepatitis, nonalcoholic, liver, pathology

1. INTRODUCTION

Nonalcoholic fatty liver disease (NAFLD) is a growing medical problem in Western countries and the most common cause of chronic liver disease with a prevalence of up to 24% in the general population.¹⁻³ Recent sur-

veys have shown that NAFLD may be responsible for approximately 80% of adults with elevated aminotransferase values in the US.^{4,5} NAFLD is considered the hepatic manifestation of the metabolic syndrome,⁶⁻⁹ a cluster of disorders that includes obesity, diabetes mellitus, dyslipidaemia, arteriosclerosis and hypertension, and has been etiologically associated with insulin resistance.¹⁰⁻¹² Other aetiological factors include nutritional disorders such as rapid weight loss, total parenteral nutrition and malnutrition, drugs, occupational toxins, jejunoileal bypass/gastroplasty surgery, bacterial contamination of the small bowel, and inherited metabolic disorders.¹⁻³

The diagnosis of NAFLD is based on clinico-pathological criteria; the minimal tissue change is hepatocellular steatosis, i.e. accumulation of triglycerides within hepatocytes,^{13,14} in a patient without excessive alcohol consumption (typically >20g/day for women and >40g/day for men).^{1-3,15} NAFLD encompasses a wide range of clinico-pathological disorders ranging on histology from "simple" steatosis, to nonalcoholic steatohepatitis (NASH), when steatosis is accompanied by necroinflammatory changes; NASH may also include fibrosis and/or cirrhosis.^{1,16-20} The entire histologic spectrum of NAFLD may be seen in patients who are not obese^{2,21} and in patients with normal aminotransferase levels.²² It is of great interest that NASH, once thought as a disease with benign course, is currently considered a significant cause of cryptogenic cirrhosis.¹⁷ The development of hepatocellular carcinoma is in some cases the final part in the natural history of NAFLD.²³⁻²⁷

The presence of steatosis in the liver of NAFLD patients can be confirmed by ultrasound, computerized tomography (CT) and magnetic resonance imaging,²⁸⁻²⁹ but none of these imaging techniques can distinguish simple steatosis from NASH³⁰ and may not highlight small amounts of accumulated fat.¹⁵ Liver biopsy remains the method of choice for confirming or excluding the diagnosis of NASH in a patient with clinical features of

Laboratory of Histology and Embryology, University of Athens
School of Medicine, Athens, Greece

Author for correspondence:

Dina G. Tiniakos, MD, PhD, Laboratory of Histology & Embryology, Medical School University of Athens, 75, M. Asias str, Goudi, Athens 11527, Greece, Tel: 210-7462302, Fax: 210-7462340, e-mail: dtiniak@med.uoa.gr

NAFLD, image-detected steatosis and elevated liver enzymes.^{2,14,15,31} Furthermore, it may indicate the concurrence of NASH with other forms of chronic liver disease or, more importantly, suggest another diagnosis.^{32,33} Evaluation of liver histology in NASH is required for characterization and quantification of parenchymal necroinflammatory injury, determination of the presence and type of fibrosis and assessment of architectural changes thus providing significant prognostic information.^{32,34-36} The course of tissue injury over time may be assessed in repeat liver biopsies and, in the case of treatment trials, the efficacy and potential toxicity of therapeutic agents can be evaluated.^{2,3}

2. PATHOLOGY OF NAFLD AND NASH

2.1. Brief historical overview

Pathologists have documented similarities of liver lesions in morbid obesity and diabetics with those of alcoholics for several decades. Connor³⁷ has described fatty infiltration of liver and development of cirrhosis in diabetics in 1938, while Westwater and Feiner³⁸ presented the histological findings of NAFLD in the liver of obese patients in 1958. Thaler³⁹ further contributed on the subject with clinical and pathological features of the disease in 1962. Since then, several papers on liver pathology in obese and diabetic individuals have appeared in the medical literature⁴⁰⁻⁴³ until the publication of the landmark study of Ludwig *et al*⁴⁴ in 1980, where the term “nonalcoholic steatohepatitis-NASH” was applied to the progressive form of NAFLD with histopathological similarities to alcoholic steatohepatitis.

2.2. Pathological features of adult NAFLD and NASH

Currently, almost 25 years after the introduction of the term “NASH” by Ludwig to describe the histological findings of steatohepatitis in liver biopsies of patients denying significant alcohol consumption,⁴⁴ there is no uniformity among hepatopathologists regarding the minimal necessary criteria for the diagnosis of NASH.^{2,3,15} This may account for the significant differences, ranging from 2-30%, in the reported frequency of histologically diagnosed NASH in NAFLD patients.^{9,45-47} However, it is generally accepted that a constellation of findings is required for the histopathological identification of adult NASH i.e. steatosis, hepatocellular injury in the form of ballooning, lobular inflammation (Figure 1) and perisinusoidal fibrosis, usually with a zone 3 predominance.

2.2.1 Steatosis

Hepatocellular steatosis is the hallmark of NAFLD and is more commonly macrovesicular, with a single large fat droplet displacing the nucleus or with smaller well defined intracytoplasmic droplets (Figure 1). Groups of hepatocytes with microvesicular steatosis may be observed.^{13,14} Macrovesicular steatosis, is usually the result of abnormalities in the delivery, metabolism, synthesis and export of lipids, while microvesicular steatosis is the hallmark of diseases with defective beta-oxidation of fatty acids, including mitochondrial cytopathies, disorders of urea metabolism and acquired disorders, such as Reye’s syndrome, acute fatty liver of pregnancy, drug toxicity etc.^{14,32}

The accumulation of fat in NAFLD usually starts in zone 3 and in more severe cases may occupy the whole acinus. Steatosis is usually evaluated semi-quantitatively by dividing the involved liver parenchyma in thirds, i.e. <33%, 33-66% and >66%.^{16,48,49} However, there are no uniform criteria for the assessment of steatosis. Recently, it has been reported that histological grading of hepatic steatosis does not correlate with liver tissue triglyceride content as measured by a biochemical method.⁵⁰

It is of interest that there is no strict histologic criterion regarding the smallest amount of fat in the liver to be considered as “pathologic”. Steatosis involving less than 5% of hepatocytes is thought to be clinically insignificant and most hepatopathologists would ignore it if it is an isolated finding.

Steatosis may not persist during the progression of

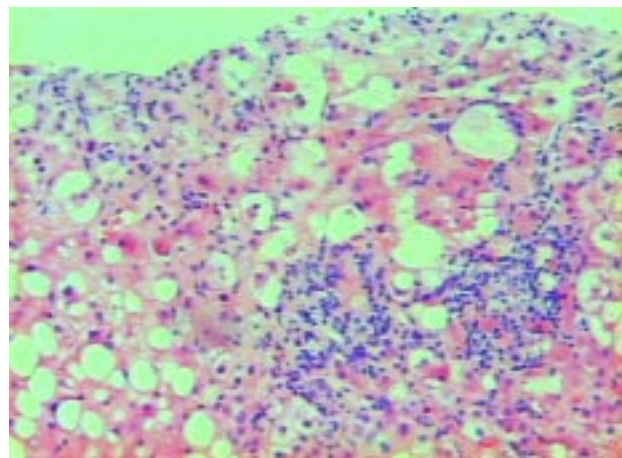


Figure 1. Nonalcoholic steatohepatitis: Macrovesicular steatosis, hepatocellular ballooning and mixed lobular inflammation. Perisinusoidal fibrosis is not evident without special stains for collagen (H&E, 200x)

NAFLD and may disappear in cases of NASH-related cirrhosis. It is now accepted that many cases of cryptogenic cirrhosis may represent “burned-out” NASH.^{2,17}

2.2.2 Hepatocellular injury

Hepatocellular ballooning refers to enlarged, swollen hepatocytes with cytoplasmic rarefaction (Figure 2), which are predominantly located among steatotic hepatocytes in acinar zone 3, usually in areas of perisinusoidal fibrosis.^{14,15,32} Although ballooned hepatocytes have been considered to be the result of microtubular disruption and severe cell injury leading to lytic necrosis,¹³ recent ultrastructural evidence suggests that they may represent an adaptation phenomenon in human NAFLD.⁵¹

Apoptotic hepatocytes, in the form of acidophil bodies, are found occasionally in NASH^{15,32,52,53} and are less common than in alcoholic steatohepatitis.^{54,55} In NASH, hepatocellular apoptosis is mediated by death receptors (Fas and TNFR1)^{52,53} and has been shown to correlate with active NF-kappaB p65 expression and disease severity.⁵³

2.2.3 Lobular and/or portal inflammation

Lobular inflammation is usually mild in NASH and frequently consists of a mixed inflammatory cell infiltrate composed of mononuclear cells and polymorphonuclear leukocytes within sinusoids and close to ballooned hepatocytes (Figure 1).^{15,32} Satellitosis, which refers to hepatocytes containing Mallory’s hyaline surrounded by polymorphs, may be present. Mild chronic inflammation may be seen in the lobules and portal tracts both in the active and the resolving phase of NASH. The presence of por-

tal inflammation greater in amount than lobular inflammation should raise the suspicion of a concurrent process such as chronic viral hepatitis C.^{14,15,32}

Lipogranulomas, consisting of chronic inflammatory cells, Kupffer cells and rare eosinophils surrounding steatotic hepatocytes, may be found near terminal hepatic venules, scattered in the acinus or in portal tracts. They are a common, but not necessary, finding in NASH. They are usually small in size, but large lipogranulomas may exist and may be associated with fibrosis, a finding which should not be confused with parenchymal fibrosis of steatohepatitis.³² Microgranulomas and single pigmented, PAS-diestase positive, Kupffer cells may be also seen in the acini.

2.2.4 Fibrosis

The characteristic pattern of fibrosis in steatohepatitis of alcoholic or nonalcoholic etiology is pericellular/perisinusoidal fibrosis (“chicken-wire”) resulting from deposition of collagen in the space of Disse (Figure 3). This type of fibrosis is initially observed in zone 3 of the acinus^{14,15,32} and it is usually associated with active steatohepatitis lesions. The finding of zone 3 pericellular/perisinusoidal fibrosis in the absence of active lesions may indicate prior episodes of steatohepatitis.¹⁵ With progression of the disease, periportal fibrosis may be evident, followed in some cases by bridging fibrosis and cirrhosis (macronodular, micronodular or mixed). At the cirrhotic stage, the perisinusoidal pattern of fibrosis may be absent.³²

Dense pericellular/perisinusoidal fibrosis may be detected in routine hematoxylin and eosin (H&E) stained

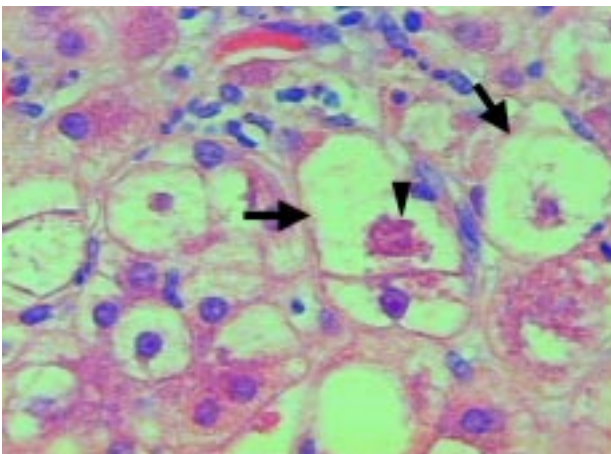


Figure 2. Ballooned hepatocytes (arrows) with rarefied cytoplasm and presence of Mallory’s hyaline (arrowhead) (H&E, 400x)

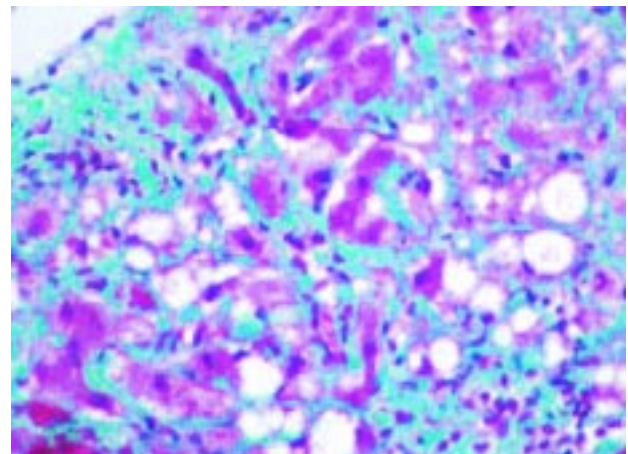


Figure 3. Dense perisinusoidal (“chicken-wire”) fibrosis in NASH (Masson’s trichrome, 200x)

sections, but usually a special histochemical stain for collagen is required for the assessment of collagen deposition, such as Masson's trichrome. Masson's trichrome stains fewer collagen types than Sweet reticulin or Picrosirius red.¹⁵

In overweight NASH patients, a group with primarily periportal fibrosis has been described.³⁴ Recently, portal fibrosis associated with steatosis in the absence of the characteristic zone 3 acinar lesions of NASH, has been reported in the liver of obese patients undergoing gastric bypass surgery.⁵⁶

In NASH, sinusoidal collagen formation is the result of hepatic stellate cell (HSC) activation^{57,58} as in other chronic liver diseases. It has been claimed that HSC activation in NASH correlates with steatosis grade and fibrosis.⁵⁷ However, other investigators suggest that it is the inflammation that induces fibrogenesis in NASH.⁵⁸ Recently, the HSC activation score, as measured by immunohistochemistry using alpha-smooth muscle actin which is a marker of HSC activation, has been shown to predict progression of fibrosis in patients with NAFLD.⁵⁹

2.2.5 Mallory's hyaline

Mallory's hyaline-MH (Mallory body) is a dense intracytoplasmic inclusion, commonly found in zone 3 ballooned hepatocytes and in areas of perisinusoidal fibrosis in steatohepatitis of alcoholic (ASH) or nonalcoholic etiology (Figure 2).^{14,15,32} In the former, they are well formed and may be abundant, while in the latter may not be easily identified when present and they are not as common as in ASH. MH is chemotactic and it is considered responsible for the lesion of "satellitosis" described above.^{15,32} Matteoni *et al*, in their seminal study on the classification of NAFLD, considered MH a required finding for the diagnosis of progressive NAFLD, delineating types 3 and 4 from types 1 and 2 (Table 1).¹⁶ However, it is now considered by most authors that although MH is helpful for the diagnosis of steatohepatitis, when present, it is not a required lesion.

MH is not a diagnostic finding of steatohepatitis because it can be observed in zone 1 in many liver diseases, including chronic cholestasis, Wilson's disease, non-Wilsonian hepatic copper toxicosis, drug-related hepatitis (amiodarone, perhexiline maleate etc), metabolic disorders, focal nodular hyperplasia and hepatocellular carcinoma.^{13,15,32,60,61} MH is composed of misfolded cytokeratin 8 and 18 intermediate filaments, ubiquitinated cytokeratin, the stress-induced and ubiquitin-binding protein p62, heat-shock proteins 70 and 25, alpha β -crystal-

Table 1. NAFLD classification system (modified from ref. 16)

Type 1 Simple steatosis

Type 2 Steatosis with lobular inflammation

Type 3 Steatosis, lobular inflammation, ballooned hepatocytes*

Type 4 as above with either Mallory's hyaline or fibrosis*

*Types 3 and 4 histologically and clinically resemble NASH

lin and the, not yet further characterized, M_M120-1 antigen.^{61,62} Cytokeratins may have a protective role against toxic cell injury and recent studies have shown that MH is not deleterious to the cell, but, on the contrary, it may be the result of a cellular defense response to toxic stress.⁶²

2.2.6 Megamitochondria

Megamitochondria may appear as intracellular round or cigar-shaped eosinophilic structures in hepatocytes of livers with NASH. Ultrastructural studies of human liver in NAFLD, have shown many abnormalities in megamitochondria: crystalline inclusions, loss of cristae and multilamellar membranes.^{63,64} Hepatocytes with megamitochondria with crystalline inclusions are distributed randomly among acinar zones in NASH.⁶⁵ This diffuse distribution indicates that mitochondrial structural abnormalities represent a generalized, most likely adaptive, response to oxidative stress and may not be the result of cell injury as previously thought.⁶⁶

2.2.7 Iron deposition

Iron deposition in periportal/periseptal hepatocytes and/or sinusoidal cells, when present, is mild (1+ or 2+ using Perls' histochemical stain) and it is reported in 15%-55% of cases in NASH studies.^{44,48,67,68} Increased iron deposition in NASH, detected by histochemical or biochemical methods, has been associated with increased portal-based fibrosis.⁶⁷ Studies on the relation of iron burden and HFE mutations with the development of liver fibrosis and pathogenesis of NASH show conflicting results.⁶⁹⁻⁷²

2.2.8 Glycogenated nuclei

Accumulation of glycogen in the nucleus of hepatocytes is a common finding in pediatric liver biopsies and in biopsies of adult liver with Wilson disease, diabetes and NAFLD.^{15,32} It has been shown that glycogenated nuclei are a more frequent finding in ASH compared to NASH.⁷³ In patients with NASH, nuclear vacuolization is correlated to the presence of diabetes and obesity.⁷⁴

2.3. Histological findings representing resolution of NASH

One of the goals of modern therapeutic trials in NASH is the resolution of the disease at tissue level. Comparison of entry liver biopsies of carefully selected patients with post-treatment biopsies allows the characterisation of histological findings that may represent resolution of NASH.¹⁵ Standardization of the morphological features denoting resolution will permit a uniform assessment of the therapeutic result in the growing number of trials using different agents. Furthermore, the issue of sampling variability that may affect the accuracy of histological results and the optimal size of the liver biopsy should be addressed.^{75,76}

Histological features that show improvement of the disease would ideally include decrease in global activity grade, improvement in the components of activity grade (steatosis, ballooning, lobular inflammation) and improvement in fibrosis stage. Promrat *et al*⁷⁷ in a pilot study of pioglitazone for 48 weeks, have set strict criteria to define histological response: reduction in NASH activity index by 3 points or more with improvements of at least 1 point each in steatosis, parenchymal inflammation and hepatocellular injury. Although in general, each of the components of the NASH activity index, fibrosis and number of Mallory bodies improved significantly post-treatment, only 12 out of 18 patients had a histological response.

In a recent trial using the PPAR-gamma ligand rosiglitazone for 48 weeks, decreased activity grade and improvement or no change of its components was noted in post-treatment biopsies. Other findings included a shift in the proportion of lobular and portal inflammation towards a greater portal component and a change in the quality of zone 3 perisinusoidal fibrosis from dense to delicate in one third of the cases.⁷⁸ Treatment of NASH patients with ursodeoxycholic acid for 2 years has shown no significant changes in the degree of steatosis, necroinflammation or fibrosis compared to the placebo group.⁷⁹ Interestingly, spontaneous regression of steatosis in a substantial number of NASH patients was noted in the placebo group of this trial. Treatment with vitamins E and C for 6 months, resulted in significant improvement in fibrosis score with no changes in inflammation,⁸⁰ while in a trial using an angiotensin II receptor antagonist for 48 weeks, improvement of necroinflammation, reduction of fibrosis and disappearance of iron deposition has been reported⁸¹ Weight loss resulted in major improvement in steatosis, necroinflammation and fibrosis in most obese patients with NASH following laparoscopic adjustable

gastric banding.⁸² Earlier treatment trials reported similar variable results probably because of differences in patient selection, agents used and therapeutic protocols (for a review see ref 15.)

2.4 Pathological features of NASH of diverse etiology

Some of the histological features that characterize NAFLD and NASH may be more prominent, while others may be differentially located in liver biopsies from patients with various underlying disorders. In patients with diabetes mellitus, glycogenated nuclei may be observed in up to 75% of the cases, fibrosis may initially involve zone 1 and Mallory's hyaline is more commonly detected in zone 1 hepatocytes.⁸³⁻⁸⁵ Perisinusoidal fibrosis in diabetic patients occurs in both type 1 and type 2 diabetes and may be related to diabetic microangiopathy.⁸⁶

The histological findings in the liver of obese patients have been described in many studies.^{34,35,40-43,87-91} In morbid obesity, sudden weight loss may result to NAFLD, characterized by mild portal inflammation and mild fibrosis,⁹⁰ while jejunioileal bypass may result to progressive liver injury aggravating preexisting lesions.^{40,88} In the latter, the proposed sequence of events is steatosis, lobular lymphocytic infiltration, pericellular fibrosis, Mallory's hyaline and progressive architectural changes.^{40,88} The prevalence of NASH in severely obese patients has been reported as high as 25% and it is more common in patients with diabetes and/or hypertension.⁹¹

In amiodarone-induced steatohepatitis, histology is more similar to ASH, with abundant Mallory's hyaline in periportal areas which may relate to disease severity.⁹²

2.5. Pathology of NAFLD and NASH in children

The incidence of NAFLD in children is increasing reflecting an increase in prevalence of childhood obesity.⁹³⁻⁹⁸ Male predominance, strong association with Hispanic ethnicity and insulin resistance characterize NAFLD in the pediatric population and it is of great importance to recognize that NASH in children may progress to cirrhosis.⁹⁴⁻⁹⁶

In obese children with NAFLD a distinctive histological feature is the predominance of portal-based chronic inflammation compared to the lobular mixed inflammation commonly seen in adult NAFLD.⁹⁹ Other features include more severe steatosis, less hepatocellular injury, frequent portal fibrosis, uncommon occurrence of Mallory's hyaline and lack of zone 3 predominance of the histologic lesions (for a review see ref. 15). The above findings characterize the pediatric-type of NAFLD his-

tology, while a histological pattern resembling adult NASH may be observed.¹⁵ The histological experience in pediatric NASH is still small compared with adult NASH and the results of recent morphological studies have shown that different histological criteria may be applied for the diagnosis of NASH in children.

2.6 NASH-related cirrhosis

Natural history studies have shown that steatosis without inflammation is relatively benign in NASH.^{16,100,101} However, NASH may progress to cirrhosis in up to 28% of the cases.¹⁶⁻²⁰ Abdelmalek *et al*¹⁰² have reported that biopsy-proven NASH may progress to cirrhosis without retaining any of the diagnostic histological features of steatohepatitis and it is now believed that NAFLD may account for a large proportion of “cryptogenic cirrhosis”.¹⁷ However, cases of NASH-cirrhosis may retain some or all of the diagnostic features of NASH.²⁵ Hui *et al*,¹⁸ have proposed pathologic criteria for the diagnosis of NASH-associated cirrhosis and categorized the disease in 4 groups: definite (steatosis with intralobular mixed inflammation), probable (steatosis with intralobular mononuclear inflammation), possible (with either steatosis only or mixed inflammation only), and cryptogenic (no steatosis, no inflammation).

NASH-related cirrhosis is an indication for liver transplantation and the number of patients transplanted for this reason is growing.^{16,68,103} There is indirect evidence to suggest that patients undergoing transplantation for NASH-cirrhosis may have poorer outcome, despite careful selection, due to co-morbid conditions related to the metabolic syndrome, like diabetes mellitus, hypertension, dyslipidemia and obesity.¹⁰³ Recurrence and de novo occurrence of NASH have been reported after transplantation^{104,105} Steatosis usually recurs within 5 years, but progression to fibrosis is rare in transplanted patients.¹⁰⁵

2.7. Grading and Staging NAFLD and NASH

A classification system correlating histological features of NAFLD with disease outcome has been proposed by Matteoni *et al*¹⁶ (Table 1). According to this system, NAFLD may be separated into four histologic subgroups based on the presence of steatosis (type 1), steatosis and lobular inflammation (type 2), steatosis and hepatocellular ballooning (type 3), and steatosis with ballooning and either Mallory’s hyaline or fibrosis (type 4). Types 3 and 4 NAFLD histologically and clinically resemble NASH.^{14,15}

A semi-quantitative system for grading the necroinflammatory activity and staging fibrosis based on the

major histopathological lesions of NASH has been proposed (Table 2).⁴⁸ It provides a method of deriving to a global activity grade from a combination and semi-quantification of steatosis, ballooning and inflammation and also a method of evaluating the pattern of fibrosis. The system is used mainly for research purposes in therapeutic trials of NASH assessing the efficacy of different agents and its value in routine practice has not been analyzed. It remains to be validated in prospective studies assessing the long-term outcome of the patients.

Recently, the NASH Clinical Research Network, a multi-center consortium sponsored by the National Institute of Diabetes and Digestive and Kidney Diseases to study the natural history and initiate therapeutic trials for NAFLD and NASH in adult and pediatric patients, proposed a scoring system for NAFLD and NASH based on the most important histological criteria.¹⁰⁶ The system confirms that a strict diagnosis of NASH correlates with the degree of steatosis, lobular inflammation, ballooning and the characteristic pattern of fibrosis. Regarding fibrosis, a slight modification from the previous system⁴⁸ was that stage 1 was further stratified in 3 groups: mild or moderate zone 3 perisinusoidal fibrosis, and portal fibrosis only (Table 3.).

3. DIFFERENTIAL DIAGNOSIS BETWEEN ALCOHOLIC AND NONALCOHOLIC FATTY LIVER DISEASE

The histopathological lesions that characterize NAFLD and NASH are similar to those observed in alcoholic liver disease (ALD).^{13,15,107} As a result, the interpretation of a liver biopsy without clinico-pathological correlation usually is not sufficient to differentiate between NASH and alcoholic steatohepatitis (ASH).³² However, there are histological features that are more specific to ALD than to NASH,^{108,109} such as sclerosing hyaline necrosis,¹¹⁰ lesions in the terminal hepatic venules and sub-lobular veins (perivenular fibrosis, phlebosclerosis and veno-occlusive lesions),¹¹¹ cholestatic features (ductular proliferation, cholangiolitis and acute cholestasis)^{108,109} and alcoholic foamy liver degeneration (microvesicular steatosis)^{108,111}

On the other hand, some histologic lesions are reported more frequently in NASH than ASH, such as periportal hepatocyte nuclear vacuolation (glycogenated nuclei: 76% vs 7%).⁷³ Generally, it is accepted that the overall histological picture of NASH is usually milder than that of ASH.³²

Table 2. Proposed grading and staging of NASH (modified from ref. 48)**GRADING****Grade 1, Mild**

Steatosis: predominantly macrovesicular, involves <33% up to 66% of the lobules

Ballooning: occasionally observed; zone 3 hepatocytes

Lobular Inflammation: scattered and mild acute (polymorphs) inflammation and occasional chronic (mononuclear cells) inflammation

Portal inflammation: none or mild

Grade 2, Moderate

Steatosis: any degree and usually mixed macrovesicular and microvesicular

Ballooning: obvious and present in zone 3

Lobular inflammation: polymorphs may be noted associated with ballooned hepatocytes, pericellular fibrosis; mild chronic inflammation may be seen

Portal inflammation: mild to moderate

Grade 3, Severe

Steatosis: typically >66% (panacinar); commonly mixed steatosis

Ballooning: predominantly zone 3; marked, Lobular inflammation: scattered acute and chronic inflammation; polymorphs may appear concentrated in zone 3 areas of ballooning and perisinusoidal fibrosis

Portal inflammation: mild or moderate

Steatosis: graded as 1= 0-33%, 2= 33%-66%, 3= >66%.

Ballooning: zonal location noted and severity (mild or marked) recorded according to estimate of numbers of hepatocytes involved

Lobular Inflammation: 0 – 3 based on observations of foci per 20x field:

1= 1-2 foci, 2= up to 4 foci, 3= > 4 foci.

In addition, cell types (acute or chronic) and location are noted.

Portal inflammation: 0-3, 1= mild, 2= moderate, 3= severe

STAGING

Stage 1: Zone 3 perivenular, perisinusoidal/pericellular fibrosis, focal or extensive

Stage 2: As above with focal or extensive periportal fibrosis

Stage 3: Bridging fibrosis, focal or extensive

Stage 4: Cirrhosis

4. PROGNOSTIC INFORMATION OF HISTOLOGICAL FEATURES OF NASH

Liver biopsy is currently accepted as the “gold standard” for differentiating NASH from simple NAFLD (types 1 and 2, according to Matteoni *et al*). However, clinicians are eager to develop non-invasive methods for accurately diagnosing NASH and predicting fibrosis in NAFLD patients mainly to eliminate patient discomfort, rare complications and expenses related to the performance of liver biopsy. Recently, transient elastography has been proposed as a promising non-invasive method for the assessment of hepatic fibrosis.¹¹² Scoring systems have been developed for obese patients based on clinical and laboratory data, like the HAIR (Hypertension, ALT,

Insulin Resistance) score to predict NASH development⁹¹ and the BAAT (BMI, ALT, Age, Triglycerides) score to predict advanced fibrosis³⁴. However, these are useful mainly for patient selection for liver biopsy. More recently, the combination of serum hyaluronate levels and serum carbohydrate-deficient transferrin/transferrin ratio has been proposed as a predictor of fibrosis in patients with features of the metabolic syndrome regardless of alcohol consumption.¹¹³ Measurement of serum adiponectin, which is a cytokine secreted by adipose tissue and may play a significant role in the progression of simple NAFLD to NASH,¹¹⁴ combined with insuline resistance tests holds promise for the future as a non-invasive method to identify patients with NASH.¹¹⁵ Furthermore, the combination of serum values of several adipokines

Table 3. NASH Clinical Research Network (NIH) Histologic Scoring system for NAFLD and NASH (Modified from ref. 107)

ACTIVITY SCORE

Steatosis + lobular inflammation + ballooning = 0-8

- Steatosis: 0: <5%; 1:5-33%; 2:>33-66%; 3:>66%
- Lobular inflammation: 0: none; 1:<2; 2:2-4; 3:>4 foci/20x
- Ballooned hepatocytes: 0: none; 1: few; 2: many/prominent

FIBROSIS (Modified Brunt criteria)

0: none

1: 1a mild zone 3 perisinusoidal fibrosis; 1b moderate zone 3 perisinusoidal fibrosis, 1c: portal fibrosis only

2: 1a/b with periportal fibrosis

3: bridging fibrosis, focal or extensive

4: cirrhosis

(i.e. adiponectin, resistin, leptin) has been reported to be predictive of histology in patients with NASH.¹¹⁶

Histological features of prognostic information for advanced fibrosis in NASH have been reported in various combinations in several studies, probably due to differing inclusion criteria and evaluation methods.^{34,35,49,67,117} These include extent of steatosis,^{34,49,67,117} severity of lobular inflammation,^{34,35,67} hepatocellular ballooning,³⁶ Mallory's hyaline^{34,36,67,117} and presence of stainable iron.⁶⁷

5. CONCURRENCE OF NAFLD WITH OTHER LIVER DISEASES

Since NAFLD is considered one of the most common causes of liver injury, an emerging area of clinical and pathological interest is the recognition of features of possible concurrent chronic liver disease in these patients.^{33,118} Careful histologic evaluation of a liver biopsy allows in many cases the determination of features that are indicative of more than one disease process.³² Macrovesicular steatosis, is known to occur in both steatohepatitis and chronic hepatitis C, but the extent and topography of this lesion is different in each disease.¹¹⁹ Features that are characteristic of chronic hepatitis C, like portal lymphoid aggregates are not seen in NAFLD. On the other hand, perisinusoidal fibrosis, a characteristic finding in NASH is not seen in hepatitis C.¹¹⁹ In a recent review, 2.6% of non-allograft liver biopsies showed concurrence of histological findings of steatohepatitis with another liver disease.³³ These were 5% of all hepatitis C biopsies and 4.3% of all other chronic liver diseases, including hemochromatosis, alpha1-antitrypsin deficiency and autoimmune hepatitis.³³

In chronic hepatitis C, the mechanisms for the development of steatosis are both host- and virus-related. The former, in non-3 HCV genotype infection, are similar to those accepted for NAFLD (metabolic steatosis), while the latter include a direct cytopathic effect of HCV genotype 3 (viral steatosis).^{120,121} In chronic hepatitis C, markers of obesity and HCV genotype 3 are associated with the extent of steatosis, while the grade of steatosis and presence of NASH are associated with advanced hepatic fibrosis.¹²²⁻¹²⁴ Current research is centered on evaluating the impact of NAFLD and its associated risk factors on the progression and treatment of chronic hepatitis C.

6. NOMENCLATURE OF NASH

The difficulties in differentiating between NASH and ASH at the histological level, the recognition that specific underlying disorders are associated with NAFLD and NASH, the acceptance that the criteria used for excluding use of alcohol are not strictly defined and the possible concurrence of steatohepatitis with other forms of chronic liver disease, have led hepatopathologists and clinicians to a reconsideration of the term “Nonalcoholic steatohepatitis”.^{2,5,14,82} The term “steatohepatitis” followed by the underlying clinical condition if provided (i.e. diabetes, obesity, hyperlipidemia etc) may be more appropriate to use in histopathological diagnosis.^{14,15,32}

7. CONCLUSIONS

NAFLD is currently considered the most common cause of chronic liver disease in the Western world and has been correlated with insulin resistance and the metabolic syndrome. The histological spectrum of NAFLD ranges from simple steatosis to NASH, with or without fibrosis, and cirrhosis. Liver biopsy remains today the “gold standard” for diagnosing NASH, assessing the extent of injury, excluding other liver disease, assessing lesions of possible prognostic significance and evaluating the response to therapy in clinical trials. Advances in the sensitivity of imaging studies, measurements of adipokine levels in the serum and increasing understanding of the role of genes in NAFLD may, in the future, lessen the necessity for a liver biopsy. Fields of ongoing investigation in NAFLD pathology are the refinement of the minimal morphological criteria that are necessary for diagnosis of NASH in adults and children, the assessment of NAFLD when co-existent with other types of chronic liver disease, the standardization of semiquantitative methods for histopathological evaluation of NASH

lesions and the evaluation of lesions indicating resolution of NASH following treatment.

REFERENCES

1. Angulo P. Nonalcoholic fatty liver disease. *N Engl J Med* 2002; 346: 1221-1231.
2. Neuschwander-Tetri BA, Caldwell SH. Nonalcoholic steatohepatitis: Summary of an AASLD Single Topic Conference. *Hepatology* 2003; 37: 1202-1219.
3. Harrison SA, Neuschwander-Tetri BA. Nonalcoholic fatty liver disease and nonalcoholic steatohepatitis. *Clin Liver Dis* 2004; 8: 861-879.
4. Clark JM, Brancati FL, Diehl AM. The prevalence and etiology of elevated aminotransferase levels in the United States. *Am J Gastroenterol* 2003; 98: 960-967.
5. Ruhl CE, Everhart JE. Epidemiology of non-alcoholic fatty liver. *Clin Liver Dis* 2004; 8: 501-519.
6. Sanyal AJ, Campbell-Sargent C, Mirshahi F, *et al.* Nonalcoholic steatohepatitis: Association of insulin resistance and mitochondrial abnormalities. *Gastroenterology* 2001; 120: 1183-1192.
7. Chitturi S, Abeygunasekera S, Farrell GC, *et al.* NASH and insulin resistance: Insulin hypersecretion and specific association with the insulin resistance syndrome. *Hepatology* 2002; 35: 373-379.
8. Marchesini G, Brizi M, Bianchi G, *et al.* Nonalcoholic fatty liver disease: a feature of the metabolic syndrome. *Diabetes* 2001; 50: 1844-1850.
9. Marchesini G, Bugianesi E, Forlani G, *et al.* Nonalcoholic fatty liver, steatohepatitis, and the metabolic syndrome. *Hepatology* 2003; 37: 917-923.
10. Marchesini G, Brizi M, Morselli-Labate AM, *et al.* Association of nonalcoholic fatty liver disease with insulin resistance. *Am J Med* 1999; 107: 450-455.
11. Pagano G, Pacini G, Musso G, *et al.* Nonalcoholic steatohepatitis, insulin resistance, and metabolic syndrome: further evidence for an etiologic association. *Hepatology* 2002; 35: 367-372.
12. Bugianesi E, Zannoni C, Vanni E, Marzocchi R, Marchesini G. Non-alcoholic fatty liver and insulin resistance: a cause-effect relationship? *Dig Liver Dis* 2004; 36: 165-173.
13. Burt AD, Mutton A, Day CP. Diagnosis and interpretation of steatosis and steatohepatitis. *Semin Liver Dis* 1998; 15: 246-258.
14. Brunt EM. Nonalcoholic steatohepatitis: Definition and pathology. *Semin Liver Dis* 2001; 21:3-16.
15. Brunt EM. Nonalcoholic steatohepatitis. *Semin Liver Dis* 2004; 24: 3-20.
16. Matteoni CA, Younossi ZM, Gramlich T, Boparai N, Liu YC, McCullough AJ. Nonalcoholic fatty liver disease: A spectrum of clinical and pathological severity. *Gastroenterology* 1999; 116: 1413-1419.
17. Caldwell SH, Crespo DM. A commentary to "The spectrum expanded: cryprogenic cirrhosis and the natural history of non-alcoholic liver disease" by Powell EE, Cooksley WGE, Hanson R, *et al.* *J Hepatol* 2004; 40: 578-584.
18. Hui JM, Kench JG, Chitturi S, *et al.* Long-term outcomes of cirrhosis in non-alcoholic steatohepatitis compared with hepatitis C. *Hepatology* 2003; 38: 420-427.
19. Fassio E, Alvarez E, Dominguez N, Landeira G, Longo C. Natural history of non-alcoholic steatohepatitis: a longitudinal study of repeat liver biopsies. *Hepatology* 2004; 40: 820-826.
20. Adams L, Lymp J, Sauver S, *et al.* The natural history of non-alcoholic fatty liver disease: A population based cohort study (Abstract). *Hepatology* 2004; 40: 582A.
21. Kim HJ, Kim HJ, Lee KE, *et al.* Metabolic significance of nonalcoholic fatty liver disease in nonobese, nondiabetic adults. *Arch Intern Med* 2004; 164: 2169-2175.
22. Mofrad P, Contos MJ, Haque M, *et al.* Clinical and histologic spectrum of nonalcoholic fatty liver disease associated with normal ALT values. *Hepatology* 2003; 37: 1286-1292.
23. Marrero JA, Fontana RJ, Su GL, Conjeevaram HS, Emick DM, Lok AS. NAFLD may be a common underlying liver disease in patients with hepatocellular carcinoma in the United States. *Hepatology* 2002; 36: 1349-1354.
24. Ratziu V, Bonyhay L, Di Martino V, *et al.* Survival, liver failure and hepatocellular carcinoma in obesity-related cryptogenic cirrhosis. *Hepatology* 2002; 35: 1485-1493.
25. Shimada M, Hashimoto E, Taniai M, *et al.* Hepatocellular carcinoma in patients with non-alcoholic steatohepatitis. *J Hepatol* 2002; 37: 154-160.
26. Mori S, Yamasaki T, Sakaida I, *et al.* Hepatocellular carcinoma with non-alcoholic steatohepatitis. *J Gastroenterol* 2004; 39: 391-396.
27. Hashimoto E, Taniai M, Kaneda H, *et al.* Comparison of hepatocellular carcinoma patients with alcoholic liver disease and non-alcoholic steatohepatitis. *Alcohol Clin Exp Res* 2004; 28(suppl. 8): 164S-168S.
28. Saadeh S, Younossi ZM, Remer EM, *et al.* The utility of radiological imaging in nonalcoholic fatty liver disease. *Gastroenterology* 2003; 123: 745-750.
29. Szczepaniak LS, Nurenberg P, Leonard D, *et al.* Magnetic Resonance Spectroscopy to measure hepatic triglyceride content: prevalence of hepatic steatosis in the general population. *Am J Physiol Endocrinol Metab* 2005; 288: E462-468.
30. Joy D, Thava VR, Scott BB. Diagnosis of fatty liver disease: is biopsy necessary? *Eur J Gastroenterol Hepatol* 2003; 15: 539-543.
31. Shalhub S, Parsee A, Gallagher SF, *et al.* The importance of routine liver biopsy in diagnosing non-alcoholic steatohepatitis in bariatric patients. *Obes Surg* 2004; 14: 54-59.
32. Brunt EM, Tiniakos DG. Pathology of steatohepatitis. *Best Pract Res Clin Gastroenterol* 2002; 16: 691-707.
33. Brunt EM, Ramrakhiani S, Cordes BG, *et al.* Concurrence of histologic features of steatohepatitis with other forms of chronic liver disease. *Mod Pathol* 2003; 16: 49-56.
34. Ratziu V, Giral P, Charlotte F, *et al.* Liver fibrosis in overweight patients. *Gastroenterology* 2000; 118: 1117-1123.
35. Garcia-Monzon C, Martin-Perez E, Iacono OL, *et al.* Characterization of pathogenic and prognostic factors of

- nonalcoholic steatohepatitis associated with obesity. *J Hepatol* 2000; 33: 716-724.
36. Gramlich T, Kleiner DE, Mc Cullough AJ, Matteoni C, Boparai N, Younossi ZM. Pathologic features associated with fibrosis in nonalcoholic fatty liver disease. *Hum Pathol* 2004; 35: 196-199.
 37. Connor CL. Fatty infiltration of liver and development of cirrhosis in diabetes and chronic alcoholics. *Am J Pathol* 1938; 14: 347.
 38. Westwater JO, Fainer D. Liver impairment in the obese. *Gastroenterology* 1958; 34: 686-693.
 39. Thaler H. The fatty liver and its pathogenetic relation to liver cirrhosis. *German. Virchows Arch Pathol Anat Physiol Klin Med* 1962; 335: 180-210.
 40. Peters RL, Gay T, Reynolds TB. Post-jejunoileal bypass hepatic disease. Its similarity to alcoholic hepatic disease. *Am J Clin Pathol* 1975; 63: 318-331.
 41. Adler M, Schaffner F. Fatty liver hepatitis and cirrhosis in obese patients. *Am J Med* 1979; 67: 811-816.
 42. Nasrallah SM, Wills CE, Galambos JT. Hepatic morphology in obesity. *Dig Dis Sci* 1981; 26: 325-327.
 43. Silverman JF, O'Brien KF, Long S, *et al.* Liver pathology in morbidly obese patients with and without diabetes. *Am J Gastroenterol* 1990; 85: 1349-1355.
 44. Ludwig J, Viggiano TR, McGill DB, Oh BJ. Nonalcoholic steatohepatitis: Mayo Clinic experiences with a hitherto unnamed disease. *Mayo Clin Proc* 1980; 55: 434-438.
 45. McCullough AJ. Update on nonalcoholic fatty liver disease. *J Clin Gastroenterol* 2002; 34: 255-262.
 46. Falck-Ytter Y, Younossi ZM, Marchesini G, McCullough AJ. Clinical features and natural history of nonalcoholic steatosis syndromes. *Semin Liver Dis* 2001; 21: 17-26.
 47. Youssef WI, McCullough AJ. Diabetes mellitus, obesity, and hepatic steatosis. *Semin Gastrointest Dis* 2002; 13: 17-30.
 48. Brunt EM, Janney CG, Di Bisceglie AM, Neuschwander-Tetri BA, Bacon BR. Nonalcoholic steatohepatitis: A proposal for grading and staging the histological lesions. *Am J Gastroenterol* 1999; 94: 2467-2474.
 49. Angulo P, Keach JC, Batts KP, Lindor KD. Independent predictors of liver fibrosis in patients with nonalcoholic steatohepatitis. *Hepatology* 1999; 30: 1356-1362.
 50. Vuppalanchi R, Matsumoto M, Cummings OW, *et al.* Histological grading of hepatic steatosis by pathologists does not correlate with hepatic triglyceride content (Abstract) *Hepatology* 2004; 40: 985.
 51. Caldwell SH, Chang C, Krugner-Higby LA, Redick JA, Davis CA, Al-Osaimi AMS. The ballooned hepatocyte in NAFLD: Degenerative or adaptive? (abstract) *J Hepatol* 2004; 40(suppl 1): 168.
 52. Feldstein AE, Canbay A, Angulo P, *et al.* Hepatocyte apoptosis and fas expression are prominent features of human nonalcoholic steatohepatitis. *Gastroenterology* 2003; 125: 437-443.
 53. Ribeiro PS, Cortez-Pinto H, Sola S, *et al.* Hepatocyte apoptosis, expression of death receptors, and activation of NF-kappaB in the liver of non-alcoholic and alcoholic steatohepatitis patients. *Am J Gastroenterol* 2004; 99: 1718-1719.
 54. Natori S, Rust C, Stadheim LM, Srinivasan A, Burgart LJ, Gores GJ. Hepatocyte apoptosis is a pathologic feature of human alcoholic hepatitis. *J Hepatol* 2001; 34: 248-253.
 55. Ziol M, Tepper M, Lohez M, *et al.* Clinical and biological relevance of hepatocyte apoptosis in alcoholic hepatitis. *J Hepatol* 2001; 34: 254-260.
 56. Abrams GA, Kunde SS, Lazenby AJ, Clements RH. Portal fibrosis and hepatic steatosis in morbidly obese subjects: a spectrum of non-alcoholic fatty liver disease. *Hepatology* 2004; 40: 475-483.
 57. Washington K, Wright K, Shyr Y, Hunter EB, Olson S, Raiford DS. Hepatic stellate cell activation in nonalcoholic steatohepatitis and fatty liver. *Hum Pathol* 2000; 31: 822-828.
 58. Cortez-Pinto H, Baptista A, Camilo ME, deMoura MC. Hepatic stellate cell activation occurs in nonalcoholic steatohepatitis. *Hepato-Gastroenterol* 2001; 48: 87-90.
 59. Feldstein AE, Papuchado BG, Angulo P, Sanderson S, Adams L, Gores GJ. Hepatic stellate cell activation score predicts fibrosis progression in patients with nonalcoholic fatty liver disease. (Abstract) *Hepatology* 2004; 40: 76.
 60. Denk H, Stumtner C, Zatloukal K. Mallory bodies revisited. *J Hepatol* 2000; 32: 689-702.
 61. Muller T, Langner C, Fuchsbichler A, *et al.* Immunohistochemical analysis of Mallory bodies in Wilsonian and non-Wilsonian hepatic copper toxicosis. *Hepatology* 2004; 39: 963-969.
 62. Zatloukal K, Stumtner C, Fuchsbichler A, *et al.* The keratin cytoskeleton in liver diseases. *J Pathol* 2004; 204: 367-376.
 63. Caldwell SH, Swerdlow RH, Khan EM, *et al.* Mitochondrial abnormalities in non-alcoholic steatohepatitis. *J Hepatol* 1999; 31: 430-434.
 64. Sanyal AJ, Campbell-Sargent C, Mirshahi F, *et al.* Nonalcoholic steatohepatitis: association of insulin resistance and mitochondrial abnormalities. *Gastroenterology* 2001; 120: 1183-1192.
 65. Le TH, Caldwell SH, Redick JA, *et al.* The zonal distribution of megamitochondria with crystalline inclusions in nonalcoholic steatohepatitis. *Hepatology* 2004; 39: 1423-1429.
 66. Caldwell SH, Chang CY, Nakamoto RK, Krugner-Higby L. Mitochondria in non-alcoholic fatty liver disease. *Clin Liver Dis* 2004; 8: 595-617.
 67. George DK, Goldwurm S, MacDonald GA, *et al.* Increased hepatic iron concentration in nonalcoholic steatohepatitis is associated with increased fibrosis. *Gastroenterology* 1998; 114: 311-318.
 68. Bacon BR, Farahvash MJ, Janney CG, Neuschwander-Tetri BA. Nonalcoholic steatohepatitis - an expanded clinical entity. *Gastroenterology* 1994; 107: 1103-1109.
 69. Younossi ZM, Gramlich T, Bacon BR, *et al.* Hepatic iron and nonalcoholic fatty liver disease. *Hepatology* 1999; 30: 847-850.
 70. Bonkovsky HL, Jawaid Q, Tortorelli K, *et al.* Non-alcoholic steatohepatitis and iron: increased prevalence of mutations of the HFE gene in non-alcoholic steatohepatitis.

- J Hepatol 1999; 31: 421-429.
71. Chitturi S, Weltman M, Farrell GC, *et al.* Mutations, hepatic iron, and fibrosis: Ethnic-specific association of NASH with C282Y but not with fibrotic severity. *Hepatology* 2002; 36: 142-149.
 72. Bugianesi E, Manzini P, D'Antico S, *et al.* Relative contribution of iron burden, HFE mutations and insulin resistance to fibrosis in non-alcoholic fatty liver. *Hepatology* 2004; 39: 179-187.
 73. Itoh S, Yougel, Kawagoe K. Comparison between non-alcoholic steatohepatitis and alcoholic hepatitis. *Am J Gastroenterol* 1987; 82: 650-654.
 74. Cortez-Pinto H, Baptista A, Camilo ME, Valente A, Saragoca A, DeMoura MC: Nonalcoholic steatohepatitis - clinicopathological comparison with alcoholic hepatitis in ambulatory and hospitalized patients. *Dig Dis Sci* 1996; 41: 172-179.
 75. Abrams GA, Jhala N, Lazenby AJ, *et al.* Comparison of paired liver biopsies in morbidly obese subjects with non-alcoholic fatty liver disease. *Gastroenterology* 2004; 126: A755.
 76. Ratziu V, Charlotte F, Heurtier A, *et al.* High sampling variability of percutaneous liver biopsy in non-alcoholic fatty liver disease. *Hepatology* 2004; 40: 237A.
 77. Promrat K, Lutchman G, Uwaifo GI, *et al.* A pilot study of pioglitazone treatment for non-alcoholic steatohepatitis. *Hepatology* 2004; 39: 188-196.
 78. Newschwander-Tetri BA, Brunt EM, Wehmeier KR, Oliver D, Bacon BR. Improvement in nonalcoholic steatohepatitis following 48 weeks of treatment with the PPAR-g ligand rosiglitazone. *Hepatology* 2003; 38: 1008-1017.
 79. Lindor KD, Kowdley KV, Heathcote EJ, *et al.* Ursodeoxycholic acid for treatment of nonalcoholic steatohepatitis: results of a randomized trial. *Hepatology* 2004; 39: 770-778.
 80. Harrison SA, Torgerson S, Hayashi P, Ward J, Schenker S. Vitamin E and Vitamin C treatment improves fibrosis in patients with nonalcoholic steatohepatitis. *Am J Gastroenterol* 2003; 98: 2485-2490.
 81. Yokohama S, Yoneda M, Haneda M, *et al.* Therapeutic efficacy of an angiotensin II receptor antagonist in patients with nonalcoholic steatohepatitis. *Hepatology* 2004; 40: 1222-1225.
 82. Dixon JB, Bhathal PS, Hughes NR, O'Brien PE. Nonalcoholic fatty liver disease: Improvement in liver histological analysis with weight loss. *Hepatology* 2004; 39: 1647-1654.
 83. Nagore N, Scheuer PJ. The pathology of diabetic hepatitis. *J Pathol* 1988; 156: 155-160.
 84. Stone BG, Van Thiel DH. Diabetes mellitus and the liver. *Semin Liver Dis* 1985; 5: 8-28.
 85. Falchuk KR, Conlin D. The intestinal and liver complications of diabetes mellitus. *Adv Intern Med* 1993; 38: 269-286.
 86. Latry P, Bioulac-Sage P, Echinard E, *et al.* Perisinusoidal fibrosis and basement membrane-like material in the livers of diabetic patients. *Hum Pathol* 1987; 18: 775-780.
 87. Marubbio AT, Buchwald H, Schwartz MZ, Varco R. Hepatic lesions of central pericellular fibrosis in morbid obesity and after jejunioleal bypass. *Am J Clin Pathol* 1976; 66: 684-691.
 88. Vyberg M, Ravn V, Andersen B. Pattern of progression in liver injury following jejunioleal bypass for morbid obesity. *Liver* 1987; 7: 271-276.
 89. Wanless IR, Lentz JS. Fatty liver hepatitis (steatohepatitis) and obesity: An autopsy study with analysis of risk factors. *Hepatology* 1990; 12: 1106-1110.
 90. Andersen T, Gluud C, Franzmann MB, *et al.* Hepatic effects of dietary weight loss in morbidly obese subjects. *J Hepatol* 1991; 12: 224-229.
 91. Dixon JB, Bhatal PS, O'Brien PE. Nonalcoholic fatty liver disease: predictors of non-alcoholic steatohepatitis and liver fibrosis in the severely obese. *Gastroenterology* 2001; 121: 91-100.
 92. Lewis JH, Mullick F, Ishak KG, *et al.* Histopathologic analysis of suspected amiodarone hepatotoxicity. *Hum Pathol* 1990; 21: 59-67.
 93. Manton ND, Lipsett J, Moore DJ, Davidson GP, Bourne AJ, Couper RT. Non-alcoholic steatohepatitis in children and adolescents. *Med J Austr* 2000; 173: 476-479.
 94. Roberts EA. Nonalcoholic steatohepatitis in children. *Curr Gastroenterol Rep* 2003; 5: 253-259.
 95. Schwimmer JB, Deutsch R, Rauch JB, Behling C, Newbury R, Lavine JE. Obesity, insulin resistance, and other clinicopathological correlates of pediatric non-alcoholic fatty liver disease. *J Pediatr* 2003; 143: 500-505.
 96. Lavine JE, Schwimmer JB. Nonalcoholic fatty liver disease in the pediatric population. *Clin Liver Dis* 2004; 8: 549-558.
 97. Weiss R, Dziura J, Burgert TS, *et al.* Obesity and the metabolic syndrome in children and adolescents. *New Engl J Med* 2004; 350: 2362-237.
 98. Marion AW, Baker AJ, Dhawan A. Fatty liver disease in children. *Arch Dis Child* 2004; 89: 648-652.
 99. Schwimmer JB, Behling C, Newbury R, *et al.* The histological features of pediatric fatty liver disease. *Hepatology* 2002; 36(suppl 1): 412A.
 100. Teli MR, James OFW, Burt AD, Bennett MK, Day CP. The natural history of nonalcoholic fatty liver: A follow-up study. *Hepatology* 1995; 22: 1714-1719.
 101. Dam-Larsen S, Franzman M, Andersen IB, *et al.* Long-term prognosis of fatty liver: risk of chronic liver disease and death. *Gut* 2004; 53: 750-755.
 102. Abdelmalek M, Ludwig J, Lindor KD. Two cases from the spectrum of nonalcoholic steatohepatitis. *J Clin Gastroenterol* 1995; 20: 127-130.
 103. Burke A, Lucey MR. Non-alcoholic fatty liver disease, non-alcoholic steatohepatitis and orthotopic liver transplantation. *Am J Transplant* 2004; 4: 686-693.
 104. Kim WR, Poterucha JJ, Porayko MK, Dickson ER, Steels JL, Wiesner RH. Recurrence of non-alcoholic steatohepatitis following liver transplantation. *Transplantation* 1996; 62: 1802-1805.
 105. Contos MJ, Cales W, Sterling RK, *et al.* Development of nonalcoholic fatty liver disease after orthotopic liver transplantation for cryptogenic cirrhosis. *Liver Transpl* 2001; 7: 363-373.

106. Kleiner DE, Brunt EM, Van Natta ML, *et al.* Design and validation of a histologic scoring system for non-alcoholic fatty liver disease (NAFLD) and non-alcoholic steatohepatitis. *Hepatology* 2003; 38(suppl 1): 160.
107. Brunt EM. Alcoholic and nonalcoholic steatohepatitis. *Clin Liver Dis* 2002; 6: 399-420.
108. French SW, Nash J, Shitabata P, *et al.* Pathology of alcoholic liver disease. *Semin Liv Dis* 1993; 13: 154-169.
109. Baptista A, Bianchi L, de Groote J, *et al.* Alcoholic liver disease: morphological manifestations. Review by an international group. *Lancet* 1981; 1: 707-711.
110. Burt AD, MacSween RNM. Hepatic vein lesions in alcoholic liver disease: retrospective biopsy and necropsy study. *J Clin Pathol* 1986; 39: 63-67.
111. MacSween RNM, Burt AD. Histologic spectrum of alcoholic liver disease. *Semin Liv Dis* 1986; 6:221-232.
112. Sandrin L, Fourquet B, Hasquenoph JM, *et al.* Transient elastography: a new noninvasive method for assessment of hepatic fibrosis. *Ultrasound Med Biol* 2003; 29: 1705-1713.
113. Laine F, Bendavid C, Moirand R, *et al.* Prediction of liver fibrosis in patients with features of the metabolic syndrome regardless of alcohol consumption. *Hepatology* 2004; 39: 1639-1646.
114. Czaja MJ. Liver injury in the setting of steatosis: cross-talk between adipokine and cytokine: *Hepatology* 2004; 40: 19-22.
115. Hui JM, Farrell GC, Kench JG, Kriketos A, George J. Beyond insulin resistance in NASH: TNF-alpha or adiponectin? *Hepatology* 2004; 40: 46-54.
116. Gawrieh S, Rosado B, Lindor K, Charlton MR. Adipokine levels are predictive of histology in patients with non-alcoholic fatty liver disease. *Hepatology* 2004; 40: 237A.
117. Shimada M, Hashimoto E, Kaneda H, Noguchi S, Hayashi N. Nonalcoholic steatohepatitis: risk factors for liver fibrosis. *Hepatol Res* 2002; 24: 429-438.
118. Clouston AD, Powell EE. Interaction of non-alcoholic fatty liver disease with other liver diseases. *Best Pract Res Clin Gastroenterol* 2002; 16: 767-781.
119. Scheuer PJ, Ashrafzadeh P, Sherlock S, Brown D, Dush-eiko GM. The pathology of hepatitis C. *Hepatology* 1992; 15: 567-571.
120. Brunt EM, Tiniakos DG. Steatosis, steatohepatitis: review of effects on chronic hepatitis C. *Curr Hepatitis Rep* 2002; 1: 38-44.
121. Negro F. Hepatitis C virus and liver steatosis: when fat is not beautiful. *J Hepatol* 2004; 40: 533-535.
122. Ong JP, Younossi ZM, Speer C, Olano A, Gramlich T, Boparai N. Chronic hepatitis C and superimposed nonalcoholic fatty liver disease. *Liver* 2001; 21: 266-271.
123. Younossi ZM, McCullough, AJ, Ong JP, *et al.* Obesity and non-alcoholic fatty liver disease in chronic hepatitis C. *J Clin Gastroenterol* 2004; 38: 705-709.
124. Hu KQ, Kyulo NL, Esraïlian E, *et al.* Overweight and obesity, hepatic steatosis, and progression of hepatitis C: a retrospective study on a large cohort of patients in the United states. *J Hepatol* 2004; 40: 147-154.