

Case report

Isolated Gastric Varices Resulting from Splenic Vein Thrombosis due to Inherited Thrombophilia: Report of a Case

V. Valatas¹, V. Balatsos¹, V. Delis¹, A. Hatzinikolaou¹, E. Felekouras², N. Skandalis¹

SUMMARY

Isolated gastric varices mainly occur in individuals with segmental sinistral portal hypertension, arising from pathology of the splenic vein, such as thrombosis or stenosis. We present a patient with acute upper gastrointestinal bleeding from isolated gastric varices in the absence of liver or pancreatic pathology. PHT was caused by thrombosis of the splenic vein due to a hereditary coagulation disorder. His condition was attributed to Leiden thrombophilia combined with increased plasma levels of factor VIII. Initial and subsequent management are presented.

Key Words: Isolated gastric varices, Leiden thrombophilia, Factor VIII, Injection sclerotherapy, Sugiura procedure

INTRODUCTION

Gastric varices (GV) are less common than esophageal varices (EV). They occur in approximately 20% of patients with portal hypertension (PHT). They are the cause of substantial morbidity and mortality and therefore they pose difficult challenges to the physician managing such patients. Although GV bleed less frequently than EV, bleeding tends to be more severe, to require more transfusions, and to have a higher mortality rate than EV bleeding. After control of acute bleeding, GV have a high rebleeding rate of 34% to 89%.¹

¹Department of Gastroenterology, "G. Gennimatas" General Hospital, Athens, Greece, ²First Department of Surgery, University of Athens Medical School, LAIKON General Hospital, Athens, Greece.

Author for correspondence:

Vassilios Balatsos, Department of Gastroenterology, "G. Gennimatas" General Hospital, Mesogion 154 Av., GR-11527, Athens, Greece, Phone: +30 2107792846, FAX: +30 2107792846, e-mail: vasibal@otenet.gr, valatas@med.uoc.gr

Segmental PHT resulting from splenic vein occlusion through thrombosis or, less commonly, stenosis, often as a sequel of pancreatic pathology, leads to the formation of isolated GV (IGV). In segmental portal hypertension, blood flows retrogradely through the short and posterior gastric veins and the gastroepiploic veins resulting in the formation of GVs. From the GV, blood flows hepatopetally through the left and right gastric veins to the portal vein. According to the classification of Sarin et al isolated GV (IGV) occurring in the absence of EV have been classified into 2 groups: (1) type 1 IGV (IGV1): varices located in the fundus and (2) type 2 IGV (IGV2): ectopic varices in the antrum, corpus, pylorus which also include the duodenal varices.²

Few studies have prospectively examined the risk for bleeding and mortality from GV.^{3,4} The overall frequency of variceal rupture is similar or less for gastric versus esophageal varices. In one study, the 2-year risk for bleeding from GV was 25%,⁵ which is similar to the 20% to 0% two-year risk for bleeding from EV.^{6,7} This may be because of the lesser risk of bleeding from varices involving the gastric lesser curvature and cardia. Fundal varices however may represent a distinct clinical entity with a rate of hemorrhage comparable or even larger than that of EV. Kim et al have shown that the cumulative bleeding rate of fundal varices at 1, 3, and 5 years was, respectively, 16%, 36%, and 44%,⁸ whereas in the case of fundal IGV a bleeding incidence as high as 78% has been reported.⁹ As a result, the optimal acute or long-term management of patients with GV is not yet fully determined due to lack of randomised control trials which deal with this issue.^{10,11} Nevertheless, endoscopic variceal obliteration therapy has emerged as the initial treatment of choice for acute GV bleeding and for secondary eradication of GV.^{12,13} The associated segmental portal hypertension has been effectively treated with splenectomy, splenic artery emboli-

zation or by stenting of the splenic vein in the case of splenic vein stenosis.¹⁴⁻¹⁷

We describe a patient with acute upper gastrointestinal (GI) bleeding from isolated gastric varices in the absence of liver or pancreatic pathology. Splenic vein thrombosis due to a combined thrombophilic disorder was detected as the cause of this patient's condition. Initial and subsequent therapeutic management is presented.

CASE REPORT

A 56 years old sailor was urgently admitted to our hospital due to hematemesis. On admission he was pale, with slight tachycardia (110beats/min), normotensive with a blood pressure of 130 mmHg systolic and he had normal temperature (36.6°C). The patient was obese and had no signs of advanced liver disease including ascites, hepatic encephalopathy and jaundice or spider angiomas. From the examination of the abdomen he had a palpable liver, which was not tender and an enlarged spleen. The patient was a heavy smoker (100pack-years) and reported moderate consumption of alcohol.

He had previously experienced two episodes of variceal bleeding the first one 14 months ago when he received appropriate hemodynamic resuscitation and acute bleeding was controlled by pharmacological treatment. One year before admission, the patient underwent a Transjugular Intrahepatic Portosystemic Shunt (TIPS) in a private hospital in Athens Greece (Fig. 1) because of a second episode of upper GI bleeding due to isolated gastric varices diagnosed by upper GI endoscopy. The pre-TIPS laboratory investigations at that time had showed no evidence of chronic liver disease. Serum biochemistry was normal, albumin and gamma-globulins were normal, there was no coagulopathy and serological markers of hepatitis viruses were negative, including HBV, HCV and HIV testing. A liver biopsy performed one month post TIPS showed no evidence of ongoing liver inflammation or fibrosis. On regular follow-up by Doppler ultrasonography occlusion of the TIPS was evident as early as one month following placement.

The patient had no family history suggestive of inherited liver disorder or thrombophilia. On the emergency laboratory investigation the patient had a hematocrit of 25.3 %, hemoglobin level of 8.0 gr/dl, white blood count of $9800 \times 10^3/\mu\text{l}$ and a marginally low platelet count of $157 \times 10^3/\mu\text{l}$. Coagulation studies were normal as well as his liver function tests and albumin level.

Following resuscitation, urgent endoscopy revealed

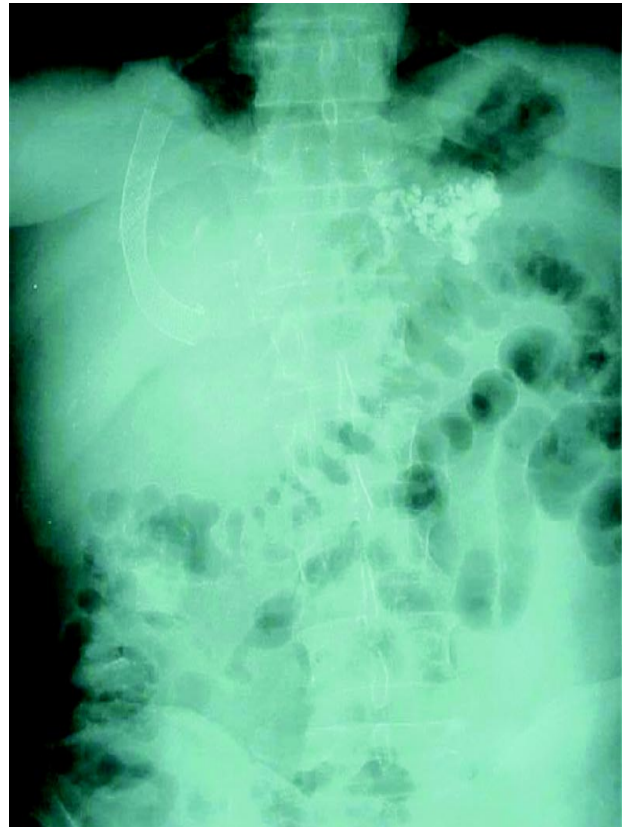

Fig. 1. Abdominal X-ray of the patient following emergency endoscopy that shows deposits of n-butyl-2-cyanoacrylate (Histoacryl) and lipiodol solution in gastric varices. The TIPS stent is also obvious at the right upper quadrant

two large type 1 isolated gastric varices in the fundus with red color spots. A small type 2 isolated gastric varix was also found in the first part of the duodenum. There was no other evident source of bleeding. Gastric varices were eradicated by injection with n-butyl-2-cyanoacrylate (Histoacryl) solution (Fig. 1). He was started on continuous somatostatin infusion and antibiotic prophylaxis. During his hospitalization the patient was hemodynamically stable and there were no symptoms or signs of recurrent hemorrhage.

Abdominal Doppler ultrasonography revealed an enlarged spleen 16.5cm, and an enlarged fatty liver (diameter of the right lobe 16.5cm). The diameter of the portal vein was 11mm. The TIPS stent was in place but with no flow. MRI angiography followed by conventional angiography revealed patent superior mesenteric and portal veins but an occluded splenic vein. Multiple aneurysms of the splenic artery and a bigger one at the origin of the Celiac axis were discovered on angiogram (Fig. 2). On thrombophilia screen the patient had increased

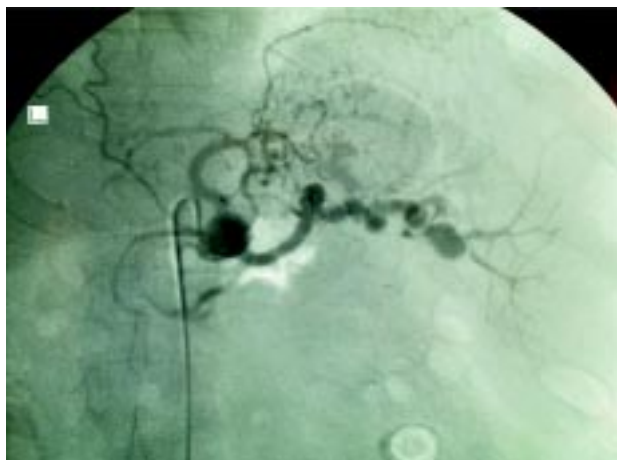


Fig. 2. Conventional angiography showing multiple microaneurysms of the splenic artery and occlusion of the splenic vein.

resistance to activated protein C and was found to be heterozygous for the 1691 G to A mutation of the gene encoding factor V resulting in Leiden thrombophilia. Additionally, he had increased levels of factor VIII (Table 1). Anticardiolipin antibodies, hemolysis, hyperhomocysteinemia and paroxysmal nocturnal haemoglobinuria screen were normal or negative. The patient was found to be a heterozygote for the factor V Leiden mutation and additionally had increased plasma levels of factor VIII. The patient was offered anti-coagulation treatment with warfarin, which he was advised to continue for life.

Finally, in order to prevent rebleeding the patient was referred for further surgical treatment. Because of left side portal hypertension (splenic vein thrombosis) a modified Sugiura procedure was performed which included splenectomy, esophagogastric devascularization, and esophageal disconnection with vagal preservation. In addition splenic artery was removed and the celiac axis aneurysm was resected with primary reanastomosis of the celiac artery to supraceliac aorta. The patient was dis-

charged on the 12th postoperative day on oral anticoagulants in good condition and his was doing fine on subsequent follow-ups.

DISCUSSION

We describe a patient with acute upper GI bleeding from isolated gastric varices caused by thrombosis of the splenic vein due to a hereditary coagulation disorder. Initial treatment consisted of effective resuscitation and endoscopic variceal obliteration therapy. Subsequently the patient's underwent a modified Sugiura procedure for the long-term management of segmental PHT. The patient's associated thrombophilic disorder and treatment options are discussed.

For the specific patient the prior use of TIPS to control acute variceal bleeding was absolutely contraindicated. Up to now and according to British Society of Gastroenterology guidelines for the management of variceal haemorrhage, TIPS or shunt surgery represent second-line therapy for the control of acute GV bleeding when standard endoscopic measures have failed. However, their use is not recommended in the absence of clinical or laboratory indications of cirrhosis even in the settings of acute refractory bleeding.¹⁸ Furthermore, previous studies have shown that stent insufficiency occurs frequently in 30% to 80% and 47% to 90% of patients by 1 and 2 years post-TIPS, respectively.¹⁹⁻²¹ In this patient the thrombosis of the stent occurred immediately after placement and to our opinion this is probably due to his underlying hypercoagulation defect.

Specifically the patient had activated protein C (APC) resistance, which is one of the most common inherited disorders of thrombophilia, accounting for almost 20% of cases of venous thrombosis.²² The prevalence of factor V Leiden, the primary cause of APC resistance, is highest in European populations at approximately 2% to 7%.²³ In 95% of cases, APC resistance is caused by a point mutation in the factor V gene, resulting in the substitution of a G for an A at position 506, which gives rise to factor Leiden. This mutation changes one of three APC cleavage sites in the heavy chain of factor Va, leading to decreased proteolytic inactivation of factor Va and, consequently, increased thrombin generation.²⁴ In the Leiden Thrombophilia Study (case-matched, controlled study), the estimated relative risk (RR) for venous thrombosis was 6 to 8 for heterozygotes,²⁵ and 80 for homozygotes for factor V Leiden.²⁶

Furthermore, our patient also had persistently increased levels of factor VIII, which were detected on both

Table 1. Patient's thrombophilia screen

Protein C (normal range: 70-140%)	77%
Protein S (normal range: 100%)	100%
Antithrombin III (normal range: 80-120%)	96%
Factor VIII	181%
Factor IX	81%
APC resistance	Positive
Factor V 1691 G to A	Positive
Factor II 20210 G to A	Negative

occasions one month and six months after his admission. The prevalence of persistently elevated factor VIII levels is 25% among patients with venous thrombosis versus 11% in healthy control subjects.²⁷ Factor VIII is a procofactor that accelerates the activation of factor X by factor IXa. The pathogenesis of elevated factor VIII levels and venous thrombosis is unclear. One possible mechanism is that elevated factor VIII levels increase the rate of thrombin formation. Another possible mechanism whereby elevated factor VIII levels could lead to an increased risk of thrombosis is by causing an acquired resistance to APC.²⁸ Elevated factor VIII concentrations (>150 IU/dL) were found to be an independent risk factor for venous thrombosis in the Leiden Thrombophilia Study, with an adjusted RR of 4.8.²⁹

Recent studies suggest that up to 60% of Leiden carriers may have more than one concomitant thrombophilic disorders. The commonest concomitant disorder found is the increased levels of factor VIII. Coexistence of both defects increases the annual incidence of venous thromboembolism from 0.09 in carriers without increased VIII levels to 0.35 in carriers with increase factor VIII levels.³⁰ It seems that the clinical expression of factor V Leiden may depend on co-segregation of more than one thrombophilic disorders.³¹

An interesting finding was the existence of multiple aneurysms of the splenic artery and the celiac axis. Histological examination showed that they were truly atherosclerotic. We believe that their existence rather represents an incidental finding. However, it would be tempting to speculate that they may have contributed to the development of thrombosis in such an uncommon site as the splenic vein as previously reported.³²

There is considerable lack of evidence concerning duration of treatment with oral coagulation for such patients. The decision depends on the severity of the initial episode of thrombosis as well as the risk of recurrent thromboembolism contrasted to the risk of severe bleeding due to anticoagulation. The annual incidence of serious bleeding complications associated with anticoagulant therapy ranges from 1 to 2 percent, a value that decreases over time during the course of treatment and that increases with age. Approximately 25 percent of severe hemorrhagic complications are fatal.³³ The risk of recurrent thrombosis depends on the presence of acquired or congenital risk factors and declines over time. Roughly, 5 percent of the recurrences are fatal.³⁴ Using these numbers, one could calculate that long-term oral anticoagulation would benefit the subgroups of patients in which the annual incidence of recurrence is above 10 percent.

Among patients with high factor VIII levels combined with factor Leiden the risk of recurrence has not been calculated but must be higher than 10 percent per year.³⁵ Furthermore, the severity of this first episode of venous thrombosis favors prolonged anticoagulation therapy to be offered to this patient. Prospective trials are needed to investigate the value of prolonged anticoagulant therapy in patients with such a combined disorder, but until these data are in hand, we believe that extended prophylaxis must be considered after a single severe episode of spontaneous venous thromboembolism in such patients.

REFERENCES

1. Ryan BM, Stockbrugger RW, Ryan JM. A pathophysiologic, gastroenterologic, and radiologic approach to the management of gastric varices. *Gastroenterology*. 2004; 126: 1175-1189.
2. Sarin SK, Jain AK, Lamba GS, et al. Isolated gastric varices: prevalence, clinical relevance and natural history. *Dig Surg*. 2003; 20: 42-47.
3. Sarin SK, Lahoti D, Saxena SP, et al. Prevalence, classification and natural history of gastric varices: a long-term follow-up study in 568 portal hypertension patients. *Hepatology*. 1992; 16: 1343-1349.
4. Korula J, Chin K, Ko Y, et al. Demonstration of two distinct subsets of gastric varices. Observations during a seven-year study of endoscopic sclerotherapy. *Dig Dis Sci*. 1991; 36: 303-309.
5. Sarin SK, Lahoti D, Saxena SP, et al. Prevalence, classification and natural history of gastric varices: a long-term follow-up study in 568 portal hypertension patients. *Hepatology*. 1992; 16: 1343-1349.
6. D'Amico G, Pagliaro L, Bosch J. The treatment of portal hypertension: a meta-analytic review. *Hepatology*. 1995; 22: 332-354.
7. Bosch J, Garcia-Pagan JC. Complications of cirrhosis. I. Portal hypertension. *J Hepatol*. 2000; 32: 141-156.
8. Kim T, Shijo H, Kokawa H et al. Risk factors for hemorrhage from gastric fundal varices. *Hepatology*. 1997; 25: 307-312.
9. Sarin SK, Lahoti D, Saxena SP, et al. Prevalence, classification and natural history of gastric varices: a long-term follow-up study in 568 portal hypertension patients. *Hepatology*. 1992; 16: 1343-1349.
10. Jalan R, Hayes PC. UK guidelines on the management of variceal haemorrhage in cirrhotic patients. *British Society of Gastroenterology*. *Gut*. 2000; 46 Suppl 3-4: III1-III15.
11. Grace ND, Groszmann RJ, Garcia-Tsao G et al. Portal hypertension and variceal bleeding: an AASLD single topic symposium. *Hepatology*. 1998; 28:868-880.
12. Sarin SK, Jain AK, Jain M, et al. A randomized controlled trial of cyanoacrylate versus alcohol injection in patients with isolated fundic varices. *Am J Gastroenterol*. 2002; 97: 1010-1015.

13. Lo GH, Lai KH, Cheng JS, et al. A prospective, randomized trial of butyl cyanoacrylate injection versus band ligation in the management of bleeding gastric varices. *Hepatology*. 2001; 33: 1060-1064.
14. Madsen MS, Petersen TH, Sommer H. Segmental portal hypertension. *Ann Surg*. 1986; 204: 72-77.
15. Sutton JP, Yarborough DY, Richards JT. Isolated splenic vein occlusion. Review of literature and report of an additional case. *Arch Surg*. 1970; 100: 623-626.
16. Sato T, Yamazaki K, Toyota J, et al. Gastric varices with splenic vein occlusion treated by splenic arterial embolization. *J Gastroenterol*. 2000; 35: 290-295.
17. Suhocki PV, Berend KR, Trotter JF. Idiopathic splenic vein stenosis: a cause of gastric variceal hemorrhage. *South Med J*. 2000; 93: 812-814.
18. Jalan R, Hayes PC. UK guidelines on the management of variceal haemorrhage in cirrhotic patients. *British Society of Gastroenterology. Gut*. 2000; 46 Suppl 3-4: III1-III15.
19. Sanyal AJ, Freedman AM, Luketic VA et al. The natural history of portal hypertension after transjugular intrahepatic portosystemic shunts. *Gastroenterology*. 1997; 112: 889-898.
20. Casado M, Bosch J, Garcia-Pagan JC, et al. Clinical events after transjugular intrahepatic portosystemic shunt: correlation with hemodynamic findings. *Gastroenterology*. 1998; 114: 1296-1303.
21. Pomier-Layrargues G, Villeneuve JP, Deschenes M, et al. Transjugular intrahepatic portosystemic shunt (TIPS) versus endoscopic variceal ligation in the prevention of variceal rebleeding in patients with cirrhosis: a randomised trial. *Gut*. 2001; 48: 390-396.
22. Koster T, Rosendaal FR, de Ronde H, et al. Venous thrombosis due to poor anticoagulant response to activated protein C: Leiden Thrombophilia Study. *Lancet*. 1993; 342: 1503-1506.
23. Ridker PM, Miletich JP, Hennekens CH, et al. Ethnic distribution of factor V Leiden in 4047 men and women. Implications for venous thromboembolism screening. *JAMA*. 1997; 277: 1305-1307.
24. Kalafatis M, Haley PE, Lu D, et al. Proteolytic events that regulate factor V activity in whole plasma from normal and activated protein C (APC)-resistant individuals during clotting: an insight into the APC-resistance assay. *Blood*. 1996; 87: 4695-4707.
25. Koster T, Rosendaal FR, de Ronde H, et al. Venous thrombosis due to poor anticoagulant response to activated protein C: Leiden Thrombophilia Study. *Lancet*. 1993; 342: 1503-1506.
26. Rosendaal FR, Koster T, Vandenbroucke JP, et al. High risk of thrombosis in patients homozygous for factor V Leiden (activated protein C resistance). *Blood*. 1995; 85: 1504-1508.
27. Koster T, Blann AD, Briet E, et al. Role of clotting factor VIII in effect of von Willebrand factor on occurrence of deep-vein thrombosis. *Lancet*. 1995; 345: 152-155.
28. Kamphuisen PW, Eikenboom JC, Bertina RM. Elevated factor VIII levels and the risk of thrombosis. *Arterioscler Thromb Vasc Biol*. 2001; 21: 731-738.
29. Koster T, Blann AD, Briet E, et al. Role of clotting factor VIII in effect of von Willebrand factor on occurrence of deep-vein thrombosis. *Lancet*. 1995; 345: 152-155.
30. Libourel EJ, Bank I, Meinardi JR, et al. Co-segregation of thrombophilic disorders in factor V Leiden carriers; the contributions of factor VIII, factor XI, thrombin activatable fibrinolysis inhibitor and lipoprotein(a) to the absolute risk of venous thromboembolism. *Haematologica*. 2002; 87: 1068-1073.
31. Lensen R, Bertina RM, Vandenbroucke JP, et al. High factor VIII levels contribute to the thrombotic risk in families with factor V Leiden. *Br J Haematol*. 2001; 114: 380-386.
32. Arias PJ, Aller Reyero MA, Lorente RL, et al. [Segmental portal hypertension caused by aneurysm of the distal splenic artery]. *Rev Esp Enferm Apar Dig*. 1989; 75: 485-488.
33. Palareti G, Leali N, Coccheri S, et al. Bleeding complications of oral anticoagulant treatment: an inception-cohort, prospective collaborative study (ISCOAT). Italian Study on Complications of Oral Anticoagulant Therapy. *Lancet*. 1996; 348: 423-428.
34. Douketis JD, Kearon C, Bates S, Duku EK, Ginsberg JS. Risk of fatal pulmonary embolism in patients with treated venous thromboembolism. *JAMA*. 1998; 279:458-462.
35. Kyrle PA, Minar E, Hirschl M, et al. High plasma levels of factor VIII and the risk of recurrent venous thromboembolism. *N Engl J Med*. 2000; 343: 457-462.