

Case report

Thigh abscess following acute diverticulitis. Report of two casesN.S. Xeropotamos¹, V.E. Nousias¹, A.D. Vekris¹, K.H. Katsanos², E.V. Tsianos², A.M. Kappas¹**SUMMARY**

The incidence of inflammatory diverticular disease in patients with diverticulosis has been reported to range from 12%-35%. Delayed diagnosis and treatment of perforated diverticulitis is accompanied by high mortality. Perforation of diverticulum is often localized and may result in abscess formation. This abscess may resolve, may rupture into the peritoneal cavity or may drain into various organs or viscera. Finally, the abscess may track intraperitoneally or extraperitoneally.

In both cases presented here, there was a communication of the inflammatory diverticular disease of the sigmoid colon with an abscess cavity in the Scarpa's triangle, tracking down through the femoral canal in the first case, and through the abdominal wall in the second case. The underlying intraabdominal lesion was treated by sigmoidectomy according to Hartmann's procedure in the first case and by sigmoidectomy and an end- to- end anastomosis in the second. These procedures were combined with local drainage of the thigh abscesses with good results.

In conclusion, it becomes apparent that in such cases, where the underlying intraabdominal lesion is overlooked, the mortality rate is as high as 93%. However, if the underlying intraperitoneal pathology is early recognised and successfully treated, in combination with thigh abscess management, the overall mortality drops to 34%.

Key Words: thigh abscess, acute diverticulitis, management

INTRODUCTION

The incidence of inflammatory diverticular disease in patients with diverticulosis has been reported to range from 12% to 35%. Delayed diagnosis and treatment of perforated diverticulitis is accompanied by high mortality¹. A diverticulum may perforate can occur freely into the peritoneal cavity (up to 5% of cases) or perforation may be localized, resulting in abscess formation (up to 39% of cases)². This abscess may resolve, may rupture into the peritoneal cavity, may drain into various organs or viscera resulting in fistulae formation, or may track intraperitoneally or extraperitoneally, along fascial planes or paths with minor resistance. Extraperitoneal tracking may result in the appearance of an inflammatory mass with or without crepitus and pain, or may result in the appearance of a fistula. The latter may track along various anatomical pathways of the abdomen, retroperitoneum, and pelvis, and finally reach a place such as the abdominal wall, flank, perineum, scrotum, buttock, vagina, hip joint, thigh, lower extremities, mediastinum, and neck³. The incidence of thigh abscesses is extremely low. It seems that thigh abscesses are relatively rare and often appear to arise primarily from local structures. Pyomyositis, infected hematoma with or without gas formation, osteomyelitis, localized cellulitis, and thrombophlebitis represent the most frequent diagnoses in patients presenting with a painful, tender, swollen thigh which is also associated with fever and leucocytosis⁴.

We present here two additional cases with literature review, focusing on the unusual extraperitoneal presentation of perforated diverticular disease involving the thigh.

CASE REPORTS**Case 1**

A 58-year old female patient was admitted to the

¹Department of Surgery, ²Hepato-Gastroenterology Unit, (1ST Department of Internal Medicine), Medical School, University of Ioannina, Greece

Author for correspondence:

N. S Xeropotamos, Assistant Professor of Surgery, 4 Pogoniou Street, T.K. 45332, Tel: #30-26510 67955 – #30-26510 99692-3, Fax: #30-26510 99768, e-mail: bnousias@in.gr, Ioannina, Greece

hospital due to left lower abdominal pain reflecting to the left thigh, fever up to 39 °C, diarrhea and vomiting. The patient had a history of rheumatoid arthritis, scleroderma and arrhythmia and was following standard medication. Physical examination revealed an emaciated patient with obvious signs of collagen disease. Clinical examination revealed tenderness and rebound tenderness of the abdominal wall, especially in the left lower quadrant. Laboratory findings showed leucocytosis and significant CRP elevation. Ultrasound and plain abdominal x-rays were within normal limits. Acute diverticulitis was suspected preoperatively and the patient was started on conservative treatment but with no improvement after a week of treatment. At that time abdominal CT-scan revealed diverticulae of the sigmoid colon and free intraperitoneal fluid (Fig. 1). Laparotomy was performed urgently and generalized peritonitis with a presence of 1500 ml of inflammatory fluid and pus was found. In addition, an inflammatory mass at the sigmoid colon, compatible with diverticulitis, and an abscess at the left iliac fossa, down to the pelvic floor were found. Mobilization of the sigmoid colon revealed communication of the above mentioned abscess with a second abscess in the Scarpa's triangle, tracking down through the femoral canal. Evacuation of both abscesses and rectosigmoid colon resection according to Hartmann's procedure were performed. Postoperative course was uneventful and the patient was discharged 36 days after admission in a very good general condition.

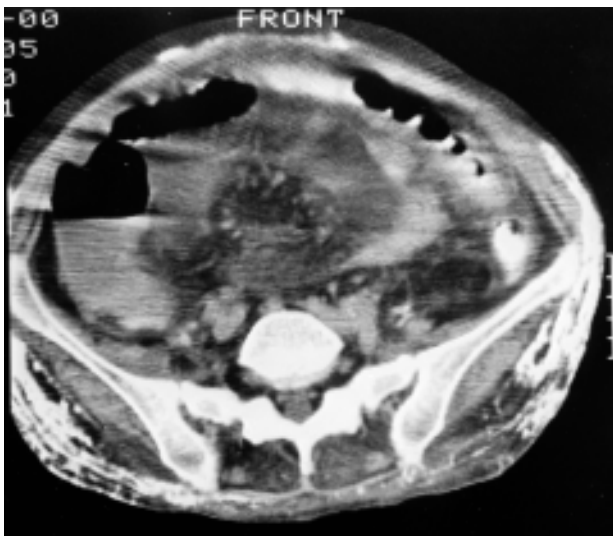


Figure 1. Abdominal CT scan showing sigmoid colon diverticulae and free intraperitoneal fluid.

Case 2

A 58-year old female patient was admitted to the hospital with left lower quadrant abdominal pain, fever up to 38 °C, pneumaturia and presence of faeces during urination. The patient had a previous history of hypertension, cholelithiasis, hepatitis C and drug allergy. In addition, the patient had relapsing episodes of low urinary tract infections, and grade 1 urinary bladder transitional cell carcinoma. In addition, the patient had undergone left total hip replacement seven years earlier, and had been examined many times for suspected hip prosthesis infection.

Physical examination revealed left lower abdominal wall tenderness and a palpable mass in the same area. Laboratory findings showed leucocytosis and anemia. CT-scan showed an inflammatory mass, 5 cm in its greatest diameter, located within the left iliac fossa (Fig. 2). The patient was initially treated conservatively but without any clinical improvement. A laparotomy was subsequently performed, which revealed an inflamed sigmoid colon, a colovesical fistula and the presence of sinuses expanding to the left inguocrural area through the abdominal wall. Sigmoid colon resection with end-to-end anastomosis was performed.

Three weeks later the patient was readmitted to the hospital with inflammation in the left Scarpa's triangle and the ipsilateral inguinal area of the abdominal wall. Physical examination revealed the existence of a sinus tract ending in an abscess cavity, which were managed three days later by laying open the sinus tract and clearing

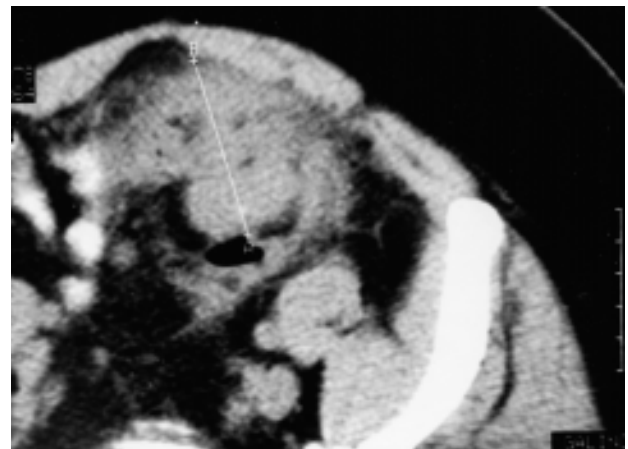


Figure 2. Abdominal CT scan showing pericolic abscess (5 cm in its greater diameter) located in the left iliac fossa deriving from acute diverticulitis.

the abscess cavity. The patient was given IV cefuroxime, metronidazole and fluids for 12 days and was discharged twenty-two days later, in good general condition.

DISCUSSION

Acute diverticulitis and lower gastrointestinal tract bleeding are the most common complications of diverticular disease, although bleeding from diverticula is not always associated with underlying acute inflammation⁵. The most common complication of sigmoid diverticulitis is a walled-off perforation or abscess; the acute inflammatory reaction usually involves the sigmoid colon and its mesentery. Signs and symptoms are most often confined to the left lower quadrant of the abdomen. Contrast radiological evaluation may reveal the changes previously described, but in addition there may be barium tracking into other areas. Conservative medical measures are usually sufficient, but in patients who continue to have pain, fever, white blood cell count elevation, or failure to tolerate oral alimentation, the surgeon should suspect presence of an abscess⁶.

Abscesses of the thigh are rare and, although easily diagnosed, their cause often remains obscure. We have presented two cases of thigh abscesses, which resulted from intraabdominal sepsis extension. A recent review of the literature reveals only forty-six previously reported cases. The underlying pathologic abnormality is usually a retroperitoneal perforation of a colorectal neoplasm or of a diverticular disease, whereas abscess origin from the small bowel or appendix is far less common.

The routes by which the infection spreads from the abdomen into extraabdominal areas has been studied by injection of air into the presacral space of cadavers, with subsequent development of subcutaneous emphysema in the lower abdominal wall, scrotum, thigh, and buttock⁷.

By reviewing the reported cases of thigh abscesses, it is clear that the route of spread can be broadly separated into two groups⁷. Direct soft tissue extension of infection originating from the gastrointestinal tract, which then passes down, to the thigh (noticed in 12 cases in the literature) almost always originates from the extraperitoneal portion of the rectum, from a perforated carcinoma of the rectum or an ischiorectal abscess. Cecal, appendiceal, and descending colonic abscess origins have been reported as well⁸⁻¹⁰.

The second broad group of routes of infection extension into the thigh is through naturally occurring

abdominal wall defects; a) along the iliofemoral vessels, as classically occurs when tuberculous osteomyelitis presents as a fluctuant femoral mass (19 cases reported in the literature); b) through the femoral canal (3 cases reported in the literature); c) by the way of the obturator foramen (3 cases reported in the literature); or d) through the sacrosiatic notch into the buttock and thigh posteriorly (5 cases reported in the literature).

Knowing the difficulty of making the correct initial diagnosis, especially in young patients. It seems that a high suspicion index is important. The two diagnostic studies with the greatest accuracy are abdominopelvic CT and barium or gastrografin enema¹¹. In addition, ultrasound may show abnormal fluid collection in the presence of an abscess but is otherwise unreliable in diverticulitis¹².

The abscess cases we described above are uncommon since in both patients, the source of sepsis originated from an intraperitoneal portion of intestine. Furthermore, the connection of the intraperitoneal lesion to extraperitoneal areas and subsequently into the thigh was completed through the aforementioned routes, such as femoral canal and direct soft tissue extension through the Retzius region.

It must be stressed that intraabdominal lesion and thigh abscess must be treated. From the literature review, it becomes apparent that in cases, where the underlying pathologic lesion was overlooked and the treatment consisted only of local thigh drainage the mortality rate was high. However, if the underlying intraabdominal lesion is diagnosed and successfully treated by appendectomy or colostomy combined with management of the thigh abscess, the overall mortality drops to 34%⁴.

Furthermore, these unusual presentations more commonly occur in elderly women, where delayed diagnosis significantly increases the mortality rate¹³⁻¹⁴.

Operative intervention of complicated diverticulitis is generally required and the best timing is determined in relation to the specific clinical situation. Emergent surgery is required for patients with free perforation and peritonitis. Whether a multistaged resection is necessary, depends on the degree of peritoneal contamination and the overall patient condition. Fecal peritonitis and advanced generalized fibrinous peritonitis often needs to be treated by resection, end colostomy, and Hartmann closure of the rectum as in our first case; reanastomosis is performed at a later date. Early fibrinous peritonitis with colovesical fistula may be treated safely with single-stage resection with on-table

lavage and end-to-end anastomosis.

REFERENCES

1. Botsford TW, Zollinger RM, Hicks R. Mortality of the surgical treatment of diverticulitis. *Am J Surg* 1971; 121:702-705.
2. Rodkey GV, Welch CE. Colonic diverticular disease with surgical treatment. *Surg Clin North Am* 1974; 54:655-665.
3. Ravo B, Khan SA, Ger R, et al. Unusual Extraperitoneal Presentations of Diverticulitis. *Am J Gastroenterol* 1985; 80:349-351.
4. Rotstein OD, Pruett TL, Simmons RL. Thigh Abscess: An Uncommon Presentation of Intraabdominal Sepsis. *Am J Surg* 1986; 151:414-418.
5. Schoetz DJ. Diverticular Disease of the Colon: A Century-Old Problem. *Dis Colon Rectum* 1999;42:703-709.
6. Corman ML. Diverticular Disease: Complications. In: Corman ML, eds. *Colon and Rectal Surgery*. 3rd ed. Philadelphia: JB Lippincott, 1993:830-834.
7. Fiss TW, Cigtay OS, Miele AJ, et al. Perforated viscus presenting with gas in the soft tissues (subcutaneous emphysema). *AJR* 1975; 125:226-233.
8. Lee JB. Cystitis emphysematosa. *Arch Intern Med* 1960; 105:618-626.
9. Shaumbaugh P, Burgert PH. Subcutaneous emphysema in cancer of the colon. *Arch Surg* 1962; 85:344-346.
10. Spring M, Kahn S. Non-clostridial gas infection in the diabetic. *Arch Intern Med* 1951; 88:373-377.
11. Ambrosetti P, Robert JH, Witzig J, et al. Acute Left Colonic Diverticulosis in Young Patients. *J Am Coll Surg* 1994; 179:156-159.
12. Naliboff JA, Longmire-Cook SG. Diverticulitis Mimicking a Tuboovarian Abscess: Report of a Case in a Young Woman. *J Rep Med* 1996; 41:921-923.
13. Chankowsky J, Dupuis P, Gordon PH. Sigmoid diverticulitis presenting as a lower extremity abscess: report of a case. *Dis Colon Rectum* 2001; 444:1711-1713.
14. Rothenbuehler JM, Oertli P, Harder F. Extraperitoneal manifestations of perforated diverticulitis. *Dig Dis Sci* 1993; 38:1985-1988.