

Case report

Hyperamylasemia in Inflammatory Bowel Disease: Report of a case with literature review

K.H. Katsanos¹, G. Kolios², G.V. Tsianos³, E.V. Tsianos¹

SUMMARY

It has been suggested that in patients with inflammatory bowel disease (IBD) there is subclinical pancreatic involvement. A 22-year-old male with Crohn's disease of the terminal ileum, diagnosed four years earlier was admitted in our hospital because of persistent asymptomatic mild hyperamylasemia (serum amylase 135 UI/ml) during azathioprine treatment. Patient personal history was unremarkable and there was no evidence of any other extraintestinal manifestations. Physical examination was within normal limits and upper gastrointestinal tract endoscopy with abdominal MRI and MRCP were normal. During admission it was decided to switch from azathioprine to methotrexate in order to exclude the possibility of azathioprine-related idiopathic pancreatitis. However, serum amylase values did not subside. An additional MRCP performed at that time was normal. Subsequent serum isoamylase determination showed pancreatic iso-enzyme predominance (P-isoenzyme). As patient transaminases were markedly increased during methotrexate therapy, it was decided to finally switch the patient again to azathioprine as the diagnosis of chronic idiopathic pancreatitis secondary to Crohn's disease seemed more probable. On the two-year laboratory follow up the patient still had mild asymptomatic hyperamylasemia. Differential

diagnosis of hyperamylasemia in IBD includes overview of general and disease specific causes of hyperamylasemia, as well as laboratory investigative methods on amylase typing and subtyping. In the absence of specific indications this hyperamylasemia requires no further investigation.

Key words: hyperamylasemia, Crohn's disease, ulcerative colitis, isoamylases.

INTRODUCTION

The first suggestion of a significant association between pancreatic lesions and inflammatory bowel disease (IBD) was reported in 1950 by Ball et al.¹ who found 14% and 53% of macroscopic and histologic lesions, respectively, in a postmortem study of patients with ulcerative colitis (UC). The same team found mild to moderate pancreatic fibrosis at necropsy in 15 of 39 patients with Crohn's disease (CD).

The first report on hyperamylasemia in inflammatory bowel disease (IBD) was from Legge D et al. in 1971². This was the first report of pancreatitis as a complication of regional enteritis of the duodenum. The authors report 3 of 10 patients with "regional enteritis" involving the duodenum who were diagnosed with pancreatitis, as judged by elevated values for serum amylase and, in 2 of the 3 patients by the gross appearance of the pancreas at operation.

Whether the pancreas can be involved in the granulomatous inflammation of Crohn's disease (CD) is not known. Granulomas isolated to the pancreas in patients with sarcoidosis or tuberculosis has been suggested as a cause of acute or chronic pancreatitis in such cases. They have, however not been demonstrated in postmortem studies or pancreatic biopsies among patients with CD and pancreatitis³. Pancreatitis in inflammatory bowel

¹1st Division of Internal Medicine (Hepato-Gastroenterology Unit), Medical School of Ioannina, Greece, ²Department of Clinical Biochemistry, University Hospital of Ioannina, ³1st Department of Surgery, Trikala General Hospital, Greece

Author for correspondence and reprints:

Dr Epameinondas V. Tsianos, Professor of Internal Medicine, Medical School of Ioannina, Leoforos Panepistimiou, 451 10 Ioannina, Greece, Tel: +30-2651 0-97501, Fax: +30-2651 0-97016, e-mail: etsianos@cc.uoi.gr

disease in children is generally anecdotal⁴. According to another study,⁵ in ulcerative colitis (UC) a patient's pancreatitis was a prior manifestation in 58% of cases, while in patients with CD, pancreatitis appeared after disease onset in 58% of cases. In a study of exocrine pancreatic function in 143 CD patients, using Lundh meal test and duodenal aspirates analysis, exocrine pancreatic function was to be shown decreased in this group of patients⁶. The reason for this decreased pancreatic function in patients with CD is unclear. According to authors at least two factors seem to be responsible for impaired pancreatic function in Crohn's disease: firstly disease activity and secondly localization or extent of disease⁶.

Two different isoenzyme types constitute total serum α -amylase: The S-isoenzyme (salivary type, predominates in serum) and the P-isoenzyme (predominates in urine). It has been suggested that in patients with inflammatory bowel disease there is a subclinical pancreatic involvement⁷. In fact, it has been shown that in ulcerative colitis patients, the ratio between pancreatic and salivary isoamylase subtypes is reversed in favour of pancreatic isoenzyme, compared to healthy controls⁸. In another study for oral findings in patients with active or inactive Crohn's disease, it has been shown that levels of salivary amylase did not differ with respect to the activity of Crohn's disease⁹.

Herein we present a case of a young Crohn's disease patient with persistent hyperamylasemia of unknown origin, in whom serum isoamylase determination showed pancreatic isoenzyme predominance.

CASE REPORT

A 22-year-old male with Crohn's disease of the terminal ileum, diagnosed four years earlier was admitted to our hospital because of persistent asymptomatic mild hyperamylasemia. The patient was on azathioprine maintenance dose treatment (150mg/day).

At the time of admission, Crohn's disease activity index (CDAI) was 138, while peripheral blood count showed nothing remarkable. Routine biochemical analysis showed serum amylase 135 UI/ml (normal up to 90 UI/ml), while all other biochemical tests showed nothing remarkable. Patient body mass index (BMI) was in the upper normal limit, while fasting cholesterol and triglycerides values did not exceed the upper normal limit.

The patient's personal history was unremarkable and there was no evidence of any other extraintestinal manife-

station related to Crohn's disease. Family history was unremarkable and the patient had one brother with no history of any kind of chronic disease. The patient was not a smoker and denied any alcohol intake.

Physical examination showed nothing remarkable and upper gastrointestinal tract endoscopy was within normal limits. Unselected random gastric and duodenal biopsies did not show any evidence of upper gastrointestinal tract Crohn's disease involvement. Additionally, routine radiological examinations, including abdominal ultrasonography, were within normal limits.

By careful review of the patient's records it became evident that since initial diagnosis of Crohn's disease and before azathioprine introduction, serum amylase was persistently mildly increased ranging from 107 to 125 UI/ml (normal range up to 90 UI/ml), while patient was continuously asymptomatic.

At the time of diagnosis, four years ago, the patient was initially started on therapy with corticosteroids with subsequent tapering (15 mg of orally administered prednisolone), and azathioprine at a dose of 2mg/kg of body weight (150mg/day). The patient was discharged a few days later but in the three-month regular follow up amylase was still elevated, although patient still remained asymptomatic. Abdominal magnetic resonance imaging (MRI) and magnetic resonance cholangiopancreatography (MRCP) were performed then and did not show anything remarkable. Peripheral blood test and routine biochemistry remained within normal limits except for amylase. Immunology showed antinuclear autoantibodies titer of 1/320, that had subsided to normal titers by the next three-month follow-up.

During this last admission it was decided to switch azathioprine to oral methotrexate (dose of 15mg/week) in order to exclude the possibility of azathioprine-related idiopathic pancreatitis. However, in the six-month follow-up, serum amylase values had not subsided to normal values despite methotrexate introduction. A second MRCP, which was performed at that time, was normal. Subsequent serum isoamylase determination showed pancreatic isoenzyme (P-isoenzyme) predominance (Figure).

As patient transaminases were markedly increased (5-fold) during methotrexate therapy, it was finally decided to switch the patient back to azathioprine, as exclusion diagnosis of chronic idiopathic pancreatitis secondary to Crohn's disease seemed more logical, compared to that of possible azathioprine-related toxicity.

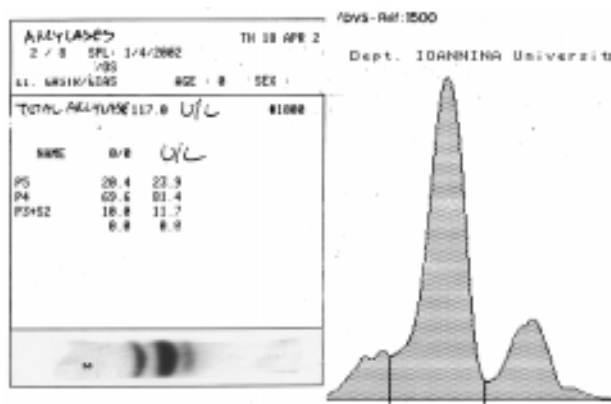


Figure 1. Hypersamylasemia in Crohn's disease. Isoamylases analysis with electrophoresis.

On the recent two-year laboratory follow up, the patient is still in inflammatory bowel disease remission under azathioprine maintenance dose (150mg/day) and still has mild asymptomatic hyperamylasemia.

DISCUSSION

Pancreatitis is a rare, extraintestinal manifestation of inflammatory bowel disease, while asymptomatic hyperamylasemia is a frequent laboratory finding that usually requires no further investigation.

The highest prevalence of hyperamylasemia ever reported was 44% and 64% of UC and CD patients respectively.⁵ However these numbers seem to be extremely high for any case series. A study with 136 IBD patients showed that asymptomatic elevation of serum amylase without symptoms of pancreatitis could occur in up to 14% of patients¹⁰. In a study with 237 patients diagnosed with IBD, hyperamylasemia was found in 11% of the group. The corresponding prevalence in CD and in ulcerative colitis were 17% and 9% respectively. High

levels of serum amylase were associated with extensive colonic disease and high histological activity. In addition, amylase was significantly elevated in patients with primary sclerosing cholangitis and smokers showed higher urinary amylase levels than non- and ex-smokers¹¹. In fact this patient was neither a smoker nor an ex-smoker, while MRCP failed to show any biliary tract involvement. However it seems that factors related to hyperamylasemia in IBD have not yet been well recognized as controversial results exist in the literature (Table 1).

A total of 211 medical files from our IBD outpatient clinic were retrospectively reviewed for evidence of hyperamylasemia (serum amylase levels over 90UI/ml at least once). Hyperamylasemia (range 92-1648 UI/ml) was recorded, at least once, in 21 out of 188 patients (11.2%) (Table 2). Only one patient (0.5%) with CD and hyperamylasemia was symptomatic and developed pancreatitis twice after short-term azathioprine administration (highest amylase value 1648 UI/ml). No correlation of hyperamylasemia with disease extension (UC or CD) was documented.

Differential diagnosis of hyperamylasemia in IBD includes overview of general and disease specific causes of hyperamylasemia, as well as laboratory investigation on amylase typing and subtyping. Abdominal imaging, as well as specific pancreatic function tests, may also be of help when available. Causes of hyperamylasemia with or without evidence of pancreatitis in IBD may be general or disease specific, while probable exceptional cases with co-existence of general and disease-specific causes may also occur in clinical practice.

The general causes of hyperamylasemia include: 1) Pancreatic diseases (acute pancreatitis, chronic pancreatitis, pancreatic cancer), 2) Hepato-biliary diseases (gallstones, choledochal stones, biliary tract cancer), 3) Acute abdo-

Table 1. Prevalence of asymptomatic hyperamylasemia in IBD and its correlation with several clinical parameters.

Author	Hyperamylasemia %	Disease Activity	Disease Extension	Duodenal location	Disease Treatment	Disease Duration	PSC*	Smoking	Weight loss	Sex
Tromm A, et al.	15.3	-			-	-			-	
Heikius B, et al.	17	+	+		-		+	+		
Katz S, et al.	8	-		-	-	-				
Le large-Guitiered	14.5	+	+	+	+		+			F>M**
Bohemeyer B.	14	-	+	+						
Barthet M, et al.	64									

*PSC= Primary Sclerosing Cholangitis, **F= females, M= males, += positive correlation, - = Negative correlation

Table 2. Disease characteristics of hyperamylasemic IBD patients from Northwest Greece with (AMS normal range 0-90 UI/ml).

Age/Sex	IBD type	Therapy	Extension	Disease duration (ys)	PSC highest	Smoking	Alcohol	AMS
57, M	UC	S	LUC	15	-	Yes	Yes	182
39, M	CD	S, Aza, Remicade	Ileocolitis	18	-	Yes	No	350
30, F	UC	S	TUC	15	-	No	No	210
72, M	UC	S	TUC	17	-	Yes	Yes	189
39, F	UC	S	TUC	16	-	No	No	115
38, M	UC	S, M	LUC	17	-	No	No	98
63, M	CD	S, M, Remicade	ileitis	5	-	Yes	Yes*	92
50, M	CD	S, M, MTX	ileitis	11	-	Yes	Yes	1648
62, F	UC	S, M	TUC	19	-	No	No	220
73, F	UC	S	LUC	15	-	No	No	95
48, M	UC	S	LUC	14	-	Yes	No	363
72, M	UC	S	LUC	10	-	Yes	No	113
87, M	UC	S	LUC	15	-	Yes	No	153
53, M	CD	S, Aza	ileitis	3	-	Yes	Yes	112
34, M	CD	S, M, Aza	ileitis	5	-	Yes	No	138
35, F	UC	S, M	TUC	2	-	No	Yes	120
80, M	UC	M, Aza	LUC	15	-	No	No	255
65, F	UC	S, Aza	LUC	15	-	No	No	200
67, F	UC	S	LUC	12	-	No	Yes	188
52, F	CD	S, M, Aza	ileocolitis	16	-	No	No	102
44, M	UC	S	TUC	6	+	No	No	1175

Abbreviations used in the table: M= male, F= female, CD= Crohn's disease, UC= ulcerative colitis, T= Total, L= Left, S= mesalazine, M= methylprednisolone, Aza= Azathioprine, MTX= methotrexate.

* hyperlipidemia also (CHOL=368 mg/dl)

minal pain (peptic ulcer perforation, peritonitis, intestinal obstruction, appendicitis, acute vascular episode), 4) Salivary gland diseases (measles, lithiasis, oral surgery), 5) Other causes such as chronic renal disease, alcohol, macroamylasemia, isoamylase production from malignant tumors, metabolic disorder, head trauma, hereditary pancreatitis, hyperlipidemia, hypercalcemia, parenteral nutrition, gestation, prostate diseases, S-type hyperamylasemia and several drugs including trimethoprim/sulfamethoxazole, corticosteroids, ACTH, estrogens, azathioprine, tetracycline, rifampycin, thiazidic diuretics, salicylates, anticoagulants, paracetamol and morphine.⁸ All the above causes were excluded by patient medical history and clinical and laboratory follow up.

Disease-specific causes of hyperamylasemia in IBD can be generally categorized as following: 1) Idiopathic hyperamylasemia as extraintestinal manifestation of IBD which seems the most probable cause in this particular patient. According to one study,¹² no alteration of intes-

tinal permeability could be demonstrated in patients with CD or UC. Painless hyperamylasemia or hyperlipasemia were found in 15.8% of CD patients and in 21.3% of UC patients without morphological abnormalities on abdominal ultrasound in the study by Tromm et al.¹³ 2) Pancreatic damage. Probable mechanisms may be the following: pancreatic autoantibodies, pancreatic duct strictures, granulomas and interlobular or perilobular fibrosis. Some investigators have found a high occurrence of autoantibodies against pancreatic tissue in serum from patients with CD, but contradictory reports still exist about their clinical significance.⁶ Autoantibodies to pancreas (PAB) are characterized by high disease specificity, although the incidence in Crohn's disease is low. In addition, it has been shown that families of patients with CD or UC had the same PAB subtypes.¹⁴

Although in this patient PAB were not tested, abdominal MRI and MRCP did not show any kind of macroscopic pancreatic involvement. 3) Drug-induced

hyperamylasemia, including azathioprine (or 6 MP), corticosteroids, sulfasalazine (or 5-ASA) in oral and rectal administration, metronidazole and Infliximab use. In their review of 676 cases of regional enteritis up to the early 50s' Crohn and Yarnis do not mention acute pancreatitis. First reports on acute pancreatitis were in transplant recipients receiving azathioprine, which were followed later on by reports on acute pancreatitis as a complication of azathioprine therapy in regional enteritis¹⁵. In an experimental study with isolated ex vivo perfused canine pancreas it was shown that azathioprine administration resulted in a significant increase in secretory volume and bicarbonate output and profound depression of trypsin output compared to controls.¹⁶ Azathioprine was associated with pancreatitis in at least 4.4% of patients receiving it in the National Cooperative Crohn's Disease Study.¹⁷ In 6 out of 113 patients with CD who developed pancreatitis, all cases occurred with the first 21 days of treatment. 6-MP has an important role in the IBD treatment. Its most frequent short-term complication has proved to be pancreatitis, which has an obscure pathophysiology. In a series of 400 IBD patients, 3.25% of them (13 patients) developed pancreatitis.¹⁸ In all cases, when 6-MP was discontinued symptoms and signs returned to normal over a period of 1-11 days. Rechallenge with low doses of 6-MP produced again the same symptoms. In the authors opinion this reaction seems to represent a type II (cytotoxic-complement-mediated) or type IV (sensitized T-lymphocyte-mediated) response.¹⁸

The pancreatic toxicity of oral 5-ASA derivatives used for the treatment of IBD remains controversial. This patient was never started on any kind of 5-ASA derivative. In a series of patients receiving mesalazine or olsalazine, acute pancreatitis occurred in 71.4% of cases during the first month of treatment.¹⁹ An example of acute pancreatitis developing five weeks after initial treatment with 5-ASA for severe Crohn's disease has been reported in a 37 year-old female patient.²⁰ Acute pancreatitis from 5-ASA derivatives receded within a few hours after the drug had been discontinued and pancreatic enzyme levels returned to normal in the course of the next 2-3 weeks in another case study.²¹ The authors support the scenario of allergic reaction to 5-ASA derivatives in these patients. In another case of acute pancreatitis with elevated serum amylase levels and ultrasonographic criteria of inflamed pancreas, it has been suggested that the sulfonamide component of sulfasalazine was responsible for this adverse effect because of the structural similarity of the sulfonamides to the thiazide diuretics, which are a well recognized cause of drug induced pancreatitis.²²

Furthermore, oral and rectal mesalazine administration, salicylazosulfapyridine and disodium azodisalicylate therapy can also induce reversible pancreatitis.²³⁻²⁵ Metronidazole use has been also associated with pancreatitis²⁶.

Finally, the role of infliximab (monoclonal chimeric antibody against TNF α) in inducing hyperamylasemia or even pancreatitis remains obscure at the moment, as controversial reports on its use in such cases exist.²⁷⁻²⁸ 4) Macroamylasemia may also rarely occur in IBD²⁹⁻³¹ and was excluded during amylase electrophoresis in this patient. 5) Duodeno-pancreatic fistula between the duodenum and pancreatic ducts also may be a triggering factor.¹⁸ 6) Ampullary damage from duodenal Crohn's disease and reflux of duodenal contents in the pancreatic duct could be another cause.³ 7) Direct ampullary involvement in Crohn's disease causing obstruction of pancreatic flow may also induce pancreatitis.⁵ 8) Intestinal complications such as ischemia, necrosis, perforation, obstruction may also cause hyperamylasemia from bowel and not from pancreatic origin.³² However upper gastrointestinal tract endoscopy and subsequent histology were negative. 9) Intravenous fat emulsions may rarely cause pancreatitis and this may be more likely in CD although here it was not the case. It is unclear whether hypertriglyceridemia secondary to intravenous fat emulsions, is a prerequisite for this complication to occur.³³ In addition, hypertriglyceridemia resulting from parenteral nutrition may be caused by glucose intolerance and not intravenous fat emulsion administration.³⁴

Methods of clinical investigation of hyperamylasemia in inflammatory bowel disease may include all methods studying for exocrine pancreatic function. The value of standard endoscopy and of ERCP or MRCP methods is undisputable as, in a series of 237 IBD patients, the prevalence of co-existing cholangiographic and pancreatographic duct changes was found to be 4.6%.³⁵ In this young patient, MRCP was preferred rather than ERCP as no signs of further clinical or laboratory deterioration were evident on long-term follow up.

Prevention of pancreatitis by weekly amylase assay in the first weeks of treatment in patients with IBD treated with azathioprine may represent a follow up strategy in such cases.³⁶⁻³⁸ This hyperamylasemia, in the absence of appropriate indications, requires no investigation. These indications arise from general and disease specific causes of hyperamylasemia discussed in previous paragraphs. These causes must always be overviewed when initial diagnosis of hyperamylasemia in any IBD patient occurs.

REFERENCES

1. Ball WP, Baggenstoss AH, Barga JA. Pancreatic lesions associated with chronic ulcerative colitis. *Arch Pathol* 1950;50:347-358.
2. Legge OA, Hoffman HN 2nd, Carlson HC. Pancreatitis as a complication of regional enteritis of the duodenum. *Gastroenterology* 1971; 61: 834-837.
3. Meyers S, Greenspan J, Greenstein AJ, Cohen BA, Janowitz HD. Pancreatitis coincident with Crohn's ileocolitis. Report of a case and review of the literature. *Dis Colon Rectum* 1987;30:119-122.
4. Le Large-Guiheneuf C, Hugot JP, Faure C, et al. Pancreatitis in inflammatory bowel disease in children. *Arch Pediatr* 2002; 9:469-477.
5. Barthet M, Hastier P, Bernard JP, et al. Chronic pancreatitis and inflammatory bowel disease: true or coincidental association? *Am J Gastroenterol* 1999; 94:2141-2148.
6. Hegnhoj J, Hansen CP, Rannem T, Sobirk H, Andersen IB, Andersen JR. Pancreatic function in Crohn's disease. *Gut* 1990; 31: 1076-1079.
7. Benjamin DR, Kenny MA. Clinical value of amylase isoenzyme determinations. *A J C P* 1974; 62:752.
8. Tsianos EV. Subclinical inflammatory process of exocrine glands in autoimmune diseases (A study of a-amylases). Professorial Thesis, Ioannina, 1984.
9. Halme L, Meurman JH, Laine P, et al. Oral findings in patients with active or inactive Crohn's disease. *Oral Surg Oral Med Oral Pathol* 1993; 76:175-181.
10. Bokemeyer B. Asymptomatic elevation of serum lipase and amylase in conjunction with Crohn's disease and ulcerative colitis. *Z Gastroenterol* 2002; 40:5-10.
11. Heikius B, Niemela S, Lehtola J, Karttunen T J. Elevated pancreatic enzymes in inflammatory bowel disease are associated with extensive disease. *Am J Gastroenterol* 1999; 94: 1062-1069.
12. Zellweger U, Freiburghaus AU, Munch R, Meyenberger C, Buhler H, Ammann R. (Measurement of intestinal permeability in Crohn's disease, ulcerative colitis, sprue and idiopathic hyperamylasemia using polyethyleneglycol-400). *Schweiz Med Wochenschr* 1990; 120:617-620.
13. Tromm A, Holtmann B, Kuntz HO, Schwegler U, May B. (Hyperamylasemia, hyperlipasemia and acute pancreatitis in chronic inflammatory bowel diseases). *Leber Magen Darm* 1991; 21:15-16.
14. Seibold F, Mork H, Tanza S, et al. Pancreatic autoantibodies in Crohn's disease: a family study. *Gut* 1997; 40:481-484.
15. Nogueira JR, Freedman MA. Acute pancreatitis as a complication of Imuran therapy in regional enteritis. *Gastroenterology* 1972; 62:1040-1041.
16. Broe PJ, Cameron JL. Azathioprine and acute pancreatitis: studies with an isolated perfused canine pancreas. *J Surg Res* 1983; 34:159-163.
17. Sturdevant RA, Singleton JW, Deren JL, Law OH, McCleery JL. Azathioprine-related pancreatitis in patients with Crohn's disease. *Gastroenterology* 1979; 77:883-886.
18. Haber CJ, Meltzer SJ, Present OH, Korelitz BI. Nature and course of pancreatitis caused by 6-mercaptopurine in the treatment of inflammatory bowel disease. *Gastroenterology* 1986; 91: 982-986.
19. Decocq G, Gras-Champel V, Vrolant-Mille C, et al. (Acute pancreatitis induced by drugs derived from 5-aminosalicylic acid: case report and review of the literature). *Therapie* 1999; 54:41-48.
20. Tromm A, Huppe D, Micklefield GH, Schwegler U, May B. Acute pancreatitis complicating Crohn's disease: mere coincidence or causality? *Gut* 1992; 33:1289-91.
21. Eckardt VF, Kanzler G, Rieder H, Ewe K. (Pancreatitis associated with 5-aminosalicylic acid). *Dtsch Med Wochenschr*. 1991; 116:540-542.
22. Sachedina B, Saibil F, Cohen IB, Whitley J. Acute pancreatitis due to 5-aminosalicylate. *Ann Intern Med* 1989; 110:490-492.
23. Schworer H, Ramadori G. (Acute pancreatitis-adverse effect of 5-aminosalicylic acid [mesalazine] in various galenic dosage forms). *Dtsch Med Wochenschr* 2000; 125:1328-1330.
24. Poldermans D, van Blankenstein M. Pancreatitis induced by disodium azodisalicylate. *Am J Gastroenterol* 1988; 83:578-580.
25. Block, Genant HK, Kirsner JB. Pancreatitis as an adverse reaction to salicylazosulfapyridine. *N Engl J Med* 1970; 282:380-382.
26. Romero Y, Yebra M, Lacombe F, Manzano L. Metronidazole and pancreatitis. *Clin-Infect Dis* 1992; 15:750-751.
27. Triantafillidis JK, Cheracakis P, Hereti IA, Argyros N, Karra E. Acute idiopathic pancreatitis complicating active Crohn's disease; favorable response to Infliximab. *Am J Gastroenterol* 2000; 95:3334-3336.
28. Oruc N, Ozutemir AO, Yukselen V, Nart D, Celiu HA, Yuce G. Infliximab: a new therapeutic agent in acute pancreatitis. *Pancreas* 2004;28:1-8.
29. Okumura Y, Tamba J, Shintani Y, et al. Macrolipasemia in Crohn's disease. *Pancreas* 1998; 16:205-210.
30. Haseda Y, Mori K, Sato T, et al. (A suggestive case of Crohn disease with macroamylasemia [author's transl]) Niñon Shokakibyō Gakkai Zasshi 1979; 76:1857-1863.
31. Levitt MD, Ellis C. A rapid and simple assay to determine if macroamylase is the cause of hyperamylasemia. *Gastroenterology* 1982; 83:378.
32. Salem SN, Truelove SC. Small intestinal and gastric abnormalities in ulcerative colitis. *Br J Med* 1964; 1:827.
33. Leibowitz AB, O'Sullivan P, Iberti T J. Intravenous fat emulsions and the pancreas: a review. *Mt Sinai J Med* 1992; 59:38-42.
34. Kristensen M, Lenz K, Nielsen OV, Jarnum S. Short bowel syndrome following resection for Crohn's disease. *Scand J Gastroenterol* 1974; 9:559-565.
35. Merritt AD, Karn RC. The human a-amylases. *Adv Human Gen* 1977; 8:135.
55. Heikius B, Niemela S, Lehtola J, Karttunen T, Lahde S. Hepatobiliary and coexisting pancreatic duct abnormalities in patients with inflammatory bowel disease. *Scand J Gastroenterol* 1997; 32:153-161.

36. Castiglione F, Del Vecchio Blanco G, Rispo A, Mazzacca G. Prevention of pancreatitis by weekly amylase assay in patients with Crohn's disease treated with azathioprine. *Am J Gastroenterol* 2000; 95:2394-2395.
37. Jordan GL Jr. Problems in the diagnosis of recurrent pancreatitis. *South Med J* 1967; 60:726-729.
38. Katz S, Bank S, Greenberg RE, Lendvai S, Lesser M, Napolitano B. Hyperamylasemia in inflammatory bowel disease. *J Clin Gastroenterol* 1988; 10:627-630.