

*Case report*

## Acute Esophageal Necrosis: Is it a so Uncommon Endoscopic Finding? A Report of Two Cases

P. Katsinelos, I. Pilpilidis, P. Tsoikas, I. Galanis, <sup>1</sup>Daphni Katsiba, <sup>1</sup>Maria Arvaniti, K. Christodoulou, A. Papagiannis, P. Xiarchos, S. Baltagiannis, P. Kapelidis, I. Vasiliadis, I. Kapitsinis

### SUMMARY

Acute esophageal necrosis (AEN) is uncommon, having been described only a few times previously. Most cases have no known etiology, although ischemia, nasogastric tube trauma and infection have all been suggested as possible causes. We describe two cases of AEN, summarize the published cases to date, and then propose the mechanism whereby patients may be predisposed to this uncommon disease.

**Key words:** Acute esophageal necrosis (AEN)

### INTRODUCTION

Acute esophageal necrosis is uncommon and has been described only a few times previously. It is defined as a dark pigmentation of the esophagus associated with histologic mucosal necrosis<sup>1</sup>. The etiology remains unknown but is most likely multifactorial, even though most reports have suggested an ischemic pathogenesis.<sup>1-7</sup>

We describe two patients with acute esophageal necrosis and summarize the published cases to date.

### CASE ONE

A 82-yr-old male was admitted with a 3-day history of epigastric pain and black stools. There was no history

<sup>1</sup>Department of Endoscopy, General Hospital "George Gennimatas", Thessaloniki, Greece, <sup>1</sup>Department of Radiology, General Hospital "George Gennimatas", Thessaloniki, Greece

Author responsible for correspondence and reprints:

Panagiotis Katsinelos, Marathonos 14, 546 38 Thessaloniki, Greece, Fax: 031057070,

of upper gastrointestinal ulcer, GERD, or corrosive intake. Past medical history was significant for hypertension, coronary insufficiency and arthritis of left shoulder. Medications included daily coated aspirin, nifedipine, lisinopril, fluvastatine, and naproxen for his arthritis.

On admission, the patient was hemodynamically stable, a febrile, with a regular pulse of 95 bpm, blood pressure of 155/90 mm, and central venous pressure 5cm water. Physical examination revealed a moderately distended abdomen, mild epigastric tenderness, and the presence of normal bowel sounds. Digital examination was positive for blood. Laboratory data (normal values in parentheses) were remarkable for a WBC count of 12000 without a left shift, hemoglobin of 9.7 gm/dl (12-15), hematocrit 28% (36-45%), creatinine of 1.5 mg/dl (0.5-1.2) and glucose of 145 mg/dl (70-115). Biochemical tests of liver function, amylase, lipase, and prothrombin time were within normal limits. The initial therapy consisted of i.v. fluids. On the following day, upper endoscopy demonstrated blackish esophageal mucosa with ulceration (Figure 1) from the upper third of the esophagus to the cardia. In addition, there were three prepyloric ulcers.

Histological examination of the esophageal biopsy specimens revealed mucosal inflammation, ulceration, and necrotic debris. The Grocott stain was negative for mycotic infection. Immunostaining and viral cultures were negative for cytomegalovirus and herpes virus. He was transfused with two units of blood, and omeprazole 20 mg/day was given for 6 weeks. The patient was discharged on day 8.

Upper GI endoscopy 6 weeks later revealed normal pink esophageal mucosa without evidence of necrosis,

exudate or stricture formation.

## CASE TWO

A 75-year-old man was evaluated in the emergency room for severe upper abdominal pain which had started two hours earlier. Past medical history was significant for hypertension, mild renal insufficiency and left shoulder osteoarthritis. Medication included daily atenolol, lisinopril and nonsteroidal antiinflammatory agents. He was afebrile, with a regular pulse of 98 bpm, and blood pressure of 165/90 mm/Hg. Physical examination revealed a moderate distended abdomen intense epigastric tenderness, a succussion splash and the absence of bowel sound. Laboratory data (normal values in parenthesis) were remarkable for a WBC of 18.000 with a left shift, hemoglobin 13.6 gm/dl (12-15) creatinine 1.9 mg/dl (0.5-1.2) and glucose 135 mg/dl. Amylase and prothrombin time were all within normal limits. A chest x-ray and plan x-rays of the abdomen revealed a collection of air under the right diaphragm. A nasogastric tube was placed and approximately 250mL of brown liquid was removed.

With a diagnosis of gastroduodenal perforation due to consumption of non-steroidal agents, he underwent an operation. Laparotomy revealed a large perforated ulcer in the middle of the lesser curvature. A Billroth II operation was performed but his postoperative course was complicated by aspiration pneumonia, hypotension, and adult respiratory distress syndrome. He required ventilatory support and was treated with intravenous omeprazole (40mg twice a day), intravenous piperacilin and metronidazole; intermittent nasogastric tube suction was

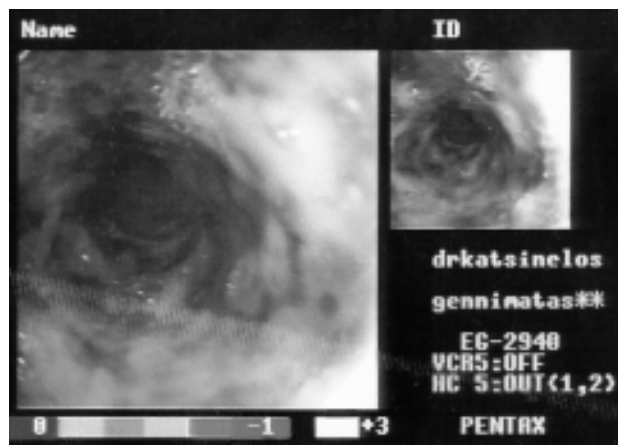
continued. On day 9 he passed melena and an EGD revealed the presence of thick black exudate from 19 cm to the gastroesophageal junction located at 40 cm (Figure 2). Biopsies demonstrated mucosal inflammation, and necrotic debris. The Grocott stain was negative for mycotic infection. Immunostaining and viral cultures were negative for cytomegalovirus and herpes virus. The patient died 5 days later as a result of multiorgan failure.

## DISCUSSION

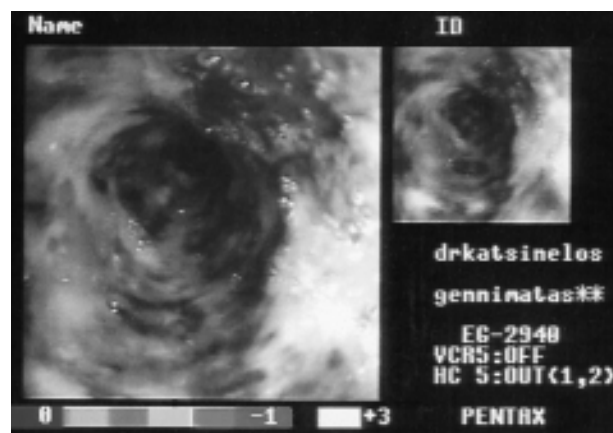
Acute esophageal necrosis (AEN) is a rare entity, the etiology of which is usually unknown. The necrosis is almost always circumferential and can extend along the entire esophagus to the gastroesophageal junction. Microscopically, AEN appears as severe necrosis of the mucosa and submucosa. Inflammation and partial destruction of adjacent muscle fibers may occasionally be seen and blood vessels are sometimes thrombosed or occluded.<sup>8</sup>

Often described as the black esophagus. This must be distinguished from other entities that can give the appearance, endoscopically, of a black esophagus, such as melanosis,<sup>9,10</sup> malignant melanoma<sup>11</sup>, pseudomelanosis,<sup>12</sup> and acanthosis nigricans<sup>2</sup>. Other entities that can produce a similar appearance include ingestion of caustic substances and local necrosis secondary to various infections.<sup>13,14</sup>

A review of the literature shows that 26 cases of AEN have been described over the last thirty years in addition to the cases described in this report. The exact cause of AEN has been found in only four cases. Cappel reported a 50-year old man who developed ischaemic AEN due



**Figure 1.** Endoscopic view of black-appearing middle and distal esophageal mucosa.



**Figure 2.** Endoscopic view of esophagus which is circumferentially black and friable.

to anticardiolipin antibody syndrome.<sup>15</sup> Two other patients had erythema multiforme or Stevens-Johnson syndrome.<sup>16,17</sup> Lee et al reported an 81-year-old who died after sudden dissection of the thoracic aorta. The autopsy revealed a huge retro-mediastinal hematoma compressing the mid-distal esophagus, causing transmural necrosis.<sup>18</sup>

The cause of AEN remains unknown in the rest of the reported cases. A variety of mechanisms have been proposed to account for the development of this unusual disease, and include nasogastric tube trauma, hyperglycemia, hypersensitivity to antibiotics, an underlying malignancy, herpetic infection or an association with a gastric valvulus.<sup>19-23</sup> In addition, local ischaemia has been proposed as a cause of AEN, despite the fact that in humans the esophageal blood supply is extensive,<sup>24-26</sup> and there was only one case with prolonged hypotension.<sup>19</sup>

The case first described here is unique because of the absence of any of the conditions listed above. He was admitted to hospital in a stable condition reporting black stools in the previous 3 days and on his second day in the hospital, during a routine upper endoscopy, a diffuse necrosis of the esophageal mucosa was diagnosed. It is quite remarkable that our patient developed AEN without clinical evidence of hypotension or shock. It seems that old age, generalized atherosclerosis and a clinically silent hypotensive episode may have resulted in AEN. Our case underscores the fact that, despite its diverse blood supply, the esophagus may be more vulnerable to ischemic injury in the elderly.

The second case was a patient in the intensive care unit, intubated with hemodynamic instability, and so more vulnerable to ischemic necrosis of the esophageal mucosa.

AEN is an uncommon disease whose precise etiology remains largely unknown. Forty percent of patients with this condition do not have any long-term sequelae, but one quarter develop complications such as esophageal strictures or stenosis, and one third die due to their underlying illness or as a direct result of AEN<sup>21</sup>. Therefore, after the correct diagnosis, appropriate management must be provided, which should include adequate hydration, treatment of underlying illness, and aggressive acid suppression with proton pump inhibitors.

Despite the fact that our department is new, (18 months), we observed two cases of AEN, and probably AEN is a more frequent endoscopic finding than usually supposed.

## REFERENCES

1. Goldenberg SP, Wain SL, Marignani P. Acute necrotizing esophagitis. *Gastroenterology* 1990; 98:493-6.
2. Geller A, Aguilaz H, Burgart L, Gostout CJ. The black esophagus. *Am J Gastroenterol* 1995; 90:2210-2.
3. Cummings DR. Acute necrotizing esophagitis (letter). *Gastroenterology* 1990; 99:1193.
4. Tuso P, Marignani P. Necrotizing duodenitis: a stress associated lesion? *J Clin Gastroenterol* 1990; 12:29-32.
5. Benhaim-Iseni MC, Brenet P, Petite JP. Acute necrotizing esophagitis: another case. *Gastroenterology* 1991; 101:281-2.
6. Robert JY, Raoul JL, Bretagne JF, Nouel O, Faroux R, Daigre JL, et al. Black esophagus: three new cases. *Gastroenterol Clin Biol* 1993; 17:298-301.
7. Goldenberg SP, Wain SL, Marignani P. Reply to Benhaim-Iseni MC, Brenet P, Petite JP. *Gastroenterology* 1991; 101:281-2.
8. Moreto M, Ojembarrena E, Zaballa M, Tanago JG, Ibanez S. Idiopathic acute esophageal necrosis: not necessarily a terminal event. *Endoscopy* 1993; 25:534-8.
9. Sharma SS, Venkateswaran S, Chacko A, Mathan M. Melanosis of the esophagus: an endoscopic, histochemical, and ultrastructural study. *Gastroenterology* 1991; 100:13-6.
10. Dumas O, Barthelemy C, Billard F, Dumallard JM, Boucheron S, Calmard P, et al. Isolated melanosis of the esophagus: systemic endoscopic diagnosis. *Endoscopy* 1990; 22:94-5.
11. Raven RW, Dawson I. Malignant melanoma of the esophagus. *Br J Surg* 1964; 51:551-5.
12. Kimball MK. Pseudomelanosis of the esophagus. *Gastrointest Endosc* 1978; 23:121-2.
13. Loeb PM, Eisenstein AM. Caustic injury to the upper gastrointestinal tract. In: Sleisinger MH and Fordtran JS, eds. *Gastrointestinal disease: Pathophysiology, diagnosis, management*, 5<sup>th</sup> ed. Philadelphia: Saunders, 1993: 293-301.
14. Me Manus JPA, Webb JN. A yeast-like infection of the esophagus caused by *Lactobacillus acidophilus*. *Gastroenterology* 1975; 68: 583-6.
15. Cappel MS. Esophageal necrosis and perforation associated with the anticardiolipin antibody syndrome. *Am J Gastroenterol* 1994; 89:1241-5.
16. Mangan TF, Colley AT, Wytocck DM. Antibiotic-associated acute necrotizing esophagitis. *Gastroenterology* 1990; 99:900.
17. Mähe A, Keita S, Blanc L, Bobin P. Esophageal necrosis in the Stevens-Johnson syndrome. *J Am Acad Derm* 1993; 29:103-4.
18. Lee KR, Stark E, Shaw FE. Esophageal infarction complicating spontaneous rupture of the thoracic aorta. *JAMA* 1977; 237:1233-4.
19. Haviv YS, Reinus C, Zimmerman J. Black esophagus: a rare complication of shock. *Am J Gastroenterol* 1996; 91:2432-4.

20. Erdozain JC, Herrera A, Molina E, Munoz F, Presa M, Martinde-Argila C. Idiopathic acute esophageal necrosis: report of a new case. *Endoscopy* 1994; 26:713.
21. Marie-Christine Bl, Pascal B, Jean-Pierre P. Acute necrotizing esophagitis: another case (letter). *Gastroenterology* 1991; 101:281.
22. Lacy BE, Toor A, Bensen SP, Rothstein RI, Maheshwari Y. Acute esophageal necrosis: report of two cases and a review of the literature. *Gastrointest Endosc* 1999; 49:527-32.
23. Kram M, Gorenstein L, Eisen D, Cohen D. Acute esophageal necrosis associated with gastric volvulus. *Gastrointest Endosc* 2000; 51:610-12.
24. Cattan P, Cuillerier E, Cellier C, Carnot F, Landi B, Dusoileil A, Barbier JP. Black esophagus associated with herpes esophagitis. *Gastrointest Endosc* 1999; 49:105-7.
25. Williams DB, Payne SW. Observations on esophageal blood supply. *Mayo Clin Proc* 1982; 57:448-53.
26. Shapiro AL, Robillard GL. The esophageal arteries. *Ann Surg* 1950; 131:171-85.