

## Case report

# Pregnancy and Crohn's Disease: Infliximab induction therapy, Accidental Conception, Pregnancy Outcome and Postpartum Complications

E. Xirouchakis<sup>1</sup>, P. Karantanos<sup>1</sup>, Lemonia Tsartsali<sup>2</sup>, E. Karkatzos<sup>1</sup>

## SUMMARY

Crohn's disease is a well known inflammatory disease of unknown origin. It appears mostly at young ages and the need for a long lasting therapy with immunosuppressing drugs makes decisions about these patients difficult especially when taking into account the need of many female patients to carry out a pregnancy. It is well known that CD exacerbations can provoke adverse effects on the foetus with a great risk of miscarriage. We present a case of a young woman with Crohn's disease under treatment with infliximab who accidentally conceived and was willing to carry out the pregnancy. Since the use of infliximab was not recommended during pregnancy, when the patient presented flare ups she was treated with corticosteroids and 5-ASA in order to achieve remission. The outcome was a spontaneously and successfully terminated pregnancy. During the early post-partum period she also presented a large abdominal cyst that was treated operatively.

**Key words:** Infliximab, inflammatory bowel disease, pregnancy

chronic disease such as Crohn's Disease (CD). It is well known that CD has an adverse effect on the foetus in women with inflammatory bowel disease (IBD) and the risk of a miscarriage is increased by up to 60%.<sup>1,2</sup> Thus, the physician should strive to ensure the disease is quiescent at conception and during pregnancy. A general evaluation of the patient is further complicated by the fact that gynaecologic disorders occur commonly in women with IBD.<sup>3</sup> Considerable overlap in symptoms attributable to gynaecologic disorders, IBD, or both is registered. This fact necessitates good knowledge of the range of gynaecologic problems that women with IBD may experience. The challenge is to identify and correctly associate a gynaecologic condition with IBD so further evaluation and management can be carried out and all possible complications due to IBD or treatment options can be foreseen.<sup>3</sup>

## OUR CASE

Here we present the case of a 23 year old patient with CD who conceived while on infliximab induction treatment. The diagnosis of CD was made initially in January 2002; two months after the patient delivered a healthy, in term child. She was started on conventional therapy but as no remission was induced, it was decided to introduce infliximab in June 2002, at a dose of 5mg/kg followed by 2 doses according to the induction protocol. The 3<sup>rd</sup> dose was administered on September 3, 2002 and the patient was in clinical and laboratory remission thereafter. In October 2002, pregnancy was diagnosed, therefore further infliximab infusions were prohibited due to insufficient data regarding its safety during pregnancy and mesalazine was introduced. The first gynecological ultrasound was done on December 5<sup>th</sup> which indicated a normal, 10 week pregnancy. On December 11<sup>th</sup> 2002 the

## INTRODUCTION

In routine clinical practice, many diagnostic and therapeutic difficulties are encountered when coping with a

<sup>1</sup> 1st IKA Hospital, Department of Gastroenterology, Athens Greece,

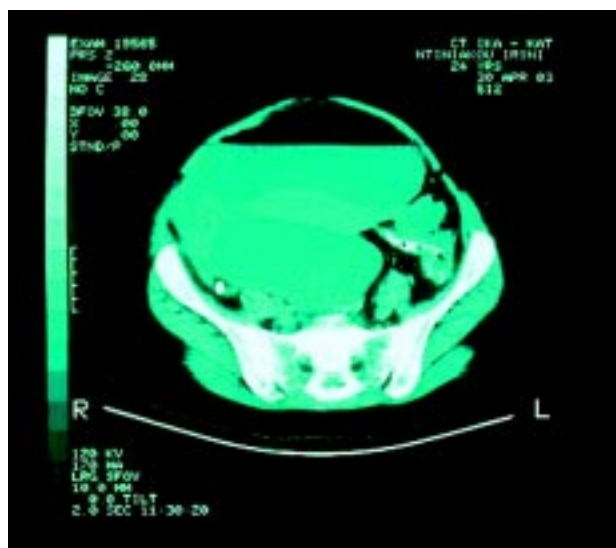
<sup>2</sup> "Agia Sofia" Hospital, University of Athens, First Pediatric Department, Athens Greece

### Author for correspondence:

E. Xirouchakis, M.D., Dept. of Gastroenterology, 1st IKA Hospital, Zaimi Street, 15127 Melissia, Athens, Greece,  
Tel: +30-2108041347, Cell: +30-6932659688,  
Fax: +30-2108041347, e-mail: [elmxir@yahoo.gr](mailto:elmxir@yahoo.gr)

patient was hospitalized due to high fever, ( $>39^{\circ}\text{C}$ ), right lower quadrant abdominal pain and sparse vaginal bleeding. The ultrasound (US) examination performed on Dec.11<sup>th</sup>, revealed thickness of the terminal ileal wall without abscess formation. Inflammatory markers by far exceeded the normal values (CRP = 76mg/l, normal value  $<3.1$ ) upon admission on December 12<sup>th</sup>, 2002, and normalized fully by December the 19<sup>th</sup> after treatment with prednisone, at a starting dose of 40 mg, continued by per os mesalazine 500mg 2x3/24hr. The patient was dismissed in an overall satisfactory condition. At this point the patient refused to be examined by a gynecologist. The US examination performed on 18<sup>th</sup> of February 2003, showed a normal fetal / pregnancy development. (Femur 38mm, BPD: 188mm. AP: 172mm, fetal weight: 477gr, antero-superior placental insertion, gestational weeks (GW) according to US 21 wk + 4 days, no abnormalities were recorded). By the 25<sup>th</sup> GW, the patient exhibited a rise in inflammatory markers and was recommenced on prednisone. During the 29<sup>th</sup> gestational week, the patient returned to our clinic in a febrile state, with signs of acute inflammation, vaginal blood loss, high CRP (130mg/l) and 9270/mm<sup>3</sup> white blood count. She was transferred to a gynecological unit where the pregnancy was spontaneously and successfully terminated on April 13<sup>th</sup>, 2003. She was discharged five days later whereas the newborn was kept for 30 days in the neonatal unit. The patient returned to our clinic on April 29<sup>th</sup>, 2003 with abdominal pain and high fever. The laboratory tests revealed the following: ESR= 108mm/h, CRP=308mg/l, WBC 5850/mm<sup>3</sup>, PLT=337.000/ml, Hgb=11.7g/dl and both US and CT examinations revealed a large inflammatory cyst, originating from the right adnexae as shown in figure 1. She refused immediate laparoscopy/ laparotomy, and returned two days later with signs of acute abdomen and therefore she was treated operatively. Surgery revealed a ruptured purulent, lipoid, inflammatory cyst of the right ovary, with no macroscopic findings indicative of intestinal inflammatory involvement. Biopsy specimen (17X11X2.5cm) microscopically indicated a fibrolipoid cyst with fibrous and granulomatous tissue characterizing acute inflammation. Epithelial and ovarian tissue was not identified and the formation was diagnosed as an abscess.

Since reporting this case, the baby is in a good condition and our patient's disease activity is quiescent. She had only two exacerbations over the last 2.5years expressed with abdominal pain and mild elevations of CRP and leucocytes treated with prednisone at a starting dose of 20mg/die. This case raises important issues relating to the treatment approach, discontinuation of existing treat-



**Figure 1.** The appearance of the large cystic formation as was seen on the CT of the abdomen.

ment schedules and maintenance during pregnancy and the investigation and treatment of flare ups of disease activity. It also raises a question of the interpretation of blood investigations for IBD during pregnancy in the assessment of disease activity. Imaging options are obviously limited and abdominal radiography should only be used in a patient suspected of intestinal obstruction or toxic megacolon. Data as to whether sigmoidoscopy or colonoscopy may be performed are contradictory.<sup>4-8</sup>

Evidence so far suggests that the disease activity is the main adverse factor predisposing to prematurity and low birth weight babies. Drugs such as 5-ASA and sulphasalazine appear to be safe and well tolerated in pregnancy. Steroids up to 40mg are also safe but should be used for exacerbations of active disease. The use of infliximab, a chimeric monoclonal antibody, which neutralizes tumor necrosis factor alpha, during pregnancy and prior to conception is restricted even though no evidence of maternal toxicity, embryotoxicity or teratogenicity was observed in a developmental toxicity study conducted in mice using an analogous antibody that selectively inhibits the functional activity of mouse TNF- $\alpha$  (Centocor, data on file). Recent data show that infliximab administration during pregnancy appears to be safe. Among patients who have received infliximab according to a database maintained by the manufacturer (Centocor Inc), live births occurred in 65%, miscarriages in 17% and therapeutic pregnancy terminations in 22%. There were no discrepancies in comparison to a healthy population.<sup>2</sup>

Clinicians must make a decision as to what drugs to prescribe, as the effects of active inflammation on the foetus are believed to be more harmful than those of the drug treatment necessary to control the disease. Therefore, medication choice depends primarily on personal preference, the severity of the disease and the potential toxicity of a given drug. Stopping a maintenance treatment increases a chance for the need to treat an acute exacerbation. We used prednisolone to treat the acute exacerbation, bearing in mind studies which report both positive and negative outcomes on the foetus.<sup>9-11</sup>

## DISCUSSION

The reason for examining this case is to stress the awareness of the high percentage of female patients who suffer from active CD and are at a reproductive stage. Contemporary diagnostic methods may enable practicing gastroenterologist to distinguish active CD from other pathologic states during pregnancy, promptly diagnose disease flares and follow up such patients. In a pregnant patient with a lower quadrant pain, fever, weight loss and diarrhea, one may suspect enteral infections, acute appendicitis, ovarian cysts, abscesses, renal involvement, malignancies etc. and these must be ruled out. Patients not in remission most likely will exhibit flare ups during pregnancy.<sup>12</sup> Recommendations of routine use of diagnostic methods such as CT, or contrast X-ray are not safe during pregnancy. Colonoscopy could be safe and should be used only in selected patients due to possible adverse premedication drug effects on the foetus as well as due to incomplete safety data of the intervention itself.<sup>13</sup> Magnetic resonance may be highly useful but the cost effectiveness of such an examination in routine practice has not been established.<sup>3,14</sup> Laboratory markers are also altered during pregnancy and cannot be used as absolute parameters. Ultrasound examination may not be helpful in differentiating an ovarian cyst given the size of the uterus even though for determining the existing inflammation of the terminal ileum it has high specificity and sensitivity.<sup>13,15,16</sup> In some reports up to 39% of patients with CD may develop ovarian cysts and 57% of them are treated surgically.<sup>12</sup> In this case it is certain that the cyst did not exist before conception and obviously it occurred after delivery although it is unclear when exactly it appeared and whether it is associated with IBD itself or treatment options (infliximab, prednisone). Therefore, we would like to stress the importance of proper cooperation with other specialties, in this case with gynecologists as many unexpected conditions may be overlooked in the differential diagnosis, and management of patients similar to ours because

of patient in compliance, or due to focusing on the underlying disease or due to unexpected postpartum complications with no evident baseline characteristics.

## REFERENCES

1. Donaldson LB. Crohn's disease: Its gynecologic aspect. *Am J Obstet Gynecol* 1978; 131:196-202.
2. Katz JA, Keenan GF, Snith DE, et al. Outcome of Pregnancy in patients receiving infliximab for the treatment of crohn's disease and rheumatoid arthritis *Gastroenterology* 2003; 124 (4, Suppl.1):Abstr.No63.
3. Weber AM, Ziegler C, Belinson JL, et al. Gynecologic history in women with inflammatory bowel disease. *Obstet Gynecol* 1995; 86:843-847.
4. Mayberry JF, Weterman IT. European survey of fertility and pregnancy in women with Crohn's disease: a case control study by European collaborative group. *Gut* 1986; 27:821-825.
5. Kornfeld D, Cnattinguis S, Ekblom A. Pregnancy outcomes in women with inflammatory bowel disease. A population based cohort study. *Am J Obstet Gynecol* 1997; 177:942-946.
6. Subhani JM, Hamilton MI. Review article: the management of inflammatory bowel disease during pregnancy. *Aliment Pharmacol Ther* 1998; 12:1039-1053.
7. Korelitz BI. Inflammatory bowel disease and pregnancy. *Gastroenterol Clin North Am* 1998; 27:213-224.
8. Connell W, Miller A. Treating inflammatory bowel disease during pregnancy: risks and safety of therapy. *Drug Safety* 1999; 21:311-323.
9. Larzilliere I, Beau P. Chronic inflammatory bowel disease and pregnancy-case control study. *Gastroenterol Clin Biol* 1998; 22:1056-1060.
10. Fonager K, Sorensen HT, Olsen J et al. Pregnancy outcome for women with Crohn's disease. Pregnancy outcome for women with Crohn's disease: a follow-up study based on linkage between national registries. *Am J Gastroenterol* 1998; 93:2426-2430.
11. Bermas BL, Hill JA. Effects of immunosuppressive drugs during pregnancy. *Arthritis Rheum* 1995; 38:1722-1732.
12. Jospe ES, Pepercorn MA. Inflammatory bowel disease and pregnancy: a review. *Dig Dis* 1999; 17:201-207.
13. Cappell MS, Sidhom O, Colon V. A study at ten medical centers of the safety and efficacy of 48 flexible sigmoidoscopies and 8 colonoscopies during pregnancy with follow-up of fetal outcome and with comparison to control groups. *Dig Dis Sci* 1996; 41:2353-2360.
14. Katz JA, Lichtenstein GR, Keenan GF, et al. Outcome of pregnancy in woman receiving remicade (infliximab) for the treatment of Crohn's Disease and Rheumatoid Arthritis. *Gastroenterology* 2001; 120(5, Suppl.1):A-69
15. Baioco PJ, Korelitz BI. The influence of inflammatory bowel disease and its treatment on pregnancy and fetal outcome. *J Clinical Gastroenterol* 1984; 6:211-216.
16. Tarjan Z, Toth G, et al. Ultrasound in Crohn's disease of the small bowel. *Eur Journal of Radiology* 2000; 35:176-182.