

Endoscopic submucosal dissection of duodenal adenocarcinoma arising from Brunner's gland

Hidekazu Tanaka, Shigenaga Matsui, Hiroshi Kashida, Masatoshi Kudo

Kindai University Faculty of Medicine, Japan

A 70-year-old man was admitted to our hospital because of a duodenal submucosal tumor (SMT) that had been detected during screening gastrointestinal endoscopy. The SMT, which was 10 mm in diameter with a small orifice at the top of the lesion, was located in the first part of the duodenum. Histopathology of a biopsy from the orifice gave a diagnosis of adenocarcinoma. Therefore, endoscopic submucosal dissection (ESD) was performed to remove the lesion *en bloc* (Fig. 1). Pathological examination (hematoxylin and eosin staining) of the resected specimen revealed a moderately differentiated tubular adenocarcinoma that had invaded the submucosa, but not the lymphatic vessels or vessels; tumor margins were negative (Fig. 2A,B). Immunohistochemical staining revealed that the carcinoma cells were positive for MUC6 (Fig. 2C), but negative for pepsinogen 1 (Fig. 2D). Thus, this duodenal tumor was confirmed as a duodenal carcinoma arising from Brunner's gland.

Duodenal adenocarcinoma from Brunner's gland is very rare and most cases are treated by surgical resection [1]. Brunner's gland is a mucus-secreting acinar gland located in the submucosa of the duodenum. Therefore, an adenocarcinoma arising from Brunner's gland resembles an SMT. ESD can be

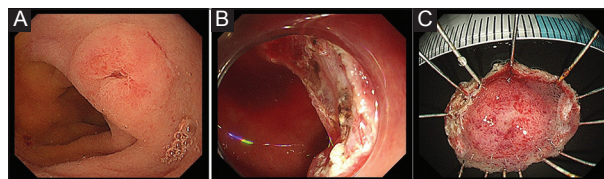


Figure 1 (A) Gastrointestinal endoscopy revealed submucosal tumor with a small orifice in the first part of the duodenum; (B) ulcer after endoscopic submucosal dissection; and (C) specimen

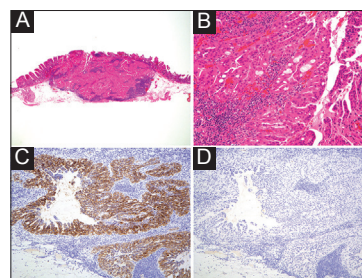


Figure 2 Pathological examination (hematoxylin and eosin staining: (A) $\times 40$, (B) $\times 400$) of the resected specimen revealed a moderately differentiated tubular adenocarcinoma that had invaded the submucosa. (C) Immunohistochemical staining revealed that the carcinoma cells were positive for MUC6, but (D) negative for pepsinogen 1

Department of Gastroenterology and Hepatology, Kindai University Faculty of Medicine, Japan

Conflict of Interest: None

Correspondence to: Shigenaga Matsui, MD, PhD, Department of Gastroenterology and Hepatology, Kindai University Faculty of Medicine, Osaka, Japan, e-mail: ma2i@med.kindai.ac.jp

Received 16 January 2019; accepted 23 January 2019; published online 15 February 2019

DOI: <https://doi.org/10.20524/aog.2019.0363>

a good treatment selection in adenocarcinoma of duodenum from Brunner's gland.

Reference

1. Kamei K, Yasuda T, Nakai T, Takeyama Y. A case of adenocarcinoma of the duodenum arising from Brunner's gland. *Case Rep Gastroenterol* 2013;7:433-437.