

Pneumatosis cystoides intestinalis

Shunsuke Yamamoto^a, Yusuke Takahashi^b, Hisashi Ishida^a

National Hospital Organization Osaka National Hospital, Osaka, Japan

A 70-year-old woman was referred to our hospital for further examinations because of findings from a previous examination. She had undergone colonoscopy at another hospital for fecal incontinence and multiple submucosal lesions had been found in the ascending colon. Colonoscopy showed several spherical or hump-shaped cystic lesions with diameters of 5-30 mm in the ascending colon (Fig. 1). All of them had normal surficial structures without erosions or ulcerations. Abdominal computed tomography revealed air-filled cysts within the bowel wall of the ascending colon (Fig. 2). From these findings, we diagnosed the case as pneumatosis cystoides intestinalis (PCI). The etiology for the disease was unclear in this case. Since the patient did not have any specific symptoms directly related to the disease, we observed her conservatively.

PCI is a rare disease characterized by cysts filled with gas in the intestinal wall. The following are considered as etiological factors for PCI: digestive tract stenosis, obstructive pulmonary disease, abdominal external injury or surgery, immunosuppression, systemic chemotherapy, and malnutrition [1-3]. As regards the pathogenesis, infiltration of intraluminal air into the injured mucosa and an invasion of gas-producing bacteria into the bowel wall have been described [2,3]. There is no standardized treatment strategy for the disease; however, most cases are free of symptoms and therefore can be managed conservatively.

Department of ^aGastroenterology and Hepatology (Shunsuke Yamamoto, Hisashi Ishida); ^bSurgery (Yusuke Takahashi), National Hospital Organization Osaka National Hospital, Osaka, Japan

Conflict of Interest: None

Correspondence to: Shunsuke Yamamoto, MD, PhD, 2-1-14 Houenzaka, Chuo-ku, Osaka, 540-0006, Japan, e-mail: shun0515suke@gmail.com

Received 31 March 2020; accepted 7 April 2020; published online 8 July 2020

DOI: <https://doi.org/10.20524/aog.2020.0524>

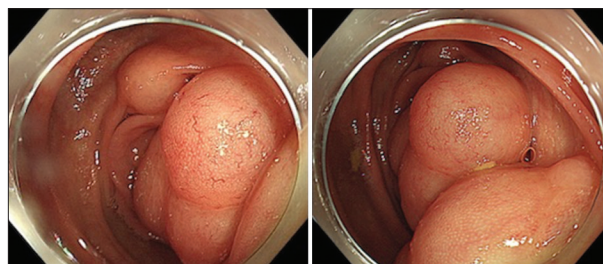


Figure 1 Colonoscopic images of multiple cystic lesions with diameters of 5-30 mm in the ascending colon

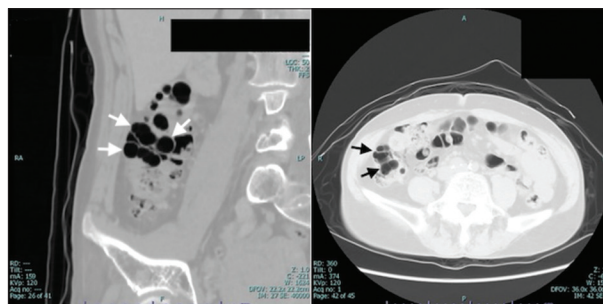


Figure 2 Computed tomography images showing air-filled cysts within the bowel wall of the ascending colon

References

1. Peng FB, Kim HS, Agarwal SK. Abnormal polypoid finding during colonoscopy. *Gastroenterology* 2019;**157**:940-941.
2. Kaechele V, Seufferlein T, Pauls S. Electronic clinical challenges and images in GI. Pneumatosis cystoides intestinalis. *Gastroenterology* 2008;**135**:e4-e5.
3. Ling F, Guo D, Zhu L. Pneumatosis cystoides intestinalis: a case report and literature review. *BMC Gastroenterol* 2019;**19**:176.