

Case report

Late postoperative adult intussusception without tumor related cause: an alternative option in management

I. Pilpilidis, Anthia Gatopoulou, K. Soufleris, A. Tarpagos, I. Katsos

SUMMARY

Introduction and Aims: To present a case of late postoperative bowel obstruction with uncommon etiology, that was successfully reduced during endoscopy. **Description of a case:** We report a case of a 63 year-old man presenting with failure to pass flatus and stool for two days. The patient underwent partial left hemicolectomy due to cancer of the sigmoid colon 5 years ago and an emergency transverse colostomy was performed 2 years ago due to bowel obstruction (megacolon). Six months after colostomy, a diagnostic colonoscopy was performed which revealed a fibrotic stenosis at the site of anastomosis that was corrected performing balloon dilatation. Restoration surgery with closure of colostomy was decided since abdominal computed tomography and laboratory tests confirmed the absence of cancer recurrence. A preoperative control colonoscopy identified a coil-spring polypoid mass with normal mucosa at the level of anastomosis. There was no sign of ischemia and mucosal fold intussusception was suspected. A reduction with balloon dilatation was performed successfully during colonoscopy. After reduction, the anastomosis was revealed with normal appearance of mucosa and the bowel function was corrected. Biopsies taken of the lead point of the obstructive mass confirmed the presence of intestinal mucosa. Mucosal fold intussusception is a rare cause of postoperative bowel obstruction at the site of anastomosis. In these cases, endoscopic balloon dilatation could be proved safe and efficient, avoiding a potentially unnecessary bowel resection.

Key words: Adult intussusception, management

*Theagenio Cancer Hospital, Thessaloniki, Greece
Al. Simeonidi, Rd, 2, 54007 Thessaloniki, Greece*

Author for correspondence:

Anthia Gatopoulou, Al. Simeonidi, Rd 2, Thessaloniki, Greece 54007, e-mail: gatop@otenet.gr

INTRODUCTION

Intussusception occurs when a proximal segment of bowel (intussusceptum) telescopes into the lumen of an adjacent distal segment (intussusciptens).¹

While intussusception is relatively common in children, it is infrequently seen in adults, accounting for only 5% to 16% of all cases.^{2,3} Of particular note is the observation that approximately 90% of cases are secondary to a definable lesion, while the opposite is true in children.⁴

Contrary to the management of the condition in children, treatment in adults is not always clear cut. While most authors agree that surgical resection is mandatory, the extent of resection and whether or not the intussusception should be reduced before resection is controversial.⁴

We report a rare case of late postoperative non-tumor related intussusception that was successfully reduced during endoscopy, in an adult patient, after surgery due to rectosigmoid cancer.

Description of a case

A 63 year-old man presented with abdominal pain and distention, nausea and failure to pass flatus and stool of sudden onset. He had undergone partial left colon surgical resection due to rectosigmoid lesion 5 years earlier and an emergency transverse colostomy was performed 2 years ago due to bowel obstruction (megacolon) Six months after colostomy, a diagnostic colonoscopy was performed which revealed a fibrotic stenosis at the site of anastomosis that was corrected performing balloon dilatation. He had a history of hypertension and obesity.

On admission, the patient's temperature and blood pressure were normal. The abdomen was slightly distended and tender and finger examination found the anorectum to be in its normal fixed position. Laboratory

tests, included white blood count, hemoglobin, platelet count, as well as electrolytes, liver and renal function tests were within normal ranges. Plain abdominal radiographs showed air fluid levels.

The patient had been referred to our hospital for a postoperative follow up routine examination 10 days before the episode took place. Abdominal computed tomography had revealed normal findings and previous colonoscopy indicated diversion colitis of distal segment of bowel and normal appearance of anastomosis. Both examinations, plus the physical one, had confirmed the absence of cancer recurrence.

A new colonoscopy was performed which identified a coil-spring polypoid mass with normal mucosa at the level of anastomosis and a colon-rectal intussusception was suspected. There was no sign suggesting ischemia in the mucosa proximally.

Due to his postoperative condition and the absence of tumor related cause, according to recent examinations, we attempted to proceed with endoscopic reduction. (Figure 1)

After balloon dilatation had been performed during colonoscopy, the anastomosis was revealed with normal mucosa and the bowel function was corrected. (Figure 2)

We had taken biopsies of the lead point of the intussusception that confirmed our suspicion that it was intestinal mucosa. Edema and infiltration of inflammatory cells were detected at the biopsy specimens. After two week follow up, the patient was well and the endoscopy demonstrated no recurrence. (Figure 3)

DISCUSSION

Colon-rectal intussusception is rare in adults and usually happens in the setting of benign or malignant tumor.^{4,5}

Neither reduction nor resection has been universally agreed on as the appropriate treatment for intussusception in an adult patient. The current weight of evidence supports the view that colonic intussusception in adults should be resected, en bloc, given the likelihood of a neoplastic etiology.⁵

In adult patients intussusception can be categorized into four groups, 1/ tumor related, 2/ postoperative, 3/ miscellaneous, 4/ idiopathic.^{6,7} Postoperative intussusception represents an entity different from the usual intussusception presenting de novo in adults.⁸ Likely etiology factors could be the formation of intra-abdominal adhesions, presence of suture lines, use of long intestinal tubes, or abnormalities in motor activity during the post-

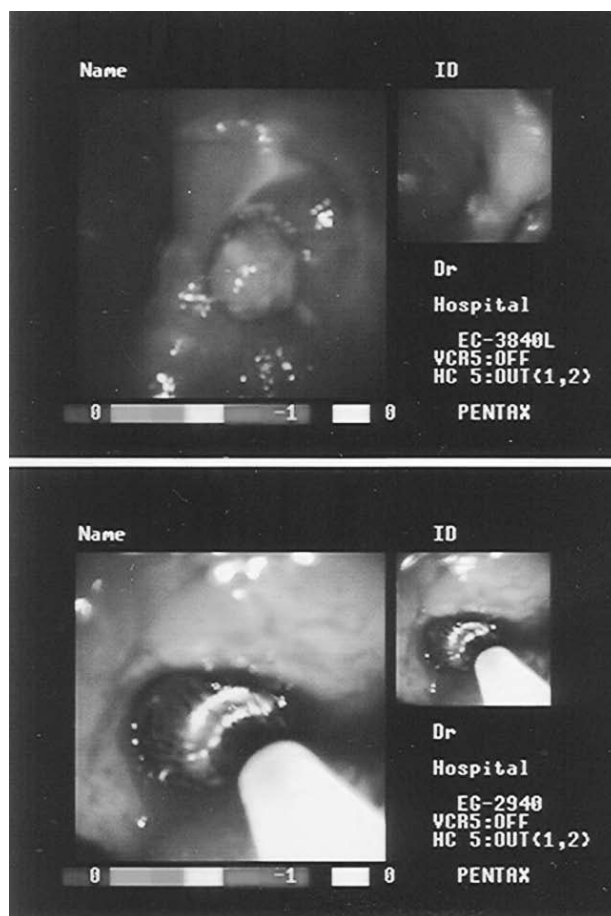


Fig. 1. Coil-spring polypoid mass with normal mucosa at anastomosis and endoscopic reduction

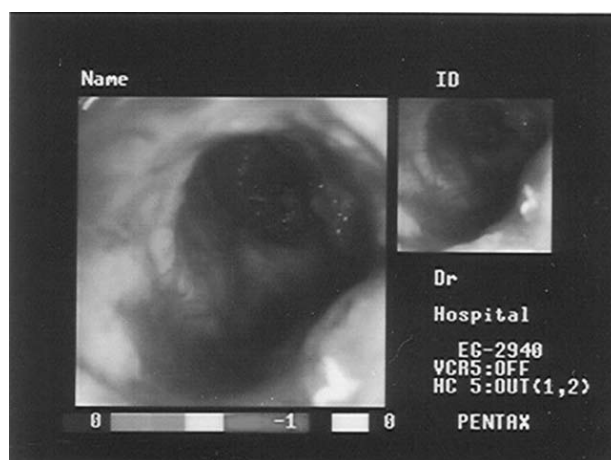


Fig. 2. Anastomosis after endoscopic reduction

operative period. Surgical treatment usually requires reduction of the intussusception and lysis of all accompanying adhesions.⁸

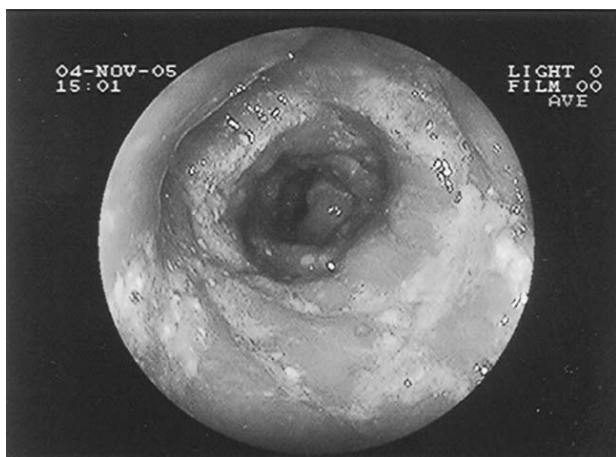

Fig. 3. Two-week endoscopic follow-up

In our case, there was no tumor related cause of bowel obstruction, which is uncommon. It also presents an alternative option in management of such conditions, as it was successfully corrected during endoscopy.

There have been several reports about the utility of endoscopy in the diagnosis and management of colonic intussusception.⁹⁻¹² Despite the fact that some authors warn against colonoscopic reduction, there are few such reports in the literature: Kitamura et al, reported a successful correction of a colonic intussusception caused by lipoma arising from the transverse colon which was later removed by endoscopic polypectomy.¹³ Eu et al also reported a successful reduction of an idiopathic ileocecal intussusception by air insufflation via the colonoscope.¹⁴ In the Begos et al series, there was one case of cecocolic intussusception which was both diagnosed and corrected at colonoscopy, but there is no further reference to the method used.⁴ In our case, a balloon dilatation was performed and there was no surgical resection needed. Kim et al presented a case of sigmoanal intussusception presenting as rectal prolapse.¹⁵ There was no such dilemma in our case because the anorectum was found in its normal position, whereas, in prolapse the entire anorectum can be inverted in continuity with the dentate line.

Biopsies were taken from the lead point of the intussusception, despite the fact that there is no such recommendation because of the high risk of an extended tissue necrosis in the vascularly compromised intussusceptum.⁶⁷

Apart from confirming the diagnosis, colonoscopy also helps in assessing the viability of the mucosa and the possibility of ischemia.

It may, additionally, identify the etiology underlying the intussusception and may reduce it, thereby, occasionally, sparing the patient the need for surgery.^{10,15}

In our case, the appearance of the mucosa was not suggestive of ischemia and therefore did not mandate an operation. This also, did not preclude a safe endoscopic correction. For this reason, an endoscopic reduction was performed.

CONCLUSION

Colonoscopy is helpful in confirming the diagnosis of intussusception and may also be useful in assessing the presence or absence of ischemia. It may not only identify the underlying condition, but also reduce the intussusceptions if no ischemia is suspected and the patient appears to be in a stable clinical condition. In these cases, endoscopic techniques, such as balloon dilatation could prove safe and efficient, avoiding a potentially unnecessary bowel resection.

REFERENCES

1. Turnage R. H, Berger P. Intestinal obstruction and ileus. In Sleisenger and Fordtran's Gastrointestinal and Liver Disease 6th EdN. Saunders Co, Philadelphia 1998, 1807
2. Taraneh A, David LB. Adult intussusception *Ann Surg* 1997;226:134-138
3. Leon KE, John DC, Arrhur HA. Intussusception in adults: institutional review. *Jam Coll Surg* 1999; 188:390-395
4. Begos D, Sandor A, Modlin IM. The diagnosis and the management of adult intussusception *Am J Surg* 1997; 173: 88-94
5. Yamazali T, Okamoto H, Suda T et al. Intussusception in an adult after colonoscopy. *Gastrointest Endosc* 2000; 53: 356-357
6. Wei PL, Yu SC, Lee WJ, Wei TC. Intussusception in adults—a report of 11 cases. *J Surg Assoc* 1996;29:115-119
7. Ren PL, Huang JC, Shin JS, Huang CY, Fang TH. Jejunojejunogastric Intussusception: a rare Intussusception in an adult patient after surgery. *Gastrointest Endosc* 2002; 56: 296-298
8. Sarr MG, Nargorney DM, McIlrath. DC. Postoperative intussusception in an adult: a previously unrecognized entity? *Arch Surg* 116; 2: 144-148
9. Forde KA, Gold RP, Holck S, Goldberg MD, Kaim PS. Giant pseudopolypoid colitis with colonic Intussusception in an adult *Gastroenterology* 1978;75:1142-1148.
10. Goldin E, Libson E. Intussusception in intestinal lymphoma: the role of endoscopy, *Postgrad Med J* 1986; 62: 1139-1140
11. Hurwitz KM, Gertker SL. Colonoscopic diagnosis of ileocolic intussusception. *Gastrointest Endosc* 1986; 32: 217-218
12. Omori H, Asahi H. Intussusception adults: a 21-year experience in the university-affiliated emergency center and indication for nonoperative reduction. *Dig Surg* 2003; 20:433-439
13. Kitamura K, Kitagawa S, Mori M, Haraguchi. Endoscopic correction of intussusception and removal of a colonic lipoma. *Gastrointest Endosc* 1990; 36: 509-511
14. Eu KW, Seow C, Goh HS. Cecal mass on barium enema

- study- a case for routine colonoscopy. *Singapore Med J* 1994;35:321-322
15. Younes Z, Johnson D, Dimick L. Sigmoid-anal intussusception presenting as rectal prolapse: a role of endoscopic diagnosis. *Gastrointest Endosc* 1998; 47: 561-563
16. Chang FY, Cheng JT, Lai KH. Colonoscopic diagnosis of ileocolic intussusception in an adult. *Safr Med J* 1990; 77:313-314.