

## Case report

## Endoscopic Balloon Dilatation of NSAID-Induced Sigmoid Diaphragm-Stricture

Georgia Lazaraki<sup>1</sup>, G. Chatzimavroudis<sup>2</sup>, I. Pilpilidis<sup>1</sup>, D. Paikos<sup>1</sup>, K. Soufleris<sup>1</sup>, I. Triantafillidis<sup>2</sup>, Anthi Gatopoulou<sup>1</sup>, P. Katsinelos<sup>2</sup>

### SUMMARY

A less common but increasingly recognized complication of NSAIDs use is thin mucosal “diaphragm-like” strictures that were initially reported in the small intestine and have been reported with increased incidence in the colon. A patient with osteoarthritis, chronic low back pain, and overuse of different types of NSAIDs suppositories developed “diaphragm” like stricture in the sigmoid colon. She underwent successful through the scope balloon dilatation of the stricture. We report this case to demonstrate an endoscopic alternative therapeutic approach to “diaphragm-like” strictures and as a reminder that this diagnosis should be suspected in patients on long-term NSAIDs therapy.

**Key words:** Non-steroidal anti-inflammatory drugs (NSAIDs), “diaphragm”-like colonic stricture, balloon dilatation.

### INTRODUCTION

Non-steroidal anti-inflammatory drugs (NSAIDs) have become the most widely used medications in the world.<sup>1</sup> Although the stomach and duodenum have been the main focus in published reports of NSAIDs-induced GI damage, more recently there has been recognition of NSAIDs associated adverse events on the colon.<sup>2</sup> Lower gastrointestinal tract lesions subsequent to NSAIDs use range from solitary or multiple erosions or ulcers to proctitis or

pancolitis simulating inflammatory bowel disease.<sup>3,4</sup> The first cases of diaphragm-like lesions due to NSAIDs use have been described in the small intestine<sup>5</sup> but accumulating data suggest that NSAIDs are associated with similar lesions in the large intestine also.<sup>6-15</sup>

We present the case of a middle aged woman with a history of long-term use of different types of NSAIDs who developed diaphragm-like stricture in the sigmoid colon and was successfully treated with through the scope balloon dilatation.

### Case Report

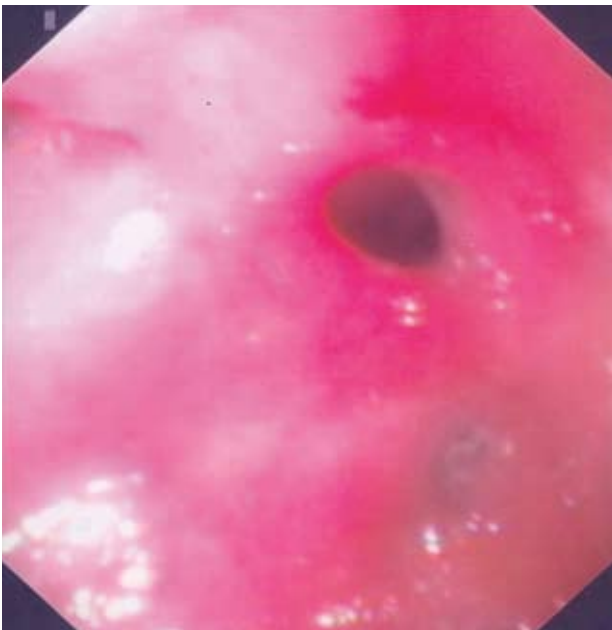
A 58-year-old overweight white woman was referred for colonoscopy from a nearby hospital. The patient had been admitted at the department of Internal medicine complaining for diffuse abdominal pain and constipation for last six months. She underwent a barium enema which showed a short-length stenosis in the sigmoid colon. Medical history revealed hypertension, severe osteoarthritis and chronic low-back pain. She reported the use of different types of NSAIDs preferring the suppository form in the last five years. These included piroxicam, sulindac, naproxen, diclofenac sodium, indomethacin and nimesulid. Physical and rectal examination was unremarkable.

Laboratory studies revealed a hemoglobin of 11.2 g/dl (normal values 12-14 g/dl) with low ferritin and ferrum plasma levels and a normal white cell count and platelets count. Serum electrolytes, renal and liver biochemical tests were normal. Upper GI endoscopy was unremarkable. At colonoscopy, in the sigmoid, shortly after the rectosigmoidal angle, a circumferential membranous-like stenosis with narrow oval opening in the center, 8 mm diameter, was demonstrated [Figure 1]. The mucosa lining the diaphragmatic lesion was not friable or ulcerated. Histology of the stricture revealed normal mucosa with localized submucosal fibrosis.

<sup>1</sup>Department of Gastrointestinal Oncology, Theagenion Cancer Hospital, Thessaloniki, Greece, <sup>2</sup>Department of Endoscopy and Motility Unit, “Georgios Gennimatas” General Hospital, Thessaloniki, Greece

#### Author for correspondence:

Dr Panagiotis Katsinelos, Department of Endoscopy and Motility Unit, “Georgios Gennimatas” General Hospital, Ethnikis Aminis 41 str, 54635 Thessaloniki, Greece, Phone:+302310963341 FAX:+302310210401, e-mail:akis\_katsinelos@yahoo.gr



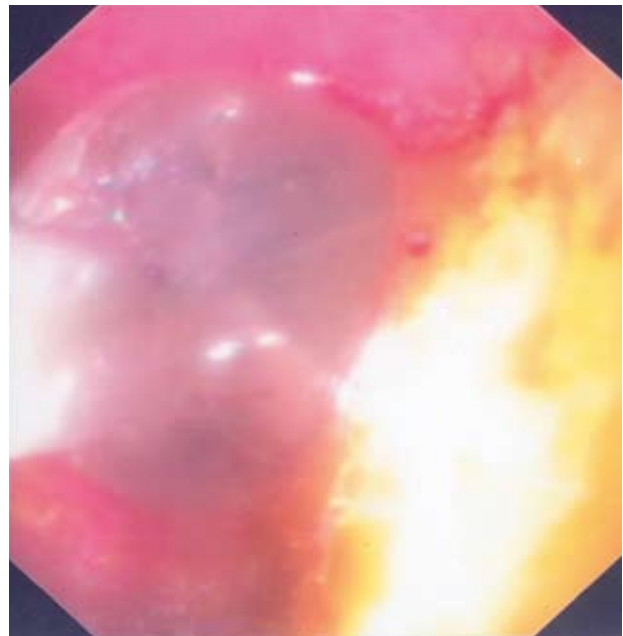
**Fig. 1.** Endoscopic view of a diaphragm-like stricture in the sigmoid colon. The stricture diameter was less than 1 cm.

After a detailed discussion with our patient about the benefits and risks of balloon dilatation, she agreed to undergo endoscopic treatment and a consent form was signed. At repeated colonoscopy, the diaphragm-like stricture was originally dilated with an 18 mm TTS balloon (Microvasive Endoscopy, Boston Scientific Corporation) but further endoscope introduction through the stenosis was unsuccessful. We decided to proceed with a balloon of diameter 25 mm, knowing the increased risk of perforation [Figure 2]. A dilatation of 20 mm was achieved [Figure 3], allowing the colonoscope to be advanced to the cecum. Colonic mucosa of the descending colon over the stenosis, transverse, ascending and up to the cecum looked normal. The patient noted resolution of abdominal pain and constipation. NSAIDs were discontinued and one year later the patient is free of symptoms reporting use of non-NSAIDs analgesic agents only.

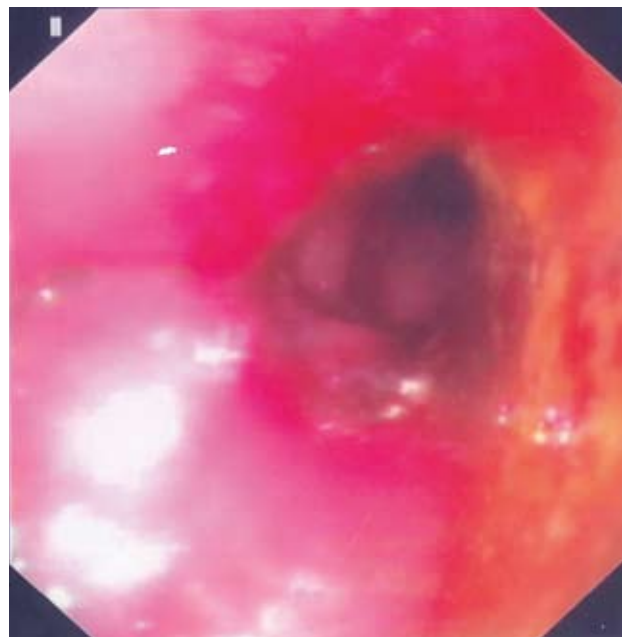
## DISCUSSION

NSAIDs deleterious side effects in the upper gastrointestinal tract are a well known entity occurring in approximately 25% of patients<sup>2, 16, 17</sup>. The ability of these drugs to injure small intestinal and colonic mucosa and the incidence of drug related colonic disease is underestimated. Cases of small bowel strictures associated with NSAIDs have been reported since 1970.<sup>1</sup> However, not until 1987<sup>5</sup> was the term “diaphragm disease” used.

The first case of diaphragm-like strictures in the colon of a patient on long-term NSAIDs was described as recently as 1989. Since then, many cases<sup>5-16</sup> of colonic diaphragm-like strictures have been reported in patients on long-term use of NSAIDs. Large bowel diaphragms are



**Fig. 2.** Endoscopic view of dilated balloon across the stricture.



**Fig. 3.** After dilatation of the diaphragm-like stricture with 25 mm balloon dilator.

considered by some investigators to be pathognomonic of NSAIDs-induced damage. These lesions consist of thin septal-like diaphragms with or without well circumscribed ulcers or superficial ulcerations at their margins, and normal intervening mucosa unrecognizable from the serosal surface. The diaphragm-like colonic strictures are the same as those that occur in small bowel NSAIDs disease.

Mechanisms underlying the induction of colonic damage by NSAIDs remain unclear although prostaglandin synthesis inhibition is the most important.<sup>17-19</sup> Other factors such as increased lysosomal fragility, local irritation, and impaired oxidative phosphorylation may also be involved. In resection specimens, they have been shown to be composed of a shelf-like circumferential fold of fibrotic submucosa, almost as if a focal ring of muscularis mucosa had been drawn tight like a purse string, pulling the submucosa toward the center of the lumen of the bowel.<sup>14</sup> There is no mucosal hyperplasia or dysplasia.

The reason for the development of diaphragm-like strictures mainly in the cecum and ascending colon and rarely in other colonic parts remains obscure. NSAIDs exert their effects on gut mucosa either locally or systemically. Local damage is a more likely explanation and one can assume that the intra-luminal NSAIDs concentration is an important factor. The localization of a unique lesion in the sigmoid colon in our patient could be explained by topical action of the drug because she preferred to use NSAIDs in the suppository form. This hypothesis is also advocated by Smith et al. These investigators reported a series of 24 patients with diaphragm-strictures disease of which 15 were under extended-release suggesting there is an association between NSAIDs concentration in the colon and diaphragm formation.<sup>7</sup>

The treatment of choice of benign NSAIDs-induced diaphragm like strictures in most reported cases<sup>5,8-11,13,14</sup> has been segmental resection of the involved colon along with NSAIDs discontinuation. If possible, the morbidity and mortality associated with surgery should be avoided. In our patient, dilatation was a good option since there was a unique lesion in the sigmoid colon. The thickness of the bowel wall in the sigmoid, along with normal appearing colon mucosa, reduced the risk of colon perforation. Given the sustained success of endoscopic dilatation in our case and that of Gopal et al<sup>12</sup> and Smith et al<sup>7</sup> and the low complication rate of endoscopic procedures in general, it would seem that endoscopic balloon dilatation plus discontinuation of the offending NSAIDs should be the initial treatment of choice in cases of NSAIDs-induced diaphragm disease.

In conclusion, this case report reinforces the point that “diaphragm”-colonic stricture can be a manifestation of frequent NSAIDs use and through the scope balloon dilatation is a safe, effective and alternative option to surgery treatment.

## REFERENCES

1. Bjarnason I, Hayllar J, MacPherson AJ, Russell AS. Side effects of nonsteroidal anti-inflammatory drugs on the small and large intestine in humans. *Gastroenterology* 1993; 104:1832-1847.
2. Bernsdorff KR, Agrawal RM, Brodmerkel GJ Jr. Nonsteroidal anti-inflammatory drugs: gastroduodenal injury and beyond. *Dig Dis* 1995; 13:251-266.
3. Katsinelos P, Christodoulou K, Pilpilidis I, Xiarchos P, Pappagiannis A, Dimiropoulos S, Amperiadis P, Vasiliadis T, Tarpagos A, Katsos I, Eugenidis N. Colopathy associated with the systemic use of nonsteroidal antiinflammatory medications. An underestimated entity. *Hepatogastroenterology* 2002; 49:345-348.
4. Kurahara K, Matsumoto T, Iida M, Honda K, Yao T, Fujishima M. Clinical and endoscopic features of nonsteroidal anti-inflammatory drug-induced colonic ulcerations. *Am J Gastroenterol* 200; 96:473-480.
5. Lang J, Price AB, Levi AJ, Burke M, Gumpel JM, Bjarnason I. Diaphragm disease: pathology of disease of the small intestine induced by non-steroidal anti-inflammatory drugs. *J Clin Pathol* 1988; 41:516-526.
6. Huber T, Ruchti C, Halter F. Nonsteroidal antiinflammatory drug-induced colonic strictures: a case report. *Gastroenterology* 1991; 100:1119-1122.
7. Smith JA, Pineau BC. Endoscopic therapy of NSAID-induced colonic diaphragm disease: two cases and a review of published reports. *Gastrointest Endosc* 2000; 52:120-125.
8. Eis MJ, Watkins BM, Philip A, Welling RE. Nonsteroidal-induced benign strictures of the colon: a case report and review of the literature. *Am J Gastroenterol* 1998; 93:120-121.
9. Byrne MF, McGuinness J, Smyth CM, Manning DS, Sheehan KM, Bohra SG, Patchett SE, Murray FE. Nonsteroidal anti-inflammatory drug-induced diaphragms and ulceration in the colon. *Eur J Gastroenterol Hepatol* 2002; 14:1265-1269.
10. Hooker GD, Gregor JC, Ponich TP, McLarty TD. Diaphragm-like strictures of the right colon induced by indomethacin suppositories: evidence of a systemic effect. *Gastrointest Endosc* 1996; 44:199-202.
11. Aloysius MM, Kaye PV, Lobo DN. Non-steroidal anti-inflammatory drug (NSAID)-induced colonic strictures and perforation: a case report. *Dig Liver Dis* 2006; 38:276-278.
12. Gopal DV, Katon RM. Endoscopic balloon dilatation of multiple NSAID-induced colonic strictures: case report and review of literature on NSAID-related colopathy. *Gastrointest Endosc* 1999; 50:120-123.
13. Haque S, Haswell JE, Dreznick JT, West AB. A cecal dia-

- phragm associated with the use of nonsteroidal anti-inflammatory drugs. *J Clin Gastroenterol* 1992; 15:332-335.
14. Pucius RJ, Charles AK, Adair HM, Rowe RC, Hacking JC. Diaphragm-like strictures of the colon induced by non-steroidal anti-inflammatory drugs. *Br J Surg* 1993;80:395-396.
  15. Fellows IW, Clarke JM, Roberts PF. Non-steroidal anti-inflammatory drug-induced jejunal and colonic diaphragm disease: a report of two cases. *Gut* 1992; 33:1424-1426.
  16. Sheers R, Williams WR. NSAIDs and gut damage. *Lancet* 1989; 2:1154.
  17. Bjorkman DJ. Nonsteroidal anti-inflammatory drug-induced gastrointestinal injury. *Am J Med* 1996; 101:25S-32S.
  18. Davies NM. Toxicity of nonsteroidal anti-inflammatory drugs in the large intestine. *Dis Colon Rectum* 1995; 38:1311-1321.
  19. Bjarnason I, Macpherson AJ. Intestinal toxicity of non-steroidal anti-inflammatory drugs. *Pharmacol Ther* 1994; 62:145-157.