

Jejunal cavernous lymphangioma: successful endoscopic treatment of a rare cause of small bowel bleeding

Mafalda João^a, Elisa Gravito-Soares^b, Sandra Lopes^b, Pedro Amaro^b

Instituto Português de Oncologia de Coimbra; Centro Hospitalar e Universitário de Coimbra, Portugal

We report a symptomatic bowel lymphangioma, successfully treated by endoscopic resection during enteroscopy [1]. A 29-year-old woman, with no relevant medical history, presented with melena and severe microcytic anemia (hemoglobin 5.5 g/dL; mean corpuscular volume 68.4 fL). Esophagogastroduodenoscopy and colonoscopy were non-diagnostic. Small bowel capsule endoscopy revealed a lesion with whitish surface and “strawberry-like” mucosa, and fresh blood at the proximal jejunum (Fig. 1A). A push enteroscopy confirmed an actively oozing 12-mm soft sessile lesion at the proximal jejunum (Fig. 1B,C), excised by endoscopic mucosal resection (Fig. 2A-C). Histopathologic examination revealed large dilated lymphatic channels, often connected to normal-caliber adjacent lymphatic spaces consistent with a cavernous lymphangioma (Fig. 2D). At 2-month follow up, the patient remains asymptomatic with stable hemoglobin levels.

Small bowel lymphangiomas are exceedingly rare tumors. Although benign, they can become symptomatic, causing gastrointestinal bleeding, intussusception or protein-losing enteropathy. Endoscopically, they present as polypoid lesions with a white-yellow surface and “strawberry-like” mucosa, reflecting the edematous mucosa along with multiple hemorrhagic red spots. The optimal treatment is radical excision, mostly surgical, given the multiplicity and large size of these lesions and their potential for invasion of surrounding tissues. Endoscopic resection has rarely been reported and should be considered as a minimally invasive treatment option.

^aGastroenterology Department, Instituto Português de Oncologia de Coimbra (Mafalda João); ^bGastroenterology Department, Centro Hospitalar e Universitário de Coimbra (Elisa Gravito-Soares, Sandra Lopes, Pedro Amaro), Portugal

Conflict of Interest: None

Correspondence to: Mafalda Cainé João, Gastroenterology Department, Instituto Português de Oncologia de Coimbra, Coimbra, Portugal, Av. Bissaya Barreto, no 98, 3000-075, Coimbra, Portugal, mafaldacaine@gmail.com

Received 25 May 2021; accepted 7 June 2021; published online 14 September 2021

DOI: <https://doi.org/10.20524/aog.2021.0662>

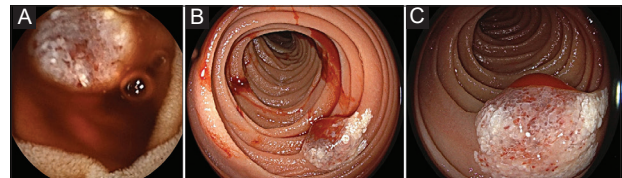


Figure 1 (A) Capsule endoscopy revealing a lesion with whitish surface and “strawberry-like” mucosa, and fresh blood at the proximal jejunum. (B and C) Push enteroscopy showing an actively oozing 12-mm soft sessile lesion

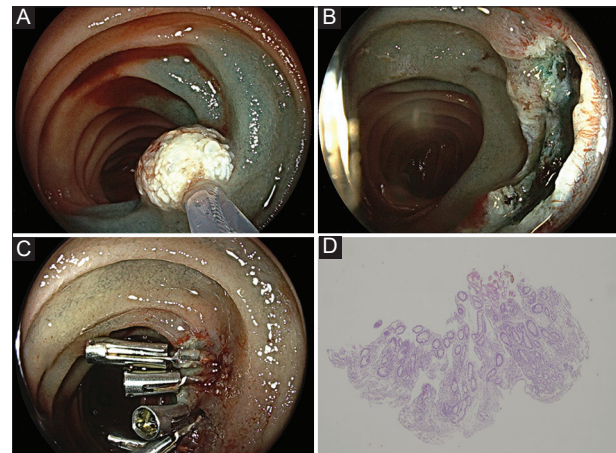


Figure 2 (A) Endoscopic mucosal resection after submucosal injection with diluted epinephrine 1:100 in normal saline stained with methylene blue. (B) Scar after lesion resection. (C) Scar prophylactically closed with through-the-scope clips. (D) Histopathologic examination revealing large dilated lymphatic channels, often connected to normal-caliber adjacent lymphatic spaces consistent with a cavernous lymphangioma

Reference

1. Bucciero F, Marsico M, Galli A, Tarocchi M. Small bowel lymphangioma: a rare case of intestinal bleeding. *Dig Liver Dis* 2015;47:815.