

Efficacy of lumen-apposing metal stents for the management of benign gastrointestinal stricture: a systematic review and meta-analysis

Suprabhat Giri^a, Arun Vaidya^b, Aditya Kale^b, Vaneet Jearth^c, Sridhar Sundaram^d

Nizam's Institute of Medical Sciences, Hyderabad; Seth GS Medical College and KEM Hospital, Mumbai; Postgraduate Institute of Medical Education & Research, Chandigarh; Tata Memorial Hospital, Mumbai, India

Abstract

Background Lumen-apposing metal stents (LAMS) are an evolving option for the management of benign gastrointestinal (GI) strictures. Multiple studies have reported on the efficacy and safety of LAMS for benign GI strictures, but were limited by their small sample size. Hence, we conducted this meta-analysis to assess the critical role of LAMS for the management of benign GI strictures.

Methods A literature search of various databases from inception until October 2022 was conducted for studies evaluating the outcome of LAMS in patients with benign GI strictures. The outcomes assessed included technical and clinical success, adverse events including stent migration, and reintervention. Pooled event rates across studies were expressed with summative statistics.

Results A total of 18 studies (527 patients) were included in the present analysis. The pooled event rates for technical, short-term and long-term clinical success were 99.9% (95% confidence interval [CI] 99.1-100.0), 93.9% (95%CI 90.7-100.0), and 72.8% (95%CI 55.7-90.0), respectively. The pooled incidence of adverse events and stent migration with LAMS for benign GI strictures was 13.5% (95%CI 8.6-18.5) and 10.6% (95%CI 6.0-15.2), respectively. The pooled event rate for reintervention with LAMS for GI strictures was 23.0% (95%CI 15.7-30.3). In a subgroup analysis focusing only on anastomotic strictures there was no significant difference in the pooled event rates for various outcomes.

Conclusions LAMS have a high technical and short-term clinical success rate, with an acceptable safety profile for the management of benign GI strictures. Further studies are needed to determine the appropriate duration of stent therapy and long-term outcomes.

Keywords Lumen-apposing metal stents, endoscopic stenting, gastrointestinal strictures, meta-analysis
Ann Gastroenterol 2023; 36 (5): 524-532

^aDepartment of Gastroenterology, Nizam's Institute of Medical Sciences, Hyderabad (Suprabhat Giri); ^bDepartment of Gastroenterology, Seth GS Medical College and KEM Hospital, Mumbai (Arun Vaidya, Aditya Kale); ^cDepartment of Gastroenterology, Postgraduate Institute of Medical Education & Research, Chandigarh (Vaneet Jearth); ^dDepartment of Digestive Diseases and Clinical Nutrition, Tata Memorial Hospital, Mumbai (Sridhar Sundaram), India

Conflict of Interest: None

Correspondence to: Dr. Sridhar Sundaram, Associate Professor, Department of Digestive Diseases and Clinical Nutrition, Tata Memorial Hospital, Mumbai, Parel, 400012, India, e-mail: drsridharsundaram@gmail.com

Received 24 January 2023; accepted 24 May 2023; published online 3 July 2023

DOI: <https://doi.org/10.20524/aog.2023.0819>

This is an open access journal, and articles are distributed under the terms of the Creative Commons Attribution-NonCommercial-ShareAlike 4.0 License, which allows others to remix, tweak, and build upon the work non-commercially, as long as appropriate credit is given and the new creations are licensed under the identical terms

Introduction

Benign gastrointestinal (GI) luminal strictures can occur as a result of peptic ulcers, caustic ingestion, chronic inflammation, radiation and surgical anastomosis [1]. Endoscopic dilatation using balloons or bougies has typically been used to treat benign GI strictures. Even with the inclusion of steroid injection, endoscopic dilatation therapy necessitates multiple sessions and is associated with stricture recurrence, apart from the risk of bleeding and perforation [2]. Fully covered self-expandable metal stents have gained popularity in refractory and recurrent strictures, and are used mostly in the esophagus. However, they have a high incidence of migration, even when fixed with clips or sutures [3,4].

Lumen-apposing, fully covered, self-expanding metal stents (LAMS) were first developed to facilitate endoscopic transluminal drainage and are commonly used to treat pancreatic fluid collections [5,6]. They subsequently received approval for bile duct drainage in failed endoscopic retrograde

cholangiopancreatography, malignant distal biliary obstruction cases, and gallbladder drainage in non-surgical patients [7]. In practice, the application of LAMS has expanded beyond the indications provided in the device's labeling, including enteric anastomosis, drainage of post-surgical collections, and benign GI luminal strictures [7,8]. The LAMS provides several benefits, such as 3 different diameters (10 mm, 15 mm, and 20 mm), a saddle-shaped design that provides an anchorage via its wide flanges, reducing migration risk, and a simple stepwise deployment technique that enables great technical success [7]. There are still limited data regarding the clinical performance of LAMS placement in benign GI strictures, with only a few case series and small-sized studies available. Hence, we conducted this meta-analysis to determine the efficacy, safety and outcomes of LAMS in treating various benign GI strictures.

Materials and methods

Information source and database search

The electronic databases of MEDLINE, Embase, and Scopus were searched from inception to October 2022 for all relevant studies, using the keywords: ((Stricture OR Strictures OR Stenosis OR Stenoses OR Narrowing) AND ((LAMS) OR ((Lumen OR Luminal OR Lumen-apposing [tiab]) AND (Metal [tiab] OR Metallic [tiab]) AND (Stent [tiab] OR Stents [tiab])))). Initially, 2 independent reviewers did a screening of the titles and abstracts of studies retrieved using the search strategy. Two researchers independently assessed the eligibility of the studies before including them. The bibliography of the included studies was also searched for relevant studies. A third reviewer resolved any disagreement. The study methodology was designed and executed to adhere to the Preferred Reporting Items for Systematic review and Meta-Analyses (PRISMA) guidelines [9].

Study inclusion

Studies included in this analysis were prospective and retrospective studies fulfilling the following criteria: (a) study population: patients with benign gastrointestinal strictures (both anastomotic and *de novo*); (b) intervention: LAMS placement for stricture; and (c) outcomes: efficacy and safety of LAMS. Studies with a sample size <5, review articles, correspondence and editorials were excluded. Studies without relevant clinical data or incomplete data were also excluded.

Data extraction and quality assessment

The collected data were entered into a structured form by 2 reviewers. The form contained the following parameters for each study: first author, year of publication, country, number of

patients, age and sex, details of stricture, type of stent placed, outcome measures, and duration of follow up. A modified Newcastle-Ottawa scale was used for quality assessment of the included studies [10]. A third independent individual was consulted in case of any discrepancy.

Definition of outcomes

The technical success of the procedure was determined by the successful placement of the stent across the stricture, as shown on fluoroscopy. Short-term clinical success was defined as symptom improvement or resolution with the indwelling LAMS in place. Long-term clinical success was defined as symptom improvement or resolution following LAMS removal, without the requirement for additional interventions. After the initial clinical success, redevelopment of obstructive symptoms requiring repeat endoscopic or surgical procedure was defined as reintervention.

Statistical analysis

The pooled proportions were computed using a random-effects inverse-variance model. Before statistical analysis, a continuity correction of 0.5 was applied when the incidence of an outcome was zero in a study. I^2 and P-value were used for the assessment of heterogeneity. $P < 0.10$ was statistically significant, while I^2 values of <50%, 50% to 75%, and >75% were considered to indicate low, moderate, and significant heterogeneity, respectively. The presence of significant heterogeneity reduces the certainty of evidence. A sensitivity analysis was performed using a "leave-one-out" approach to investigate each study's influence on the overall effect-size estimate and identify influential studies. A publication bias assessment was conducted by evaluating funnel plot asymmetry and quantified using Egger's test. The meta-analysis was performed using Stata 17.0 software package (Stata Corp LP, College Station, TX, USA).

Results

Baseline study characteristics and quality assessment

A total of 2318 records were identified from the search strategy and 18 studies were included in the final analysis. Fig. 1 shows the PRISMA flowchart for the study selection and inclusion process. Table 1 shows the baseline characteristics of the included studies. The majority of the studies were from the USA, and only 2 studies were prospective [11,25]. Tables 2 and 3 summarize the clinical characteristics and clinical outcomes of the included studies, respectively. The proportion of patients with anastomotic strictures varied from 40-100%. A majority of the patients had failed prior endoscopic therapy, in the form of endoscopic balloon dilatation with or without

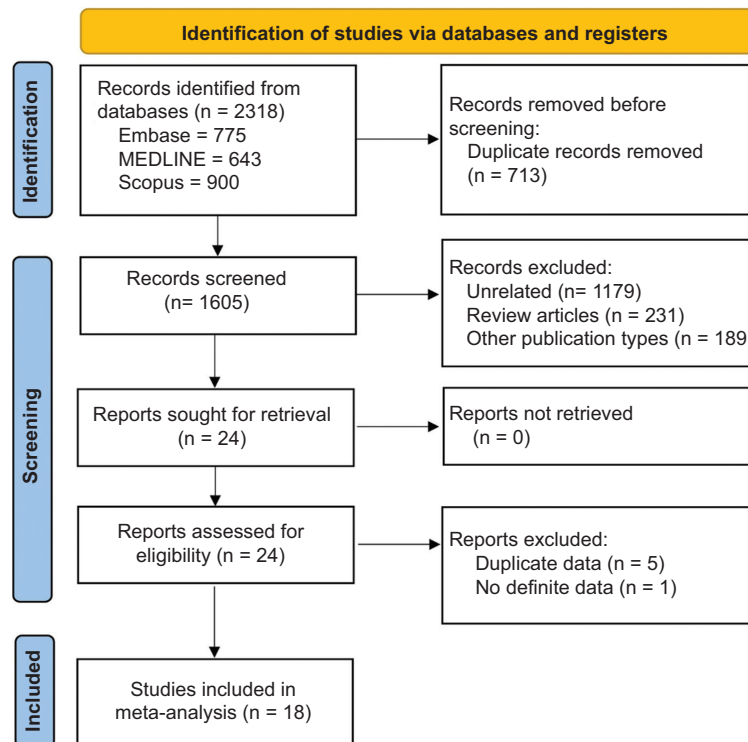


Figure 1 PRISMA flowchart for study identification and selection process

Table 1 Baseline characteristics of the included studies

Author, year [ref.]	Country	No. of centers	Study design	No. of patients	Mean age, in years	Male/female
Arain 2015 [11]	USA	Multicenter	Prospective	11	-	2/9
Mazumder 2016 [12]	USA	Single	Retrospective	5	47.4	1/4
Bazerbachi 2017 [13]	USA	Multicenter	Retrospective	49	51.4	28/21
Fernandez 2017 [14]	Spain, USA	Multicenter	Retrospective	21	62.6	10/11
Irani 2017 [15]	USA	Multicenter	Retrospective	25	54	7/18
Tyberg 2017 [16]	USA	Multicenter	Retrospective	17	55	6/11
Yang 2017 [17]	USA	Multicenter	Retrospective	30	51.6	11/19
Hallac 2018 [18]	USA	Single	Retrospective	15	70	7/8
Jirapinyo 2018 [19]	USA	Single	Retrospective	18	54	-
Packey 2018 [20]	USA	Multicenter	Retrospective	17	62	5/12
Simsek 2019 [21]	USA	Single	Retrospective	9	47	2/7
Gajula 2020 [22]	USA	Multicenter	Retrospective	11	-	5/6
Gollol 2020 [23]	USA	Single	Retrospective	19	50.7	8/11
Mizrahi 2021 [24]	USA	Multicenter	Retrospective	51	60.3	20/31
Skidmore 2021 [25]	Australia	Single	Prospective	14	-	-
Choi 2022 [26]	USA	Single	Retrospective	37	62	14/23
Ichkhanian 2022 [27]	Multicenter	Multicenter	Retrospective	33	57	7/26
Mahmoud 2022 [28]	USA	Single	Retrospective	109	54.3	35/74

steroid injection, fully-covered self-expanding metal stent insertion or stricturotomy. A 15×10-mm LAMS was the most commonly used stent, with median stent dwell time varying

from 60-119 days. Our study quality assessment found that 11 were of medium quality [14-18,21,22,24,26-28] and 7 were of low quality [11-13,19,20,23,25] (Supplementary Table 1).

Table 2 Clinical characteristics of the included studies

Author, year [ref.]	No. of patients	Location of stricture						Stricture type		Previous treatment	Median follow up
		EG	GD	GJ	P	Co	Other	An	Non-An		
Arain 2015 [11]	11	-	6	4	-	-	1	5	6	-	-
Mazumder 2016 [12]	5	-	-	2	2	1	-	3	2	EBD: 2, FCSEMS: 1	90 days
Bazerbachi 2017 [13]	49	2	-	17	7	7	16	38	11	EBD: 38, EBD+steroid injection: 2, FCSEMS: 13	
Fernandez 2017 [14]	21	-	-	-	-	2	19	14	7	16 (EBD-14, cSEMS-3, stricturoplasty-1)	119 days
Irani 2017 [15]	25	4	-	13	6	-	2	18	7	EBD: 20, Dilation (3) with intralesional steroids (2), needle knife (1), FCSEMS: 1	301 days
Tyberg 2017 [16]	17	-	-	-	3	1	13	17	-	EBD: 17, steroid injection: 2, enteral stent: 9, PEGJ: 2	246.4 days
Yang 2017 [17]	30	5	-	15	3	7	-	25	5	27 (EBD: 27, FCSEMS: 7)	100 days
Hallac 2018 [18]	15	3	6	3	3	-	-	6	9	Endoscopic dilations: 37	299 days
Jirapinyo 2018 [19]	18	-	-	18	-	-	-	18	-	Endoscopic dilations: 18	7 months
Packey 2018 [20]	17	4	-	1	4	4	4	10	7	Endoscopic dilations: 14, FCSEMS: 3	-
Simsek 2019 [21]	9	-	-	6	1	-	2	6	3	Endoscopic dilations: 9	171 days
Gajula 2020 [22]	11	6	-	5	-	-	-	11	-	-	2-3 months
Gollol 2020 [23]	19	-	-	8	4	0	7	8	11	Endoscopic dilations	
Mizrahi 2021 [24]	51	10	-	11	17	1	12	21	30	33 (EBD: 27, EBD+steroid injection: 14, Needle knife: 2, FCSEMS: 6)	173.8 days
Skidmore 2021 [25]	14	-	-	14	-	-	-	14	-	-	
Choi 2022 [26]	37	5	-	15	8	-	9	27	10	EBD: 17, EBD+steroid: 7, FCSEMS: 1	386 days
Ichkhanian 2022 [27]	33	-	-	33	-	-	-	33	-	-	334 days
Mahmoud 2022 [28]	109	2	-	60	7	14	26	91	18	EBD: 77, FCSEMS: 10, steroid injection: 3, needle knife: 2, revision surgery: 4	668.5 days

EG, esophagogastric; GD, gastroduodenal; GJ, gastrojejunal; P, pylorus; Co, colonic; An, anastomotic; Non-An, non-anastomotic; EBD, endoscopic balloon dilation; FCSEMS, fully covered self-expandable metal stents

Technical success

A total of 18 studies with 527 patients reported the outcome of technical success with LAMS for benign GI strictures. The pooled technical success rate was 99.9% (95% confidence interval [CI] 99.1-100.0; $I^2=0.0\%$) (Supplementary Fig. 1).

Clinical success

A total of 15 studies (450 patients) and 9 studies (239 patients) reported the outcomes of short-term and long-term clinical success, respectively. The pooled short-term clinical success rate was 93.9% (95%CI 90.7-100.0; $I^2=39.0\%$) (Supplementary Fig. 2), while the pooled long-term clinical success rate was 72.8% (95%CI 55.7-90.0; $I^2=94.4\%$) (Supplementary Fig. 3).

Adverse events (AEs) and risk of migration

The incidence of AEs was reported by 14 studies (n=483). The pooled incidence of AEs with LAMS for benign GI strictures was 13.5% (95%CI 8.6-18.5) (Supplementary Fig. 4). Table 4 summarizes the details of AEs along with their pooled incidence rates. Overall, 16 studies (n=511) reported on the outcome of LAMS migration. The pooled incidence of LAMS migration in benign GI strictures was 10.6% (95%CI 6.0-15.2) (Supplementary Fig. 5).

Reintervention

The requirement for reintervention was reported by 11 studies (418 patients). The pooled event rate for reintervention

Table 3 Clinical outcomes of included studies

Author, year [ref.]	Stricture length, in mm	Procedural time, min	Stent dwell time	Type of stent	Technical success	Clinical success	Adverse events	Reintervention
Arain 2015 [11]	-	-	62 days	AXIOS 15 × 10 mm	11/11	10/11	-	4 (LAMS replacement)
Mazumder 2016 [12]	-	-	-	AXIOS 15 × 10 mm	5/5	5/5	-	-
Bazerbachi 2017 [13]	10.53	46.8	100.6 days	10 × 15 mm: 55, 10 × 10 mm: 1	56/56 (100%)	54/56 (96.4%)	Pain 2, Bleeding 2, Infection 1, Occlusion 3, Adjacent stricture 6, Migration 10	17 (balloon dilation 6, surgical resection 2, replaced with LAMS 5, replaced with Soleus stent 2, replaced with WallFlex stent 1, surgical Hegart dilation 1)
Fernandez 2017 [14]	-	-	107.2 days	AXIOS 10 × 10 mm: 2 and 15 × 10 mm: 16, NAGI 16 mm × 30 mm	21/21 (100%)	Short-term 19/21 (90.5%), Long-term 12/18 (66.7%)	Migration 4	-
Irani 2017 [15]	-	-	92 days	10 × 10 mm: 3, 15 × 10 mm: 25	25/25 (100%)	15/25 (60%)	Migration 2, 4 (pain 2, bleeding 1, proximal stricture 2)	-
Tyberg 2017 [16]	-	3.8	81.2 days	10 × 10 mm: 2, 15 × 10 mm: 15	17/17 (100%)	17/17 (100%), Long-term 16/16 (100%)	Migration 2, bleeding 1, infection (aspiration pneumonia) 1	Balloon dilation 1, replacement of another LAMS 1
Yang 2017 [17]	8	12.8	60 days	10 × 10 mm: 1, 15 × 10 mm: 29	29/30 (96.7%)	27/30 (90%) Long-term 19/23 (82.6%)	Bleeding 1, perforation 1, pain 1, aspiration pneumonia 1 migration 2	Repeat stent placement 3, surgical 1
Hallac 2018 [18]	-	14.7	-	AXIOS 15 × 10 mm, 10 × 10 mm	15/15 (100%)	11/15 (73.5%)	Migration 1 chest pain 1 abdominal pain 1 obstructive jaundice from stent pressure 1	Surgical revision 1, surgical vertical band gastroplasty removal 1 esophagogastric anastomosis duodenal segment dilation 2
Jirapinyo 2018 [19]	-	-	-	10 × 10 mm, 15 × 10 mm	18/18 (100%)	17/18 (94%)	GI bleed 2, stent migration 2, stent occlusion 2	Needle knife electroincision 1

(Contd...)

Table 3 (Continued)

Author, year [ref.]	Stricture length, in mm	Procedural time, min	Stent dwell time	Type of stent	Technical success	Clinical success	Adverse events	Reintervention
Packey 2018 [20]	<10	-	57 days	15 × 10 mm	17/17 (100%)	15/17 (88.2%)	Stent migration 2	-
Simsek 2019 [21]	-	52	110.7 days	15 × 10 mm: 4, 20 × 10 mm: 5	9/9 (100%)	9/9 (100%)	Regurgitation and pyrosis 1	-
Gajula 2020 [22]	-	-	-	15 mm × 10 mm: 10 20 mm × 10 mm: 1	11/11 (100%)	5/11 (45.4%)	None	-
Gollol 2020 [23]	-	-	-	20 × 10 mm: 4, 15 × 10 mm: 15, 10 × 10 mm: 2	19/19 (100%)	13/15 (86.7%)	None	-
Mizrahi 2021 [24]	8.3	17.5	71.7 days	15 × 10 mm, 20 × 10 mm	61/61 (100%)	Short-term 56/61 (91.8%), Long-term 18/61 (29.5%)	Stent migration 8, pain 4, occlusion 3, bleeding 1, stricture formation 1	19 (EBD 9, surgical intervention 5). New LAMS 11
Skidmore 2021 [25]	-	-	-	-	14/14 (100%)	12/14	Migration 5, chest pain 2	Surgery 2, repeat stenting 5
Choi 2022 [26]	-	-	70 days	10 × 10 mm: 1, 15 × 10 mm: 36	36/37 (97.3)	22/37 (59.5%)	Migration 4, pain 2, bleeding 1, proximal stricture 2	Surgical revision 5
Ichkhanian 2022 [27]	10	-	-	-	33/33 (100%)	26/33 (78%)	4 (Migration -2, pain-2)	Balloon dilatation-4, surgery-1, FCSEMS-2
Mahmoud 2022 [28]	10.8	-	119 days	10 × 10 mm: 3, 10 × 15 mm: 125	128/128 (100%)	126/128 (98.4%)	Pain 13, new adjacent stricture 12, bleeding 5, perforation 2, occlusion 2, infection 1, pancreatitis 1, migration 35	Balloon dilatation 15, surgery 7, LAMS 15, Soleus stent 1, Niti-s stent 1, modified double pigtail stent 1, wall flex stent 1, surgical Hegart dilation 1

EBD, endoscopic balloon dilation; FCSEMS, fully covered self-expandable metal stents

with LAMS for GI strictures was 23.0% (95%CI 15.7-30.3) (Supplementary Fig. 6).

Publication bias and sensitivity analysis

Visual assessment of the funnel plots did not show any evidence of publication bias for the outcomes, except for short-term and long-term clinical success (Supplementary Fig. 7). The “leave-one-out” sensitivity analysis did not show any significant difference in the event rate of various outcomes.

We separately analyzed the outcome of LAMS for anastomotic strictures, which did not show any significant difference in the pooled event rates (Table 5).

Discussion

Treating benign GI luminal strictures can be challenging using conventional endoscopic modalities, such as endoscopic balloon dilation, intralesional steroid injection, needle-knife

Table 4 Summary of adverse events associated with lumen apposing metal stents for benign luminal strictures

Adverse events	No. of studies (No. of patients)	Pooled event rate	Heterogeneity, I^2
Periprocedural			
Bleeding	15 studies (n=450)	2.3% (0.7-3.9)	4.4%
Pain	12 studies (n=400)	5.7% (3.3-8.0)	49.0%
Perforation	15 studies (n=450)	0.1% (0.0-1.0)	0.0%
Infection	9 studies (n=324)	0.9% (0.0-2.1)	37.2%
Pancreatitis	1 study (n=109)	0.8%	-
Pyrosis	1 study (n=9)	11.1%	-
Delayed			
Occlusion	9 studies (n=346)	1.8% (0.1-3.5)	55.4%
Stricture	8 studies (n=332)	4.0% (0.8-7.3)	80.0%
Ulceration	7 studies (n=176)	0.5% (0.0-2.4)	35.7%
Angulation	1 study (n=21)	9.5%	-
Fistula into adjacent organ	1 study (n=109)	1.8%	-
Obstructive jaundice	1 study (n=15)	6.6%	-

Table 5 Summary of findings for use of lumen apposing metal stents for benign luminal strictures

Findings	Overall			Anastomotic strictures		
	No. of studies (patients)	Event rate (95%CI)	I^2	No. of studies (patients)	Event rate (95%CI)	I^2
Technical success	18 studies (n=527)	99.9% (99.1-100)	0.0%	17 studies (n=344)	99.9% (98.8-100)	0.0%
Short-term clinical success	15 studies (n=450)	93.9% (90.7-100)	39.0%	13 studies (n=299)	94.6% (90.6-98.7)	44.5%
Long-term clinical success	9 studies (n=239)	72.8% (55.7-90.0)	94.4%	6 studies (n=102)	76.9% (61.1-92.8)	79.8%
Adverse events	14 studies (n=483)	13.5% (8.6-18.5)	59.9%	11 studies (n=296)	14.4% (7.1-21.6)	66.3%
Migration	16 studies (n=511)	10.6% (0.6-15.2)	64.9%	10 studies (n=284)	13.3% (6.5-20.0)	60.1%
Reintervention	11 studies (n=418)	23.0% (15.7-30.3)	67.8%	6 studies (n=166)	31.0% (11.7-50.3)	88.5%

CI, confidence interval

incision, or a combination of these. Refractory benign GI strictures are now more frequently treated with stents like fully covered self-expandable metal stents, which are effective in dilating the stricture but have a high migration rate. In 2012, the FDA approved the first LAMS for treating pancreatic pseudocysts endoscopically [29]. In practical experience, around one third of patients undergo LAMS placement for off-label use in benign strictures due to the broader flange providing anchorage and reducing the risk of migration [30]. This meta-analysis provided an excellent opportunity to assess the technical and clinical outcomes and safety of LAMS in benign GI strictures.

This meta-analysis revealed a high technical success rate (99.9%) irrespective of stricture etiology, type, site in the GI tract and/or stent size. Simple deployment techniques and expert endoscopists placing the LAMS attributed to high technical success [7,31]. Overall, short-term and long-term clinical success rates were 93.9% and 72.8%, respectively. High clinical success rates can be attributed to the anchoring

mechanism with a dumbbell-shaped design, a fully covered nature of the stent, and a larger diameter, producing apposition between the 2 lumens, thereby reducing the likelihood of stent migration, enabling a longer indwell duration and increasing patient tolerance [31,13]. In a previous meta-analysis on the outcome of endoscopic stenting in Crohn's disease (CD)-related GI strictures (both anastomotic and non-anastomotic), the pooled clinical success rate was 71.3% [32]. In another meta-analysis by Mohan *et al*, LAMS demonstrated statistically better outcomes regarding clinical success and stent migration compared with SEMs [8].

Stent migration is a widely recognized limitation of conventional SEMs in treating benign GI strictures. In a previous systematic review and meta-analysis on the outcome of stent placement in refractory benign esophageal strictures, the migration rate was reported to be 28.6% (95%CI 21.9-37.1) [33]. The reported migration rate of SEMs in patients with CD-related stricture also remains as high as 32% [32]. The migration rate reported with LAMS in the present

meta-analysis was 10.6% (95%CI 0.6-15.2). Hence, based on a high clinical efficacy and lower reported migration rate, LAMS may be a preferred option over SEMs for short-segment stricture. However, there is a need for further comparative studies before recommending one above the other.

Despite the high short-term clinical success, the overall reintervention rate with LAMS was as high as 23%. After the use of fully covered self-expandable metal stents for refractory benign esophageal strictures, the reintervention rate was 38.9% [33]. Tan *et al* [34] conducted a meta-analysis to evaluate the efficiency and safety of LAMS in treating benign strictures, including 6 studies and 144 patients, while the present analysis included a total of 18 studies with 527 patients. Tan *et al* reported high pooled technical success (98.3%) and clinical success (73.8%) rates, which were similar to our results. We also evaluated the pooled short-term clinical success and reintervention rates, which were not reported in the previous meta-analysis [34]. Tan *et al* reported an AE rate of 30.6% in their meta-analysis. Overall, AEs were seen in 13.5% of patients in the present study. Thus, with increasing expertise, the incidence of AEs with the use of LAMS is declining.

Our study showed high technical (99.9%) and short-term (94.6%) success rates, with few AEs (14.4%), when LAMS were used for anastomotic strictures. Although revisional surgery has a high clinical success rate for anastomotic strictures, it is associated with high postoperative morbidity and mortality [28]. Therefore, LAMS placement can be viewed as an alternative option after failed endoscopic dilatation in anastomotic strictures before surgery. Patients with recalcitrant strictures who are not surgical candidates, or who have had unsuccessful revisional surgery, can also be considered for LAMS placement.

The majority of the studies used an Axios stent with a short length of 10 mm. Hence, the utility of LAMS for longer strictures remains a matter of debate. Most studies have used the 15 mm diameter LAMS, while only a few have reported the use of 10-mm and 20-mm diameter Axios stents. The larger diameter stents have smaller flanges. While there are no data to suggest that larger diameter stents may have a higher risk of migration and reintervention than smaller diameter stents, further studies are required to compare the outcomes with different stent sizes for refractory strictures of the GI tract.

The strength of the present analysis was the absence of significant heterogeneity concerning a majority of the outcomes. Nevertheless, we recognized several limitations to the present analysis. First, there were no randomized control trials, and the majority of studies were retrospective. Second, details of the etiologies (malignant vs. benign) when resection and anastomosis were performed were unavailable for the majority of the studies. Third, we could not compare LAMS with other available therapies for managing benign GI strictures. Fourth, we could not perform a cost-effectiveness analysis of LAMS, because the relevant data were not available. Lastly, we could not analyze the optimal stent dwell time that would yield optimal long-term clinical success.

In conclusion, LAMS can be considered as an option for treating refractory benign GI strictures of short length. The present meta-analysis showed a high pooled technical and

short-term clinical success rate, with an acceptable safety profile. However, the present level of evidence for the use of LAMS in benign GI strictures remains low. Further studies of the use of LAMS in patients with refractory strictures will allow us to determine the appropriate duration of stent therapy and help improve long-term outcomes.

Summary Box

What is already known:

- Lumen-apposing metal stents (LAMS) are increasingly being used for the management of short-segment benign gastrointestinal (GI) strictures
- However, the previously reported pooled success rate varied from 70-80%, with the rate of adverse events (AEs) being as high as 30%
- Data on the need for reintervention on follow up were also limited

What the new findings are:

- The pooled short-term, and long-term clinical success rates for LAMS in the treatment of benign GI strictures were 93.9% and 72.8%, respectively
- The pooled incidence of AEs and stent migration with LAMS for benign GI strictures were 13.5% and 10.6%, respectively
- LAMS for GI strictures was associated with a 23.0% pooled event rate for reintervention in the form of endoscopic or surgical therapy
- There has been an increase in the clinical success rate of LAMS for benign GI strictures, with a fall in the rate of AEs, probably due to an increase in endoscopists' expertise

References

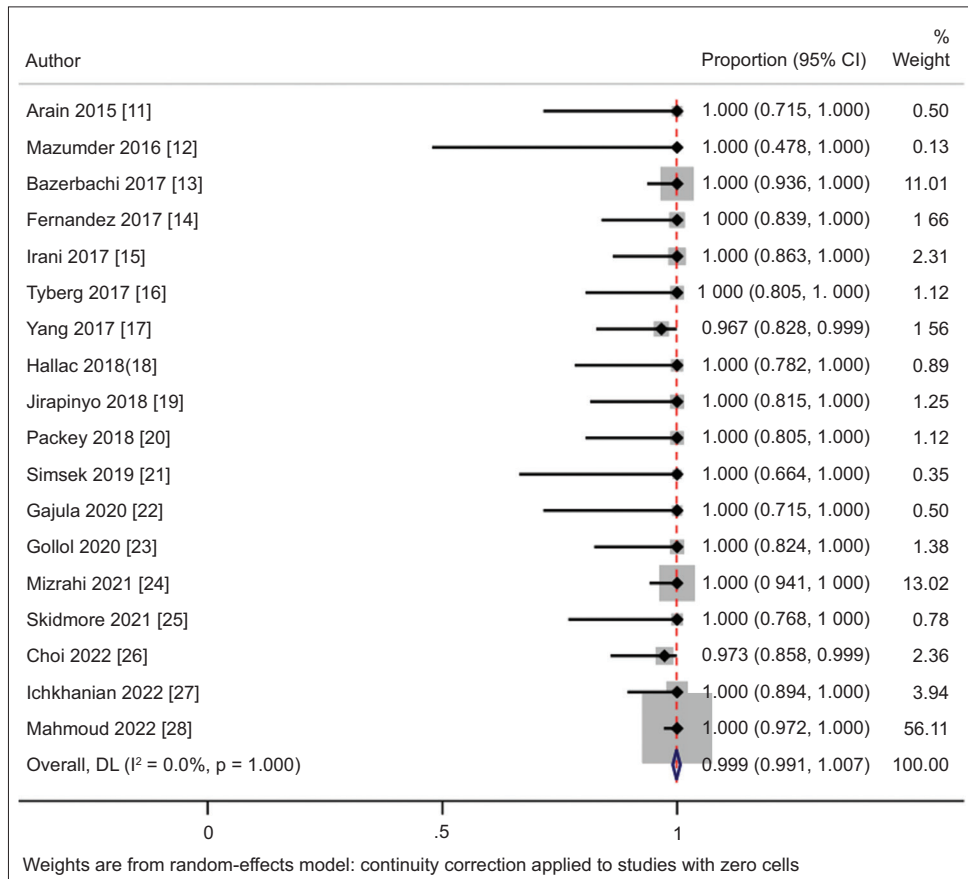
1. Kochhar R, Kochhar S. Endoscopic balloon dilation for benign gastric outlet obstruction in adults. *World J Gastrointest Endosc* 2010;**2**:29-35.
2. Pereira-Lima JC, Ramires RP, Zamin I Jr, Cassal AP, Marroni CA, Mattos AA. Endoscopic dilation of benign esophageal strictures: report on 1043 procedures. *Am J Gastroenterol* 1999;**94**:1497-1501.
3. Hirdes MM, Siersema PD, Vleggaar FP. A new fully covered metal stent for the treatment of benign and malignant dysphagia: a prospective follow-up study. *Gastrointest Endosc* 2012;**75**:712-718.
4. Fujii LL, Bonin EA, Baron TH, Gostout CJ, Wong Kee Song LM. Utility of an endoscopic suturing system for prevention of covered luminal stent migration in the upper GI tract. *Gastrointest Endosc* 2013;**78**:787-793.
5. Binmoeller KE, Shah J. A novel lumen-apposing stent for transluminal drainage of nonadherent extraintestinal fluid collections. *Endoscopy* 2011;**43**:337-342.
6. Walter D, Will U, Sanchez-Yague A, et al. A novel lumen-apposing

- metal stent for endoscopic ultrasound-guided drainage of pancreatic fluid collections: a prospective cohort study. *Endoscopy* 2015;**47**:63-67.
7. Bhenswala P, Lakhana M, Gress FG, Andalib I. Novel uses of lumen-apposing metal stents: a review of the literature. *J Clin Gastroenterol* 2021;**55**:641-651.
 8. Mohan BP, Chandan S, Garg R, et al. Lumen-apposing metal stents, fully covered self-expanding metal stents, and biodegradable stents in the management of benign GI strictures: a systematic review and meta-analysis. *J Clin Gastroenterol* 2019;**53**:560-573.
 9. Page MJ, McKenzie JE, Bossuyt PM, et al. The PRISMA 2020 statement: an updated guideline for reporting systematic reviews. *BMJ* 2021;**372**:n71.
 10. Stang A. Critical evaluation of the Newcastle-Ottawa scale for the assessment of the quality of nonrandomized studies in meta-analyses. *Eur J Epidemiol* 2010;**25**:603-605.
 11. Arain MA, Nabiha SS, Amateau SK, et al. Novel use of a removable lumen apposing metal stent (LAMS) for management of gastroduodenal and bariatric anastomotic strictures. *Gastrointest Endosc* 2015;**81**:AB452-AB453.
 12. Majumder S, Buttar NS, Gostout C, et al. Lumen-apposing covered self-expanding metal stent for management of benign gastrointestinal strictures. *Endosc Int Open* 2016;**4**:E96-E101.
 13. Bazerbachi F, Heffley JD, Abu Dayyeh BK, et al. Safety and efficacy of coaxial lumen-apposing metal stents in the management of refractory gastrointestinal luminal strictures: a multicenter study. *Endosc Int Open* 2017;**5**:E861-E867.
 14. Santos-Fernandez J, Pajji C, Shakhathreh M, et al. Lumen-apposing metal stents for benign gastrointestinal tract strictures: An international multicenter experience. *World J Gastrointest Endosc* 2017;**9**:571-578.
 15. Irani S, Jalaj S, Ross A, Larsen M, Grimm IS, Baron TH. Use of a lumen-apposing metal stent to treat GI strictures (with videos). *Gastrointest Endosc* 2017;**85**:1285-1289.
 16. Tyberg A, Nieto J, Gabr MM, Gaidhane M, Kahaleh M. Lumen apposing metal stents for anastomotic stricture: a new alternative. *Gastrointest Endosc* 2017;**85**:AB498.
 17. Yang D, Nieto JM, Siddiqui A, et al. Lumen-apposing covered self-expandable metal stents for short benign gastrointestinal strictures: a multicenter study. *Endoscopy* 2017;**49**:327-333.
 18. Hallac A, Srikureja W, Liu E, Dhumal P, Thatte A, Puri N. Economical effect of lumen apposing metal stents for treating benign foregut strictures. *World J Gastrointest Endosc* 2018;**10**:294-300.
 19. Jirapinyo P, Ge PS, Young JY, Ryou M, Thompson CC. Efficacy of lumen-apposing metal stents in the treatment of gastrojejunal anastomotic stenosis. *Gastrointest Endosc* 2018;**87**:AB295.
 20. Packey CD, Doukides TP, Khan A, et al. Role for lumen-apposing metal stents in the management of short-length gastrointestinal strictures. *Gastrointest Endosc* 2018;**87**:AB400-AB401.
 21. Simsek C, Ichkhanian Y, Fayad L, et al. Secured lumen-apposing fully covered metallic stents for stenoses in post-bariatric surgery patients. *Obes Surg* 2019;**29**:2695-2699.
 22. Gajula P, Raza A, Patel K, DaVee T, Dacha S. The use of lumen apposing metal stents in benign strictures. *Gastrointest Endosc* 2020;**91**:AB287.
 23. Gollol Raju NS, Kratzer MC, Mudireddy PR. Lumen apposing metal stent for gastrointestinal strictures: experience from a tertiary care center. *Gastrointest Endosc* 2020;**91**:AB292.
 24. Mizrahi M, Fahmawi Y, Merritt L, et al. Luminal-apposing stents for benign intraluminal strictures: a large United States multicenter study of clinical outcomes. *Ann Gastroenterol* 2021;**34**:33-38.
 25. Skidmore AP. Use of lumen-apposing metal stents (LAMS) in the management of gastro jejunostomy stricture following roux-en-y gastric bypass for obesity: a prospective series. *BMC Surg* 2021;**21**:314.
 26. Choi JH, Kozarek RA, Larsen MC, et al. Effectiveness and safety of lumen-apposing metal stents in endoscopic interventions for off-label indications. *Dig Dis Sci* 2022;**67**:2327-2336.
 27. Ichkhanian Y, Agha YH, Manivannan A, et al. Balloon dilation vs. lumen apposing metal stent for the management of post roux- en-y gastric bypass (RYGB) gastro-jejunal anastomotic stricture (GJAS): a multicenter comparative study. *Gastrointest Endosc* 2022;**95**:AB6-AB7.
 28. Mahmoud T, Beran A, Bazerbachi F, et al. Lumen-apposing metal stents for the treatment of benign gastrointestinal tract strictures: a single-center experience and proposed treatment algorithm. *Surg Endosc* 2023;**37**:2133-2142.
 29. Itoi T, Binmoeller KE, Shah J, et al. Clinical evaluation of a novel lumen-apposing metal stent for endosonography-guided pancreatic pseudocyst and gallbladder drainage (with videos). *Gastrointest Endosc* 2012;**75**:870-876.
 30. Hindryckx P, Degroote H. Lumen-apposing metal stents for approved and off-label indications: a single-centre experience. *Surg Endosc* 2021;**35**:6013-6020.
 31. Jain D, Patel U, Ali S, Sharma A, Shah M, Singhal S. Efficacy and safety of lumen-apposing metal stent for benign gastrointestinal stricture. *Ann Gastroenterol* 2018;**31**:425-438.
 32. Giri S, Gopan A, Sundaram S, Kale A. Efficacy and safety of endoscopic stenting for Crohn's disease related strictures: a systematic review and meta-analysis. *Korean J Gastroenterol* 2022;**80**:177-185.
 33. Fuccio L, Hassan C, Frazzoni L, Miglio R, Repici A. Clinical outcomes following stent placement in refractory benign esophageal stricture: a systematic review and meta-analysis. *Endoscopy* 2016;**48**:141-148.
 34. Tan S, Zhong C, Huang S, et al. Clinical outcomes of lumen-apposing metal stent in the management of benign gastrointestinal strictures: a systematic review and meta-analysis. *Scand J Gastroenterol* 2019;**54**:811-821.

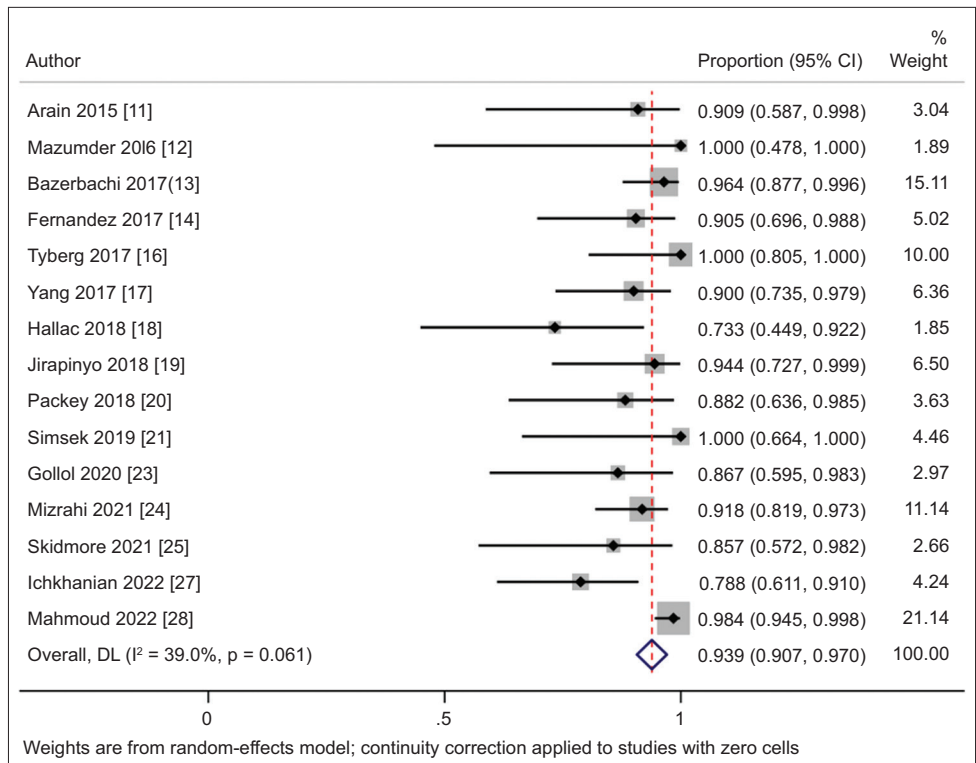
Supplementary material

Supplementary Table 1 Assessment of study quality

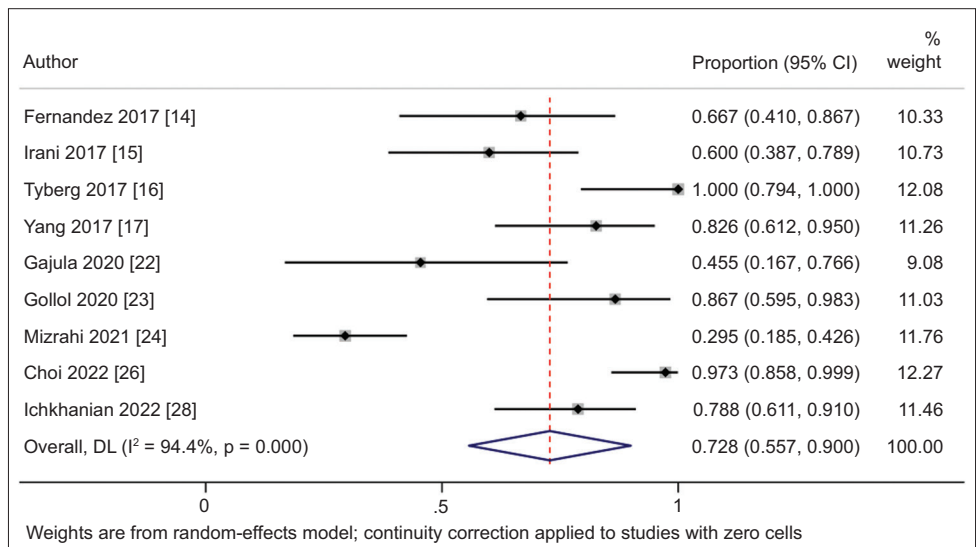
Study, year [ref.]	Representative of the average adult in the community	Cohort size	Type of study	Definite information on technical and clinical success	Information reported on adverse events	Length of follow up	Adequacy of follow up	Total
Arain 2015 [11]	0	0	1	1	1	0	0	3: Low
Mazumder 2016 [12]	0	0	0	0.5	0	1	1	2.5: Low
Bazerbachi 2017 [13]	0.5	1	0	1	1	0	0	3.5: Low
Fernandez 2017 [14]	0.5	0.5	0	1	1	1	1	5: Medium
Irani 2017 [15]	0.5	0.5	0	1	1	1	1	5: Medium
Tyberg 2017 [16]	0.5	0.5	0	1	1	1	1	5: Medium
Yang 2017 [17]	0.5	0.5	0	1	1	1	1	5: Medium
Hallac 2018 [18]	0	0.5	0	1	1	1	1	4.5: Medium
Jirapinyo 2018 [19]	0	0.5	0	1	1	1	0	3.5: Low
Packey 2018 [20]	0.5	0.5	0	1	1	0	0	3: Low
Simsek 2019 [21]	0	0	0	1	1	1	1	4: Medium
Gajula 2020 [22]	0.5	0	0	1	1	1	1	4.5: Medium
Gollol 2020 [23]	0	0.5	0	1	1	0	0	2.5: Low
Mizrahi 2021 [24]	0.5	1	0	1	1	1	1	5.5: Medium
Skidmore 2021 [25]	0	0	1	0.5	1	0	0	2.5: Low
Choi 2022 [26]	0	1	0	1	1	1	1	5: Medium
Ichkhanian 2022 [27]	0.5	1	0	1	1	1	1	5.5: Medium
Mahmoud 2022 [28]	0	1	0	1	1	1	1	5: Medium



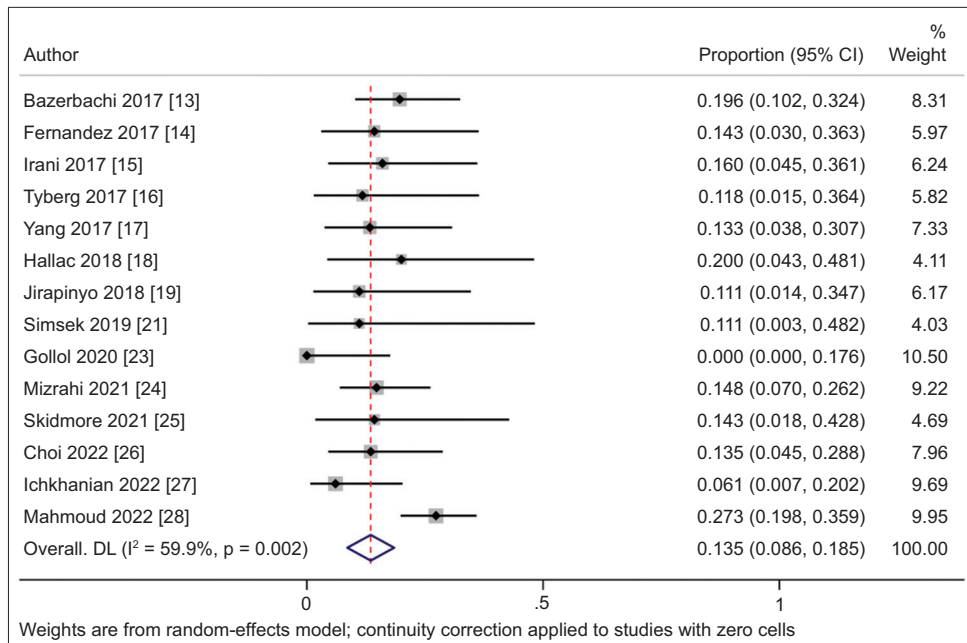
Supplementary Figure 1 Forest plot for pooled event rate of technical success with lumen apposing metal stents for benign luminal strictures
CI, confidence interval



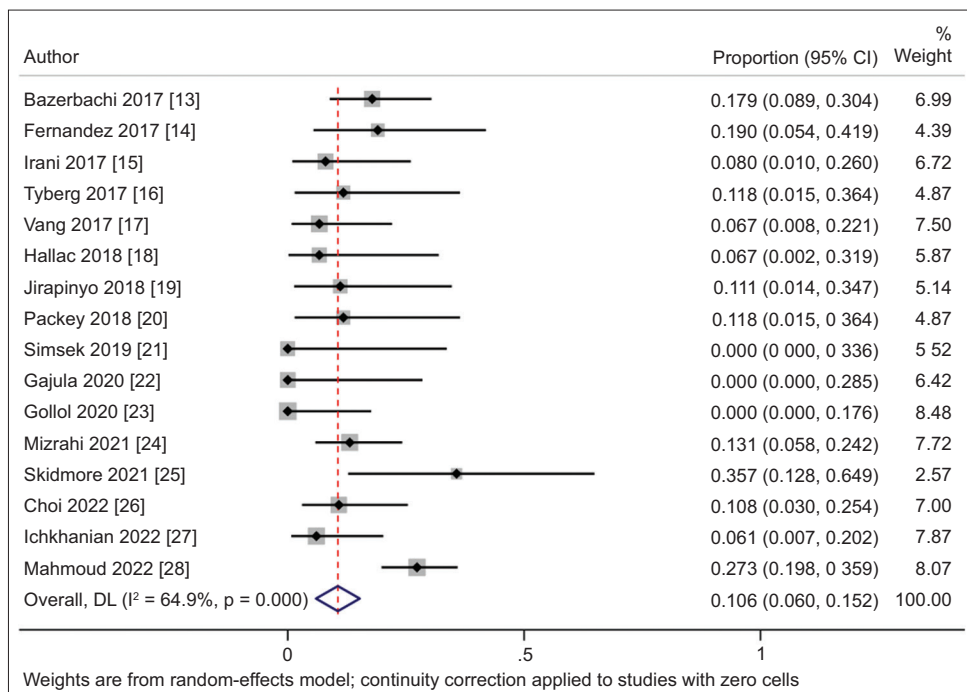
Supplementary Figure 2 Forest plot for pooled event rate of short-term success with lumen apposing metal stents for benign luminal strictures
CI, confidence interval



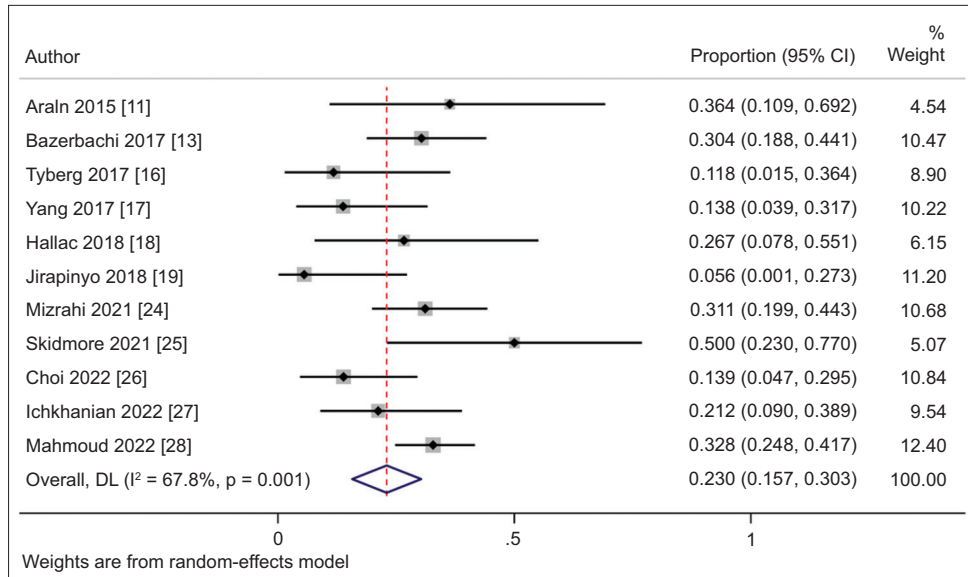
Supplementary Figure 3 Forest plot for pooled event rate of long-term success with lumen apposing metal stents for benign luminal strictures
CI, confidence interval



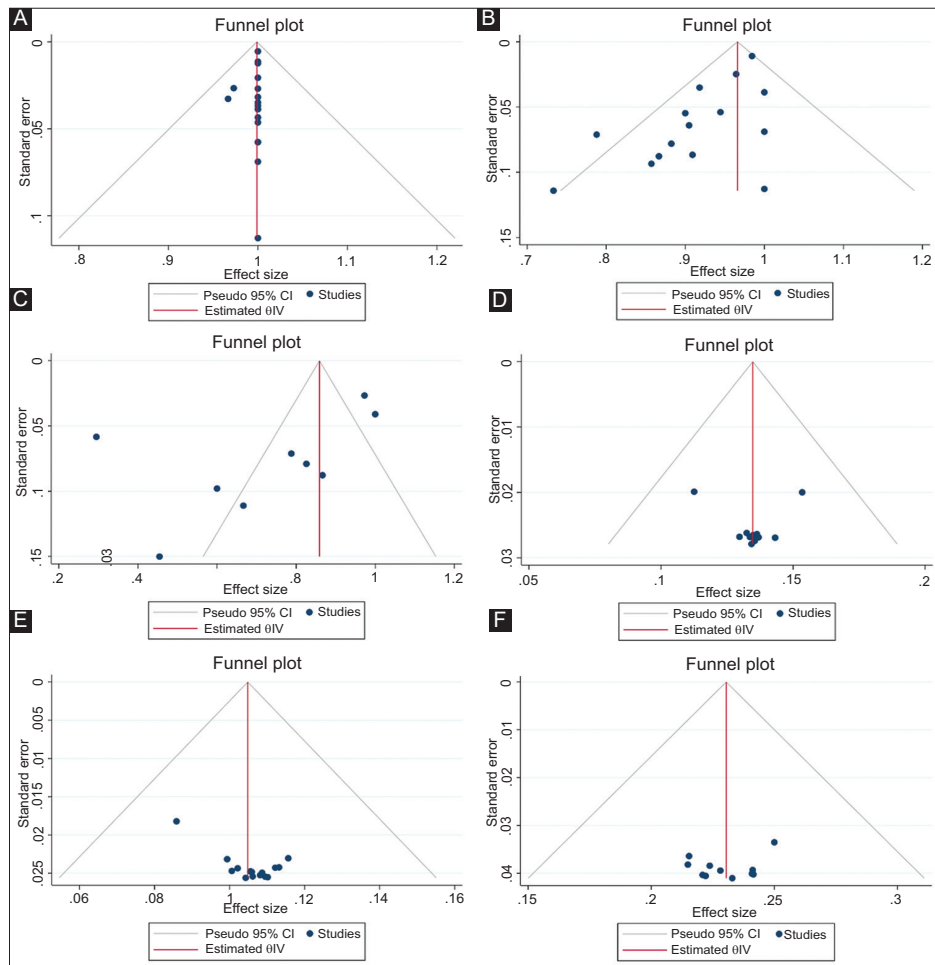
Supplementary Figure 4 Forest plot for pooled adverse event rate with lumen apposing metal stents for benign luminal strictures
CI, confidence interval



Supplementary Figure 5 Forest plot for pooled rate of migration with lumen apposing metal stents for benign luminal strictures
CI, confidence interval



Supplementary Figure 6 Forest plot for pooled rate of reintervention with lumen apposing metal stents for benign luminal strictures
CI, confidence interval



Supplementary Figure 7 Funnel plots for assessment of publication bias with respect to (A) technical success, (B) short-term clinical success, (C) long-term clinical success, (D) adverse events, (E) stent migration, and (F) reintervention
CI, confidence interval