

Current paradigm of endoscopic ultrasound in biliary and pancreatic duct drainage: an update

Vaneet Jearth^a, Sridhar Sundaram^b, Aditya Kale^b, Anurag Sachan^a, Surinder Singh Rana^a

Postgraduate Institute of Medical Education and Research (PGIMER), Chandigarh; Tata Memorial Hospital, Mumbai, Maharashtra, India

Abstract

Endoscopic retrograde cholangiopancreatography (ERCP) is the workhorse for biliary and pancreatic ductal interventions. Despite advances in both endoscopes and accessories for ERCP, it still has limitations in the presence of altered anatomy, luminal obstruction hindering access to the papilla, and proximal duct obstructions by tight stricture, calculi or intraductal growth. Endoscopic ultrasound-guided biliary drainage (EUS-BD) and EUS-guided pancreatic duct drainage (EUS-PDD) have expanded the rescue procedures after failed ERCP. This review discusses the techniques and results of various EUS-BD procedures, as well as EUS-PDD.

Keywords Endosonography, pancreatic duct, gallbladder, self-expanding metal stent, lumen-apposing metal stent

Ann Gastroenterol 2024; 37 (1): 1-14

Introduction

Despite advances, endoscopic retrograde cholangiopancreatography (ERCP) has limitations in the presence of altered anatomy, luminal obstruction hindering access to the papilla, and proximal duct obstructions by tight stricture, calculi or intraductal growth. Before the introduction of therapeutic endoscopic ultrasound (EUS), there were limited options for rescue in case of failure of ERCP. Percutaneous transhepatic (PT) biliary drainage (BD) has been the most commonly used rescue procedure for BD after failure of ERCP. However, PTBD is associated with a number of disadvantages, including external drainage resulting

in loss of bile, an externally placed catheter with associated discomfort, as well as a risk of accidental dislodgement and need for reinterventions. For pancreatic duct drainage, given the retroperitoneal position and smaller caliber of the duct, the only rescue procedure available was surgery. EUS has the benefit of direct visualization of ductal anatomy, wall, contents and nearby vessels, while providing an opportunity for drainage in the same setting. EUS-BD and pancreatic duct drainage (EUS-PDD) have expanded the rescue procedures after failed ERCP. The question thus arises: why is it not the first-line, but only a rescue procedure for biliary and pancreatic duct drainage? ERCP follows the natural route of drainage of the duct. In addition, ERCP is widely available, has a low overall failure rate of ~5-10% [1], needs no transmural puncture, thus obviating the risks of bleeding and perforation, and is cheaper compared to EUS-guided duct drainage. With its high efficacy, feasibility, technical availability, smaller learning curve and cheaper cost, ERCP remains and is likely to remain the first-line intervention for biliary and pancreatic drainage.

^aDepartment of Gastroenterology, Postgraduate Institute of Medical Education and Research (PGIMER), Chandigarh (Vaneet Jearth, Anurag Sachan, Surinder Singh Rana); ^bDepartment of Digestive Diseases and Clinical Nutrition, Tata Memorial Hospital, Mumbai, Maharashtra (Sridhar Sundaram, Aditya Kale), India

Conflict of Interest: None

Correspondence to: Dr Surinder Singh Rana, Professor, Department of Gastroenterology, PGIMER, Chandigarh, 160 012, India, e-mail: drsurinderrana@yahoo.co.in

Received 21 August 2023; accepted 19 October 2023; published online 23 December 2024

DOI: <https://doi.org/10.20524/aog.2023.0854>

This is an open access journal, and articles are distributed under the terms of the Creative Commons Attribution-NonCommercial-ShareAlike 4.0 License, which allows others to remix, tweak, and build upon the work non-commercially, as long as appropriate credit is given and the new creations are licensed under the identical terms

Classification of EUS-guided biliary access and drainage procedures

EUS-guided cholangiography was first described in 1996 by Wiersema [2]. Subsequently, EUS-guided choledochoduodenostomy (CDS) was first performed by Giovannini *et al* in 2001 [3], and Burmester *et al* performed the first hepaticogastrostomy (HGS) in 2003 [4]. EUS-BD has evolved over the years, and may now be classified into access procedures (bile duct is punctured and guidewire is

passed across ampulla followed by ERCP and BD) or drainage procedures (direct puncture of bile duct from stomach or duodenum and drainage performed by transmural stent placement). Direct drainage procedures can further be divided into intrahepatic and extrahepatic drainage. The left hepatic duct is the preferred route for intrahepatic drainage, because of its anatomic proximity to the stomach. On the other hand, the right hepatic duct can also be targeted in select cases via the duodenum [5-7]. Extrahepatic drainage is performed by targeting the common bile duct (CBD) or common hepatic duct (CHD), whichever is more feasible in a particular case. EUS-gallbladder drainage (EUS-GBD) may be used for BD when the cystic duct is patent and puncturing the CBD/CHD is not technically feasible [6-8]. EUS-BD can also be subclassified as transpapillary (EUS-guided rendezvous [RV] and EUS-guided antegrade [AG] stent placement) or transmural procedures (EUS-CDS and EUS-HGS) [7].

Technical aspects of EUS-BD

All types of EUS-BD are associated with 4 major steps [9]: puncturing the bile duct, guidewire passage, transmural tract dilatation and stent placement. The puncture is usually made into the bile duct or intrahepatic radicles with a 19-G needle, followed by passage of a 0.035" or 0.025" guidewire. In situations where the intrahepatic radicles are not significantly dilated, a 22-G needle may be used for puncture, followed by use of a 0.018" guidewire. Tract dilatation can be performed using either diathermic (cystotome) or non-diathermic methods (Bougie or balloon). A higher rate of bleeding may be seen in patients undergoing tract dilatation with diathermic catheters [10]. However, the rate of significant bleeds not controlled by tamponade from the subsequently deployed stent is minimal. While conventional uncovered biliary metal stents can be used for AG transpapillary stent placement, covered or partially covered self-expanding metal stents (SEMS) or lumen-apposing metal stents (LAMS) are needed for EUS-CDS. Specially designed stents with an uncovered distal end (Giobor stents) are used for EUS-HGS. While significant dilatation of the CBD is required for stent placement in EUS-CDS, EUS-HGS can be carried out even in situations with minimally dilated intrahepatic biliary radicles.

Outcomes of EUS-BD procedures

While transpapillary procedures are similar to ERCP, transmural procedures require the creation of a fistula connecting the bile duct with the duodenum, or intrahepatic radicles with the stomach. No previous large studies have compared the outcomes of transpapillary and transmural procedures.

Transpapillary procedures

These carry the distinct advantage of ensuring physiological drainage, especially in patients with a benign biliary obstruction. Transpapillary EUS-BD can be either EUS-AG stent placement or an EUS-RV procedure.

EUS-AG

EUS-AG is a complex procedure requiring guidewire manipulation from the left hepatic duct, across the biliary stricture and ampulla into the duodenum (Fig. 1). It was first described by Nguyen-Tang *et al* in 2010 [11] and thereafter, a number of studies have reported its safety and efficacy [12-18]. Although the wire manipulation makes this a technically challenging procedure, it still has the advantages of a transpapillary route for stent placement and the use of standard ERCP stents for the procedure (Table 1). In a previous large series from India, it was shown that AG drainage can be successfully employed as a method of preoperative BD, as an alternative to PTBD in cases of failed ERCP, with excellent clinical and technical success. Surgical outcomes following AG BD were favorable, with 10/11 undergoing pylorus-preserving pancreatoduodenectomy without complications [16]. Iwashita *et al* showed that EUS-AG interventions were successful even in patients with a surgically altered anatomy. Anastomotic stricture dilatation and CBD stone clearance can also be achieved using the AG method [17]. An AG drainage procedure provides a more physiological form of BD compared to EUS-CDS, EUS-GBD, and EUS-HG. This might be important in a preoperative setting, where the creation of fistulous communication between duodenum, stomach or antrum, and bile duct or gallbladder may elicit adhesions or fibrosis.

EUS-RV

This technique is used when the papilla is accessible with endoscopy, but deep cannulation is not possible. The puncture for guidewire passage across the bile duct and through the papilla can be made via a transhepatic route or a trans-duodenal route, from either the duodenal bulb or the second part of the duodenum [19]. Biliary cannulation can be reattempted alongside the wire, or the wire can be pulled out of the duodenoscope and cannulation attempted over the wire. The most challenging step in this procedure is steering the guidewire across the ampulla. Limitations associated with EUS-RV include the need for wire manipulation across the papilla, the change back to a duodenoscope, prolonging procedure time while entailing a risk of wire dislodgement, and the risk of acute pancreatitis associated with wire manipulation across the papilla. In order to facilitate easy cannulation over the guidewire in patients undergoing RV, Nakai *et al* described the "Hitch and Ride" technique using a modified ERCP cannula with a slit for engaging the guidewire [20].

Table 1 Literature review depicting technical success, clinical success and complications of EUS-AG

Authors [ref.]	Year	Mode of EUS-BD	Technical success (n)	Functional success (Jaundice resolution)	Complications (n)
Nguyen-Tang [11]	2010	EUS-AG	(100%) 5/5	100%	Nil
Shah <i>et al</i> [12]	2012	EUS-AG	81% (13/16)	-	6% (1/16) hepatic hematoma
Artifon <i>et al</i> [13]	2011	EUS-AG	100% (1/1)	100%	Nil
Park <i>et al</i> [14]	2012	EUS-AG	100% (1/1)	100%	Nil
Iwashita <i>et al</i> [17]	2013	EUS-AG	100% (2/2)	100%	50%, (1/2) mild pancreatitis, abdominal pain
Park <i>et al</i> [15]	2013	EUS-AG	57% (8/14)	100%	Nil
Sundaram <i>et al</i> [16]	2023	EUS-AG	88.7% (47/53)	95.7% (45/47)	Nil
Iwashita <i>et al</i> [18]	2020	EUS-AG	97.1%	97.1%	11.4%

EUS, endoscopic ultrasound-guided; AG, antegrade; BD, biliary drainage

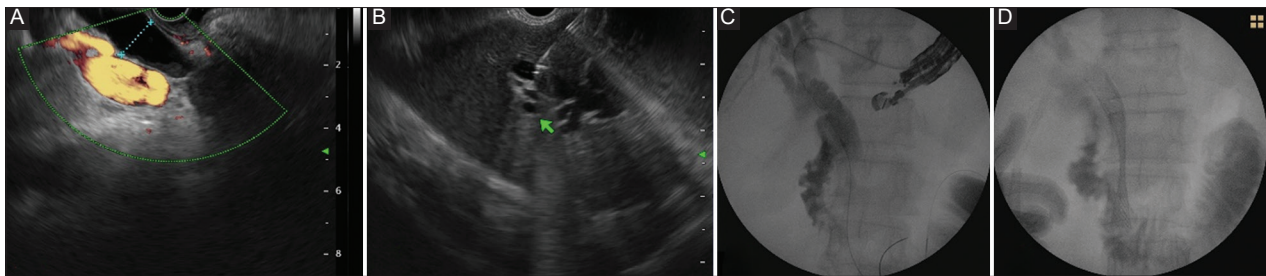


Figure 1 Periapillary adenocarcinoma causing distal biliary obstruction. The papilla is inaccessible because of duodenal infiltration. (A) Dilated common bile duct with distal biliary obstruction. (B) EUS-guided puncture of biliary radicles in left lobe. (C) Guidewire negotiated across the stricture into the duodenum. (D) Antegrade biliary SEMS placed
EUS, endoscopic ultrasound; SEMS, self-expanding metal stent

Mallery *et al*, for the first time, punctured intrahepatic biliary radicals and performed RV procedures in 2 cases [21]. Subsequently, many studies using this approach as a rescue procedure were published (Table 2) [22-26]. In cases of difficult CBD cannulation, Iwashita *et al* performed the EUS-RV procedure through D1, D2 and stomach in 20 patients. The guidewire could be successfully manipulated in 100% (10/10) of patients with the D2 (second part of duodenum) approach, and 66.7% (6/9) patients with stomach and D1 approach, with an overall success rate of 80%. Only 2 patients required a percutaneous approach for BD [26]. Dhir *et al* compared precut sphincterotomy with EUS-RV for failed cannulation [27]. The success rate was significantly higher for the EUS-RV (57/58 patients) than for those undergoing the pre-cut papillotomy technique (130/144 patients) (98.3% vs. 90.3%; $P=0.03$). Importantly, there was no significant difference in the rate of procedural complications (3.4% vs. 6.9%, $P=0.27$), suggesting that EUS-RV is a safe procedure in case of failed cannulation. In another study of 35 patients, Dhir *et al* showed that the transhepatic RV was associated with a longer procedure time, more post-procedure pain and a need for longer hospitalization, compared to trans-duodenal procedures [25]. Based on the results of this study, they suggested that the trans-duodenal route should be the preferred route for RV when access to the distal CBD is available.

Transmural procedures

Considering the need for fistulization and stent placement across the fistulous tract, these procedures are usually carried out in patients with a malignant biliary obstruction. Their role is typically described in patients with unresectable biliary obstruction [28], with emerging data for resectable malignancies [29].

EUS-CDS/choledochojejunostomy

EUS-CDS is performed in patients with distal biliary obstruction; many groups have published their data on its technical success, clinical success and complications (Table 3) [3,30-39]. Initially, when plastic stents were placed across the fistula created between the bile duct and duodenum [30,31], the risk of bile leakage and peritonitis was an important concern [40]. The use of covered SEMS and electrocautery-enhanced LAMS has reduced the risk of bile leakage [39-41]. Proper orientation of the EUS scope towards the hepatic hilum is critical for passage of the guidewire towards the hilum [39,42,43]. Double mucosal puncture can occur during the procedure, which may result in bleeding and perforation [42,43]. The water-filling technique, which

Table 2 Literature review depicting technical success, clinical success and complications of EUS-RV

Authors [ref.]	Year	Mode of EUS-BD	Intrahepatic	Extrahepatic	Technical success (n)	Functional success (Jaundice resolution)	Complications (n)
Mallery <i>et al</i> [21]	2004	EUS-RV	2	0	100%	100%	Nil
Kahaleh <i>et al</i> [22]	2006	EUS-RV	11/13 (85%)	7/10 (70%)	18/23 (78%)	100%	Bleeding-1, peritonitis-1, pneumoperitoneum-4, pneumonia-1, abdominal pain-1
Maranki <i>et al</i> [23]	2009	EUS-RV	24/35 (69%)	8/14 (57%)	32/49 (65%)	29 (83%)	Bleeding, peritonitis and pneumonia-1 each, Pneumoperitoneum (4)
Iwashita <i>et al</i> [24]	2012	EUS-RV	4/9 (44%)	25/31 (85%)	29/40 (73%)	29 (73%)	Abdominal pain, pneumoperitoneum and death-1 each, pancreatitis-2
Dhir <i>et al</i> [25]	2013	EUS-RV	16/17 (94%)	18/18 (100%)	34/35 (97%)	34 (100%)	Abdominal pain-8, bile leak-2, pneumoperitoneum-2
Iwashita <i>et al</i> [26]	2016	EUS-RV	-	16/20 (80%)	16/20 (80%)	Not available	Hematoma-1, pancreatitis-2

EUS, endoscopic ultrasound-guided; BD, biliary drainage; RV, rendezvous technique

Table 3 Literature review depicting technical success, clinical success and complications of EUS-CDS

Authors [ref.]	Year	Mode of EUS-BD	Stent type	Technical success (n)	Functional success (jaundice resolution)	Complications (n)
Giovannini <i>et al</i> [3]	2001	CDS	Plastic stent	1/1 (100%)	1/1 (100%)	None
Hara <i>et al</i> [30]	2011	CDS	Plastic stent	17/18 (94%)	3/18 (17%)	Peritonitis-2, hemobilia-1
Komaki <i>et al</i> [31]	2011	CDS	Plastic stent	14/15 (93%)	7/14 (50%)	Cholangitis-4, stent migration-1, peritonitis-2
Park <i>et al</i> [32]	2011	CDS	Plastic stent/ Covered SEMS	24/26 (92%)	5/26 (19%)	Not available
Artifon <i>et al</i> [33]	2012	CDS	Covered SEMS	13/13 (100%)	2/13 (15%)	Bleeding-1 Bile leak-1
Khashab <i>et al</i> [34]	2013	CDS	Plastic stent/ covered SEMS	20/20	Not available	
Kawakubo <i>et al</i> [35]	2014	CDS	Plastic stent/ covered SEMS	43/44 (95%)	Not available	Bile leak-3, stent misplacement, bleeding, perforation, pneumoperitoneum-1 each
Hara <i>et al</i> [36]	2013	CDS	Covered SEMS	17/18 (94%)	17/17 (100%)	Peritonitis-2
Rai <i>et al</i> [37]	2018	CDS	Covered SEMS (Wallflex)	28/30 (93.3%)	28/28 (100%)	Bile leak-1, hemobilia-1
Jacques <i>et al</i> [38]	2019	CDS	LAMS (hot Axios)	46/52 (88.5%)	46/46 (100%)	Cholangitis and bleeding 1 each
Anderloni <i>et al</i> [39]	2019	CDS	LAMS (hot Axios)	43/46 (93.5%)	42/43 (97.1%)	Bleeding-1, stent occlusion-3, migration-1

EUS, endoscopic ultrasound-guided; CDS, choledochoduodenostomy; BD, biliary drainage; SEMS, self-expanding metal stent; LAMS, lumen-apposing metal stent

distends the lumen and flattens the folds, can avoid double mucosal puncture [42,43]. Rarely, cystic duct puncture may occur during EUS-CDS, leading to failure; therefore, caution should be exercised while puncturing the dilated duct. Tract dilatation for stent placement is needed for placement of tubular stents and bile leak can occur during this process.

Options for dilatation include the bougie biliary dilator, balloon biliary dilator and coaxial electrocautery dilator. Honjo *et al* compared a novel mechanical dilator with an ultra-tapered tip to an electrocautery dilator. They reported similar clinical success (100% [23/23] vs. 92.3% [24/26]; P=0.52), but there was more bleeding with the electrocautery dilator [10].

In the authors' experience, the use of a 6-Fr cystotome is safe for tract creation and dilatation, without a significant increase in bleeding risk (Fig. 2). Considering the risk of bleeding, and also bile leak, electrocautery-enhanced LAMS appears to be a better suited stenting approach for EUS-CDS, because of the single-step assembly and controlled release of the stent. A previous study that included 57 patients, comparing tubular SEMS and LAMS, found no significant difference between the 2 groups in terms of technical success, clinical success, adverse events, reinterventions or survival rates [44]. However, more endoscopists prefer using LAMS for the sheer convenience of single-step delivery. Cost-effectiveness is another aspect that needs to be discussed, considering the higher cost of LAMS. In a recent randomized controlled trial of EUS-CDS using LAMS vs. ERCP in patients with unresectable distal biliary obstruction, EUS-CDS was associated with a higher rate of technical success (EUS-CDS 96% vs. ERCP 76%) and needed a shorter procedure time [45].

Large studies on EUS-CDS have shown stent patency ranging from 180-370 days [40]. The Leuven-Amsterdam-Milan study group recently described the various types of dysfunction known to occur in patients undergoing EUS-CDS with LAMS: 31% of patients developed dysfunction after a mean of 166 days. Type I refers to Sump syndrome; type II refers to impaction inside the LAMS (IIa, due to stone or sludge, or IIb, due to food bolus); type III refers to LAMS obstruction due to invasion or compression (IIIa, on the biliary side, or IIIb, on the duodenal side); type IV refers to LAMS migration; and type V refers to gastric outlet obstruction leading to symptoms of poor bile drainage. Type II is the most common type of dysfunction, followed by type V, with duodenal stenosis being the only predictor of dysfunction (hazard ratio 2.7, 95% confidence interval [CI] 1.1-6.8) [46]. Almost all the types of LAMS dysfunctions can be managed endoscopically (96%).

EUS-HGS

In this procedure, using a transgastric approach, a fistula is created between segment 3 intrahepatic ducts (rarely segment 2) and stomach, followed by partially covered or fully covered SEMS placement (Fig. 3). Bile leak,

pneumoperitoneum, bleeding and biloma are commonly reported complications [47]. Table 4 shows the technical success, clinical success and complications of large EUS-HGS case series [10,32,48-53]. Oh *et al*, in their study, suggested that a bile-duct diameter of >5 mm and a hepatic portion of 1 cm to <3 cm is suitable for EUS-HGS. They analyzed the learning curve for EUS-HGS and suggested that at least 33 cases are required to develop the necessary skills to perform EUS-HGS procedures [53]. Ogura *et al*, in their study, suggested that if the angle between the puncture and the biliary radical is less than 90°, the subsequent procedure becomes more difficult [54]. Honjo *et al*, in their study comparing 2 methods of dilatation (ultra-slim mechanical dilator vs. cautery dilator), observed more bleeding with the cautery dilator for a similar tract dilatation size [10]. Careful selection of the biliary radical, looking for intervening blood vessels using Doppler, use of a cautery dilator after securing deep access, use of covered SEMS and avoiding puncture of a biliary radical <math><5\text{ mm}</math> will help preclude complications [47,53]. Median stent patency according to major studies ranges from 137-368 days [10,53,55]. Critical steps in EUS-HGS are choosing an appropriate biliary radicle for puncture (segment B3, typically running from top left to bottom right) and intra-channel stent deployment, ensuring a long segment is deployed into the stomach [55]. The long intragastric segment lowers the risk of internal stent migration, while reducing the risk of food impaction in the stent.

While CDS can only be used for distal biliary obstruction, HGS can be applied for both distal and proximal obstructions. The choice of one procedure over another in distal obstruction remains at the discretion of the endoscopist. A previous systematic review of 10 studies comparing these techniques showed similar rates of technical and clinical success between CDS and HGS, with no difference in the rate of adverse events [56]. In another systematic review, the pooled rate of early adverse events was lower with CDS compared to HGS (12.3% vs. 17.5%, odds ratio [OR] 0.58, 95%CI 0.36-0.93; $P=0.02$) [57]. However, HGS stent patency in a previous study was much higher (133 days vs. 37 days, adjusted hazard ratio 0.391, 95%CI 0.156-0.981; $P=0.045$) in the presence of duodenal stenosis, and should be preferred over CDS in this setting [58]. Overall, the jury is still out on the choice of one procedure over another.

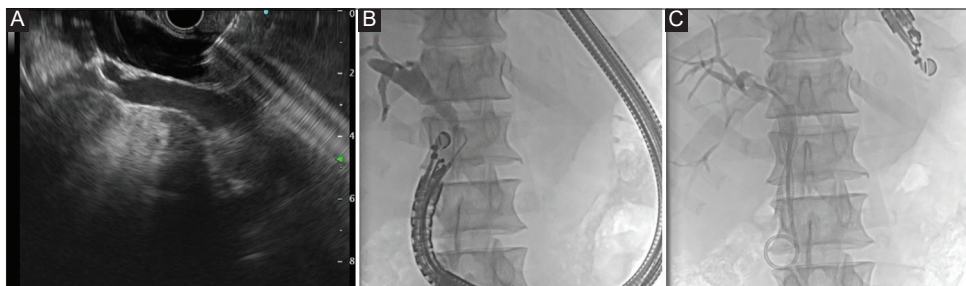


Figure 2 Pancreatic adenocarcinoma causing distal biliary obstruction. The papilla is inaccessible because of duodenal infiltration. (A) EUS-guided puncture of the common bile duct. (B) Guidewire being negotiated into bile duct towards hilum. (C) Transmural fully covered SEMS placed into common bile duct. A double pigtail stent is placed through the stent to prevent migration of the SEMS
EUS, endoscopic ultrasound; SEMS, self-expanding metal stent

Table 4 Literature review depicting technical success, clinical success and complications of EUS-HG

Authors [ref.]	Year	Mode of EUS-BD	Technical success (n)	Clinical success	Complications (n)
Park <i>et al</i> [32]	2011	EUS-HG	31/31 (100%)	27/31 (87%)	Bile peritonitis-1; self-limited pneumoperitoneum-2
Attasaranya <i>et al</i> [48]	2012	EUS-HG	13/16 (81%)	13/13 (100%)	6 (38%) extragastric stent placement-1, abdominal pain-2, fever-2, collection-1
Bories <i>et al</i> [49]	2007	EUS-HG	10/11 (91%)	4/11 (36%)	Stent occlusion, biloma, ileus, cholangitis-1 each
Vila <i>et al</i> [50]	2012	EUS-HG	22/34 (65%)	11/22 (50%)	11/34 (29%) Biloma 3, bleeding 3, perforation-2, liver hematoma-1, abscess-1
Poincloux <i>et al</i> [51]	2015	EUS-HG	65/66 (98%)	Not available	Bile leak-5, pneumoperitoneum-2, liver hematoma-1, severe sepsis and death-2
Khasab <i>et al</i> [52]	2016	EUS-HG	56/61 (92%)	45 (82.1%)	Peritonitis-3, bile leak-2, cholangitis-2, intraperitoneal stent migration-2, bleeding-1, hepatic collection-1, shared wire-1
Oh <i>et al</i> [53]	2017	EUS-HG	120/129 (93%)	Not available	Bacteremia-16, bleeding-5, bile peritonitis-4, pneumoperitoneum-4, intraperitoneal stent migration-3
Honjo <i>et al</i> [10]	2018	EUS-HG	41/41 (100%)	Not available	Bile peritonitis-4, cholangitis-1, stent migration-1

EUS, endoscopic ultrasound-guided; HG, hepaticogastrostomy; BD, biliary drainage

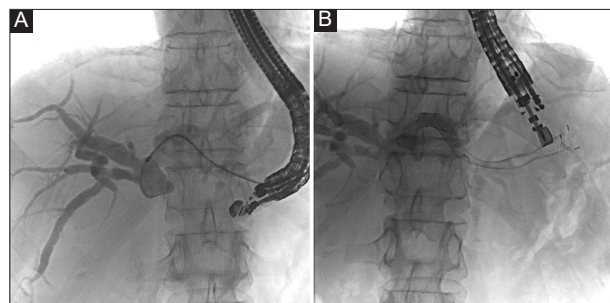


Figure 3 EUS-guided hepatico-gastrostomy in a patient with cholangiocarcinoma. (A) The transmural tract being dilated with cystotome. (B) Partially covered SEMS placed
EUS, endoscopic ultrasound; SEMS, self-expanding metal stent

Safety of EUS-BD

A recent large systematic review of 155 studies compared adverse events associated with EUS-BD [59]. The pooled rate of adverse events was 13.7% (95%CI 12.3-15.0). The rate was highest for HGS (15.5%), followed by CDS (11.9%), AG stent placement (9.9%) and RV (8.8%). Major adverse events were seen in 0.6%, with mortality reported in 0.1%. There was a need for reintervention in 16.0%, more for HGS (20.9%) than CDS (15.8%).

EUS-GBD

EUS-GBD is a rescue procedure for patients with acute cholecystitis who are poor surgical candidates (Fig. 4). Recent studies have shown high technical success rates ranging from 90-98.7% and clinical success rates of 89-98.4% [8,60-64].

In patients with acute cholecystitis who are poor surgical candidates and undergo percutaneous gallbladder drainage, internalization of the catheter can be successfully performed using LAMS placement under EUS guidance. Law *et al*, in their study (7 patients) achieved a technical success rate of 100%. Two patients required placement of covered SEMS through LAMS, to connect the gallbladder to the lumen. No adverse events were observed at a mean of 2.5-month follow up [61]. A previous systematic review and meta-analysis of 5 studies with 495 patients showed a variety of postprocedural adverse events (overall 20.4%), including gastrointestinal bleed (7 patients), stent dislodgement (n=1), stent blockage (n=5), pneumoperitoneum (n=4), intraabdominal collections (n=4), and peritonitis (4) [64]. Choi *et al* followed up patients who underwent EUS-GB drainage for 3 years and noted a median stent patency of 86% at 3 years, while 96.4% had no recurrence of cholecystitis [60]. While most patients undergo EUS-GBD in settings of acute cholecystitis, it can be considered a rescue in patients who have a malignant biliary obstruction with a patent cystic duct and narrowing distal to the cystic duct insertion. In a previous small multicenter study of 28 patients that evaluated the role of EUS-GBD as rescue after failed ERCP in distal obstruction, the technical and clinical success were 100% and 93%, respectively, with a significant reduction in bilirubin levels [65].

EUS-BD in special situations

Benign biliary obstruction

While most EUS-BD procedures are performed in malignant biliary obstruction, EUS-BD can be performed in

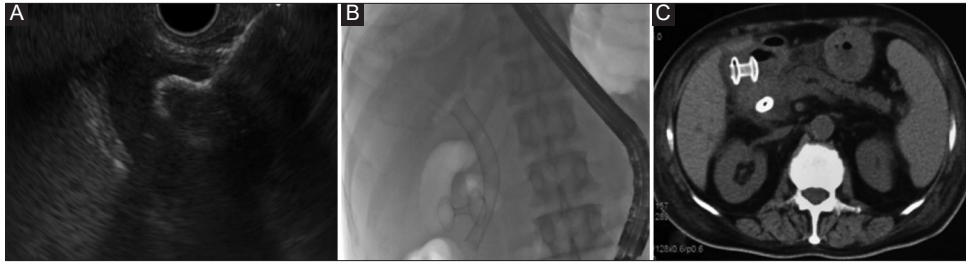


Figure 4 EUS guided cholecysto-duodenostomy for acute cholecystitis in a patient with pancreatic adenocarcinoma and cystic duct obstruction. (A) Inner flange of cauterized LAMS placed inside the gallbladder lumen. (B) LAMS deployed. (C) CT abdomen showing deployed LAMS with one flange in the gallbladder and the other flange in the duodenum

EUS, endoscopic ultrasound; LAMS, lumen-apposing metal stent; CT, computed tomography

benign biliary obstruction, predominantly to gain access to the bile duct. While EUS-RV can be done for access, in situations where papilla is inaccessible, EUS-AG intervention for stone extraction has been described [66]. In a large series by Mukai *et al*, involving 37 patients, stone extraction was successful via the AG route in 91%, with adverse events in 15% [67]. In certain situations, a 2-step approach with initial HGS followed by AG stone extraction can also be used [68].

Hilar obstruction

EUS-BD has been well described in distal malignant obstruction; however, data relating to hilar biliary obstruction are sparse. The critical issue in hilar obstruction remains the volume of liver drained. While PTBD is the procedure of choice for complex hilar obstruction [69], EUS-BD has the distinct advantage of single-step internal drainage. Overall, various types of procedures can be undertaken to ensure optimal BD in hilar obstruction, including EUS-HGS (For left duct drainage with communicating blocks), EUS-hepaticoduodenostomy (EUS-HDS; for right duct drainage with communicating blocks), EUS-guided HGS with bridging stent placement (for complex blocks to drain right and left system) and combined ERCP-EUS drainage (CERES: EUS-HGS with right ERCP or EUS-HDS with left ERCP) [70]. In a previous series by Minaga *et al*, the technical success of EUS-BD in complex hilar blocks (II, III, IV) was 91% and the clinical success was 75%. Type IV block was the only predictor of clinical failure [71]. In another study by Kongkam *et al*, the technical and clinical success rates of CERES were similar to those of PTBD in complex hilar blocks; however, the need for reintervention was much lower in CERES [72].

Surgically altered anatomy

EUS-BD is an alternative to enteroscopy-assisted ERCP (e-ERCP) in patients with a surgically altered anatomy. In situations where the papilla is inaccessible, depending on the anatomy and the nature of the biliary obstruction (benign or

malignant), the type of EUS-BD can be planned [3]. In patients with Billroth II or post-Whipple anatomy, EUS-HGS or EUS-AG intervention can be planned. In those with Roux-en-Y gastric bypass, an EUS-directed transgastric ERCP procedure may need to be performed, with a connection established between the excluded stomach and remnant using a LAMS. In a previous multicenter study comparing e-ERCP with EUS-BD, the technical success rate was much higher with EUS-BD (98% vs. 65%, OR 12.48, 95%CI 2.69-57.78) [73]. However, more adverse events were seen in the EUS-BD group (20% vs. 4%, $P=0.01$) as well as a significantly longer hospital stay. Hence EUS-BD in this cohort must be used only in expert centers.

Algorithmic approach to EUS-BD in a case with failed or not feasible ERCP

We suggest the following approach (Fig. 5) to a patient with a biliary obstruction and failed ERCP, or where ERCP is not feasible. In a patient with normal anatomy and access to the papilla, if regular ERCP is not feasible despite salvage techniques, EUS-BD can be attempted as a safe therapeutic option to PTBD in case of failed ERCP.

EUS-PDD

EUS-PDD has emerged as a feasible rescue method to drain the pancreatic duct in patients when standard transpapillary ERCP is either impossible or unsuccessful [74-76]. The only rescue option available in the case of failed ERCP used to be surgery, associated with significant morbidity and associated consequences of loss of pancreatic tissue [77]. EUS-PDD, however, does not preclude surgery later, if required. A recent, systematic review focusing on late complications following pancreatoduodenectomy, proposed EUS-PDD as first-line modality for the management of anastomotic site stricture that was reported in up to 11.4% of cases within 34 months of surgery [78]. In these settings, e-ERCP as first-line option is associated with high failure rates, whereas EUS-PDD is superior in terms of efficacy and has acceptable safety [79].

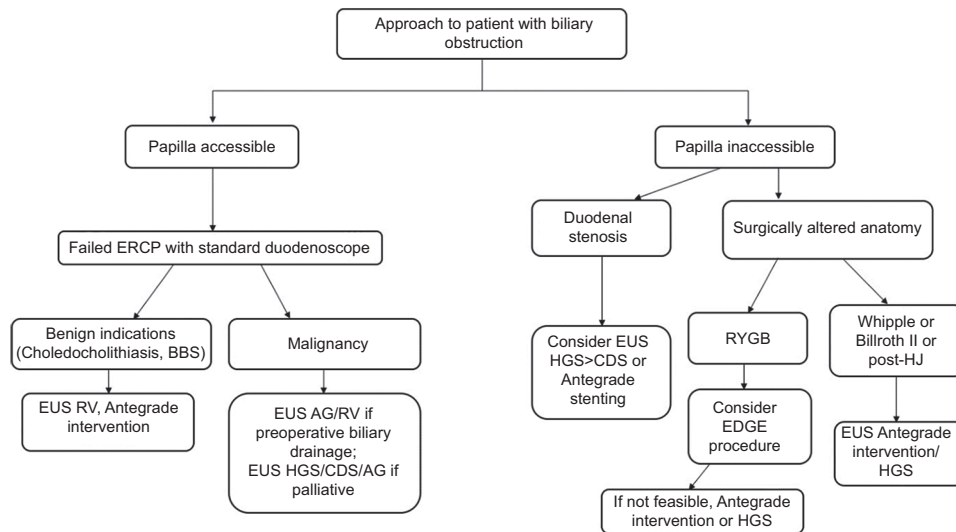


Figure 5 Algorithmic approach to EUS-BD in a case with failed or not feasible ERCP

EUS, endoscopic ultrasound-guided; BD, biliary drainage; HGS, hepaticogastrostomy; CDS, choledochoduodenostomy; AG, antegrade; ERCP, endoscopic retrograde cholangiopancreatography; RYGB, Roux-en-Y gastric bypass; BBS, benign biliary strictures; RV, rendezvous; HJ, hepaticojejunostomy; EDGE, EUS-directed transgastric ERCP

Furthermore, Kogure *et al* later reported that a combination of double balloon e-ERCP and EUS-PDD, used interchangeably as salvage procedures, can achieve superior technical and clinical success in surgical altered anatomy [80].

EUS-PDD relies on similar principles of endoscopic transmural drainage via the transgastric or transduodenal route of pancreatic fluid collections. However, EUS-PDD requires more technical expertise, given the relatively small caliber of the dilated main pancreatic duct (MPD), embedded in fibrotic pancreas, along with the unstable scope position in the stomach, the lack of dedicated transmural MPD stents, and the risk of pancreatitis associated with pancreatic manipulation. Therefore, the frequency of this procedure is still low. Data from the available literature suggest a technical success rate of approximately 80% and an adverse event rate of around 20% [81-83]. Therefore, careful patient selection and execution by well-trained interventional endoscopists are prerequisites before opting for this procedure. Tyberg reported a steep learning curve for this procedure, with mastery at the 40th case [84]. The indications and contraindications for EUS-PDD are summarized in Table 5.

Types of approach

EUS-PDD comprises 2 distinct approaches: EUS-RV PD drainage and EUS-guided transmural drainage (EUS-TMD). The choice of procedure relies mainly on 2 factors: access to the native papilla or anastomotic site, and the ability to negotiate a guidewire across them or across a pancreatic duct obstruction. The presence of both factors makes EUS-RV the first-line option, as it is able to address the anatomic issue and offers a

Table 5 Indications and contraindications for endoscopic ultrasound (EUS)-guided pancreatic duct drainage

<p>Indications</p> <ol style="list-style-type: none"> 1. Chronic pancreatitis with pancreatic duct obstruction due to stones/stricture 2. Disconnected pancreatic duct following acute pancreatitis/trauma 3. Failed pancreatic duct cannulation following standard endoscopic retrograde cholangiopancreatography or due to inaccessible papilla 4. Pancreatico-jejunal anastomotic site stricture 5. Refractory pancreatic fistula <p>Contraindications</p> <ol style="list-style-type: none"> 1. Severe coagulopathy/bleeding disorder 2. Not fit for sedation/endoscopy 3. Non visualization of main pancreatic duct on EUS 4. Long distance between puncture site and main pancreatic duct 5. Multiple strictures in main pancreatic duct 6. Intervening blood vessels 7. Non-dilated pancreatic duct (<3 mm)

physiological route of drainage. In the absence of either factor or both, EUS-TMD should be preferred [85-87].

Technical tips

Preprocedural preparation

Cross-sectional imaging with a contrast-enhanced computed tomography scan and/or magnetic resonance imaging with magnetic resonance cholangiopancreatography should be part of the preprocedural workup to evaluate the size and configuration of the MPD, the location of stricture/stones, and the distance between the pancreas and the stomach and vascular anatomy.

Puncture of MPD

The site of MPD puncture is crucial for subsequent technical success. It depends upon a number of factors, including the distance of the stomach or duodenum from the MPD, MPD size, the angle between the needle and the MPD, and any intervening vasculature. Although both transduodenal and transgastric puncture seem to have similar outcomes, in the literature the stomach is the most common puncture site. The distance between the puncture site and the MPD should be shortest in a stable scope position, and the angle of puncture needs to be oblique rather than perpendicular for better guidewire manipulation, preventing cannulation of side branches and negotiation of accessories [81,85,87].

A 19-G needle is the usual choice for MPD access, except when the pancreas is highly fibrotic or the MPD is not optimally dilated (<5 mm). A 22-G needle can be utilized in such cases; however, this will require an 0.018" guidewire, which has the inherent issues of poor fluoroscopic visibility and subsequent handling of accessories, which may require a change to a stiffer wire later. Therefore, some experts recommend puncture with a 19-G needle using 0.025" or 0.035" guidewires, even in a non-dilated MPD [81,85,87]. Gentle contrast injection to obtain a pancreatogram following puncture can be used to confirm position.

The next step is gentle guidewire insertion (0.025" or 0.035") into the MPD under fluoroscopic guidance, towards the head or tail of pancreas depending on the subsequent plan. Guidewire manipulation should be gentle to prevent shearing, which occurs mostly when the guidewire is pulled back at an acute angle [85]. These steps are common to any approach to EUS-PDD; the specific technique for each approach is described below.

EUS-RV

For EUS-RV specifically, the pancreatic neck is considered the optimal site for puncture, as opposed to the body or tail, as it permits easier guidewire manipulation [81,85]. The guidewire is negotiated towards the head of the pancreas and passed across the papilla or anastomotic site into the intestinal lumen, folded sufficiently to maintain MPD access. The linear echoendoscope is then withdrawn and exchanged for a duodenoscope (enteroscope or pediatric colonoscope

in surgical altered anatomy) and the guidewire is retrieved through the accessory channel using forceps or snare. The MPD is later cannulated over or alongside the guidewire.

EUS-TMD

EUS-TMD with transpapillary/transanastomotic stenting

An endoscopically inaccessible papilla and failure of EUS-RV could be tackled with this approach. Following access to the MPD as previously described, the transgastric or transduodenal tract is dilated using either cautery (6-Fr cystotome/needle knife) or non-cautery devices (mechanical dilators or balloon dilators). There is still debate as to the choice of device for tract dilation; however, some experts recommend using tapered non-cautery devices for dilating the tract initially, to decrease the risk of bleeding, perforation and pancreatitis due to the acute and late burn effects associated with cautery. If extensive pancreatic fibrosis and a thick MPD wall preclude tract dilation, then a coaxial cautery device can be employed as a rescue option. Step-up dilation of the needle tract to the smallest diameter required for stent deployment is another acceptable strategy to prevent pancreatic fluid leak [85,87]. An ultra-tapered mechanical dilator specially designed for EUS-guided transmural drainage demonstrated less postprocedural bleeding (0% vs. 18.2%, $P=0.04$), with statistically similar rates of dilation success and overall success of stent deployment compared to a 6-Fr cautery dilator [10]. Optimal tract dilation can be followed by the introduction of a second guidewire using a double lumen cannula, which helps with scope stabilization and facilitates the transmural deployment of 2 stents separately across the papilla or anastomotic site [88].

EUS-TMD using AG/retrograde stenting

If the guidewire cannot be negotiated across the MPD or anastomotic stricture, transmural drainage using AG (towards the head of pancreas/papilla) or retrograde (towards the tail) stenting is required. Apart from the basic principles mentioned earlier for choosing the optimal site for needle puncture, EUS-pancreaticogastrostomy (EUS-PGS) is favored

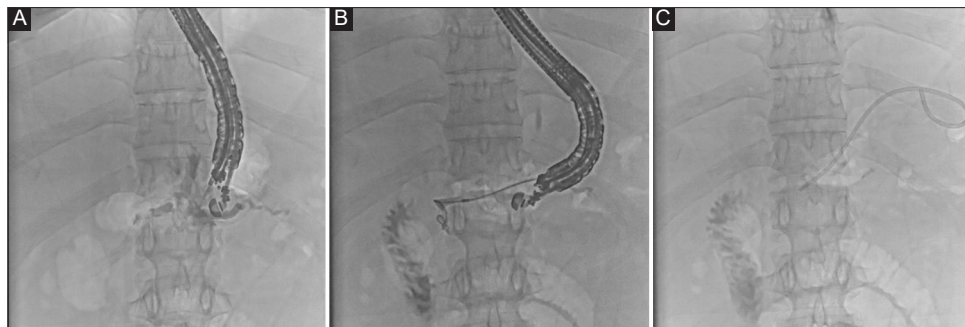

Figure 6 EUS-guided transmural pancreatico-gastrostomy using plastic stent in a patient with a disconnected pancreatic duct
EUS, endoscopic ultrasound

for body and tail drainage and EUS-pancreaticoduodenostomy (EUS-PDS) for MPD access to the pancreatic head [81]. After following the usual steps of MPD access and dilation of the tract, a 5- or 7-Fr stent is deployed, with one end in the MPD and other in the gastric or duodenal lumen (Fig. 6). The choice and type of stents need special mention for this approach. Most available studies utilized plastic stents for EUS-TMD [87]. Plastic stents without a side hole are recommended, in order to decrease the chances of a peritoneal leak. Certain technique modifications—such as using a longer single pigtail stent and retaining 2 thirds of the stent in the stomach, leaving the other end in MPD, and ring drainage/gastro-pancreatico-jejunostomy (distal end of the stent in the intestinal lumen and proximal end in the stomach)—reduce the chances of stent migration [87,89]. A fully covered self-expandable metal stent (FCSEMS) is a feasible alternative to plastic stents, with lower chances of a peritoneal leak and longer stent patency (Fig. 7). Modified FCSEMS (M.I. Tech, Seoul, Korea) with anti-migratory properties (with proximal and distal anchoring flaps) also have less chance of stent migration [90]. The use of uncovered SEMS is not recommended, given the obvious risk of pancreatic juice leakage and tissue ingrowth preventing removal. Plastic stents have an edge over metallic stents when the MPD is not very dilated [87]. The use of LAMS for EUS-TMD of MPD has been reported, but its utility is limited by the prerequisite of hugely dilated MPD [91].

EUS-TMD of recurrent pancreatic fluid collections due to disconnected pancreatic duct syndrome is the standard line of management. However, in the absence of significant collections and in the setting of pancreatico-cutaneous fistula, EUS-PGS can be utilized to place a stent in an excluded upstream main MPD, creating an internal fistula [92].

Outcomes

Most of the published data related to EUS-PDD are retrospective, involving case reports and case series. There is a lack of standardized definitions for technical and clinical success, while several studies make no clear distinction between the types of approach; thus, direct comparisons and isolated assessment are difficult [86]. Recent guidelines by the European Society of Gastrointestinal Endoscopy include

the strong recommendation, with low quality evidence, that “EUS-PDD should only be considered in symptomatic patients with an obstructed MPD when retrograde endoscopic intervention fails or is not possible” [93].

Bhurwal *et al*, in a recent meta-analysis of 16 studies and 503 patients, reported a technical success rate of 81.4%, a clinical success rate of 84.6% and an overall adverse event rate of 21.3%. Postprocedural pain was most common adverse event post procedure, while the pooled adverse event rate for postprocedural pancreatitis was 5% [83]. Another meta-analysis earlier reported similar outcomes and pooled adverse event rates of 18.1% (95%CI 14.2-22.9) with pooled rates for post-procedure pancreatitis being 6.6% (95%CI 4.5-9.4%), for bleeding being 4.1% (95%CI 2.7-6.2), for pancreatic leakage and/or pancreatic fluid collection being 2.3% (95%CI 1.4-4) and for perforation and/or pneumoperitoneum being 3.1% (95% CI 1.9-5) [82]. EUS-RV is associated with a higher technical success rate and a lower adverse event rate compared to EUS-PGS [93,94]. Uchida *et al* evaluated the outcomes of EUS-PDD in 15 patients with recurrent pancreatitis due to benign vs. malignant strictures, and reported similar technical (75% vs. 100%) and clinical success (100% vs. 85.7%), with a nonsignificant difference in adverse events (overall 26.7%) [95]. Fujii *et al* reported the long-term outcomes of EUS-PDD in 23 patients with at least 12-month follow up. Complete clinical success with full symptom resolution occurred in 16 patients (69.6%) at the time of last follow up (median 37, range 12-72 months). Stents were removed after a median of 4 months, with symptom recurrence in 4 patients after a median of 14 (range 5-32) months [96]. Oh *et al* reported the long-term outcomes of EUS-PDD for management of anastomotic site strictures after Whipple surgery in 23 patients, after failed ERCP using FCSEMS. During a median follow up of 27.2 months, 5 patients (21.7%) developed late adverse events, including asymptomatic stent fracture at the gastric end (n=3) and stent migration (n=1). Only 1 patient with stent occlusion showed symptom recurrence [97]. Rana *et al* reported good outcomes of EUS-PDD in 21 patients with painful chronic pancreatitis after failed ERCP, over a mean follow-up period of 27.3±16.9 months. Twelve patients of this series underwent anterograde MPD drainage [98].

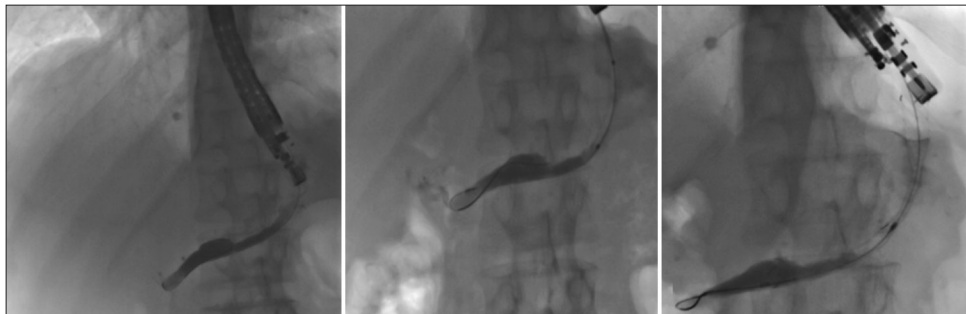


Figure 7 EUS guided transmural pancreatico-gastrostomy using fully covered SEMS in a patient with chronic pancreatitis and failed ERCP
EUS, endoscopic ultrasound; SEMS, self-expanding metal stents; ERCP, endoscopic retrograde cholangio-pancreatography

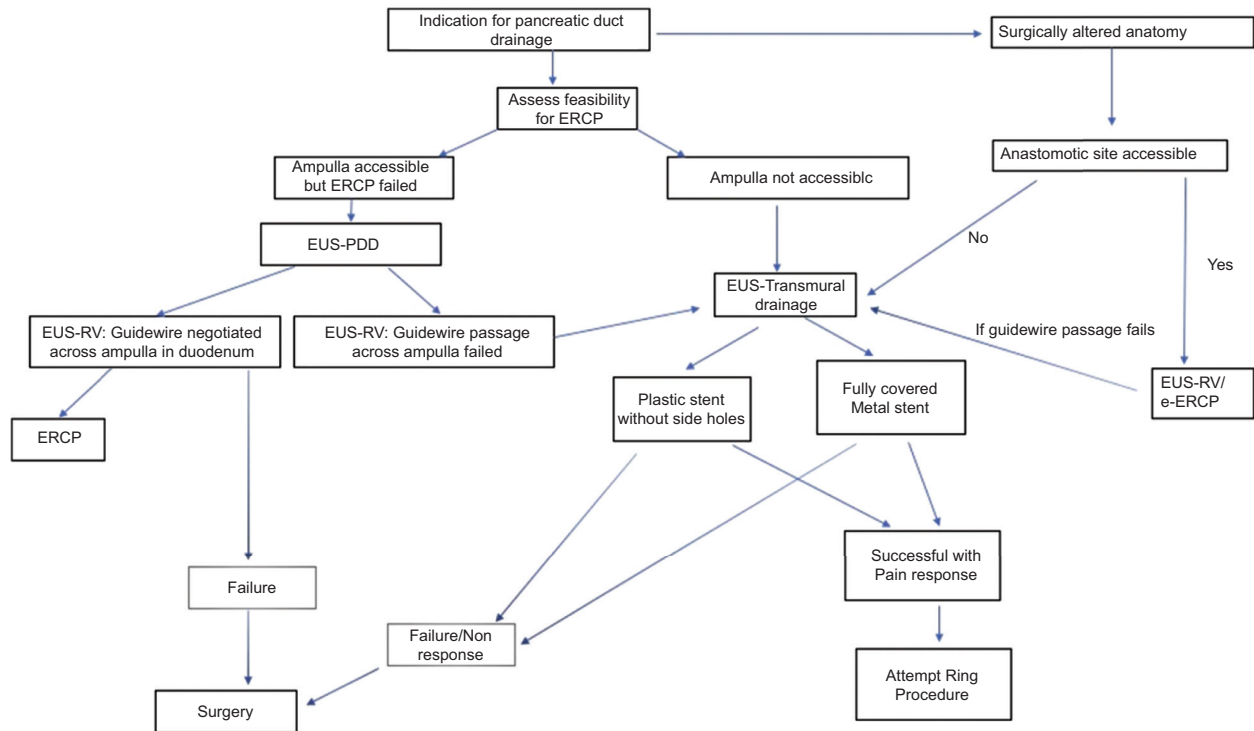


Figure 8 Algorithmic approach to EUS-PDD in a case with failed or not feasible ERCP
 EUS-PDD, endoscopic ultrasound guided pancreatic duct drainage; ERCP, endoscopic retrograde cholangio pancreatography

Algorithmic approach to EUS-PDD

We suggest the approach shown in Fig. 8 for a patient with MPD obstruction when traditional ERCP fails or is not feasible, provided the requisite expertise and backup are available. Standardization of techniques, more data from high volume centers and the development of dedicated accessories will help this procedure find wider acceptance as an alternative to a percutaneous approach or surgery.

References

- Coté GA, Singh S, Bucksot LG, et al. Association between volume of endoscopic retrograde cholangiopancreatography at an academic medical center and use of pancreatobiliary therapy. *Clin Gastroenterol Hepatol* 2012;**10**:920-924.
- Wiersema MJ, Sandusky D, Carr R, Wiersema LM, Erdel WC, Frederick PK. Endosonography-guided cholangiopancreatography. *Gastrointest Endosc* 1996;**43**:102-106.
- Giovannini M, Moutardier V, Pesenti C, Bories E, Lelong B, Delpero JR. Endoscopic ultrasound-guided bilioduodenal anastomosis: a new technique for biliary drainage. *Endoscopy* 2001;**33**:898-900.
- Burmester E, Niehaus J, Leineweber T, Huetteroth T. EUS-cholangio-drainage of the bile duct: report of 4 cases. *Gastrointest Endosc* 2003;**57**:246-251.
- Park SJ, Choi JH, Park DH, et al. Expanding indication: EUS-guided hepaticoduodenostomy for isolated right intrahepatic duct obstruction (with video). *Gastrointest Endosc* 2013;**78**:374-380.
- Iwashita T, Doi S, Yasuda I. Endoscopic ultrasound-guided biliary drainage: a review. *Clin J Gastroenterol* 2014;**7**:94-102.
- Sundaram S, Kale A. Endoscopic ultrasound guided biliary drainage in surgically altered anatomy: A comprehensive review of various approaches. *World J Gastrointest Endosc* 2023;**15**:122-132.
- Rana SS. Endoscopic ultrasound-guided gallbladder drainage: a technical review. *Ann Gastroenterol* 2021;**34**:142-148.
- Doyle JB, Sethi A. Endoscopic Ultrasound-Guided Biliary Drainage. *J Clin Med* 2023;**12**:2736.
- Honjo M, Itoi T, Tsuchiya T, et al. Safety and efficacy of ultra-tapered mechanical dilator for EUS-guided hepaticogastrostomy and pancreatic duct drainage compared with electrocautery dilator (with video). *Endosc Ultrasound* 2018;**7**:376-382.
- Nguyen-Tang T, Binmoeller KE, Sanchez-Yague A, Shah JN. Endoscopic ultrasound (EUS)-guided transhepatic antegrade self-expandable metal stent (SEMS) placement across malignant biliary obstruction. *Endoscopy* 2010;**42**:232-236.
- Shah JN, Marson F, Weilert F, et al. Single-operator, single-session EUS-guided antegrade cholangiopancreatography in failed ERCP or inaccessible papilla. *Gastrointest Endosc* 2012;**75**:56-64.
- Artifon EL, Safatle-Ribeiro AV, Ferreira FC, et al. EUS-guided antegrade transhepatic placement of a self-expandable metal stent in hepatico-jejunal anastomosis. *JOP* 2011;**12**:610-613.
- Park DH, Jang JW, Lee SS, Seo DW, Lee SK, Kim MH. EUS-guided transhepatic antegrade balloon dilation for benign bilioenteric anastomotic strictures in a patient with hepaticojunostomy. *Gastrointest Endosc* 2012;**75**:692-693.
- Park DH, Jeong SU, Lee BU, et al. Prospective evaluation of a treatment algorithm with enhanced guidewire manipulation protocol for EUS-guided biliary drainage after failed ERCP (with video). *Gastrointest Endosc* 2013;**78**:91-101.
- Sundaram S, Mane K, Patil P, et al. Endoscopic ultrasound-guided antegrade stent placement in patients with failed ERCP as a

- modality of preoperative and palliative biliary drainage. *Dig Dis Sci* 2023;**68**:1551-1558.
17. Iwashita T, Yasuda I, Doi S, et al. Endoscopic ultrasound-guided antegrade treatments for biliary disorders in patients with surgically altered anatomy. *Dig Dis Sci* 2013;**58**:2417-2422.
 18. Iwashita T, Uemura S, Mita N, et al. Endoscopic ultrasound guided-antegrade biliary stenting vs percutaneous transhepatic biliary stenting for unresectable distal malignant biliary obstruction in patients with surgically altered anatomy. *J Hepatobiliary Pancreat Sci* 2020;**27**:968-976.
 19. Tsuchiya T, Itoi T, Sofuni A, Tonozuka R, Mukai S. Endoscopic ultrasonography-guided rendezvous technique. *Dig Endosc* 2016;**28**(Suppl 1):96-101.
 20. Nakai Y, Isayama H, Matsubara S, et al. A novel "hitch-and-ride" deep biliary cannulation method during rendezvous endoscopic ultrasound-guided ERCP technique. *Endoscopy* 2017;**49**:983-988.
 21. Mallery S, Matlock J, Freeman ML. EUS-guided rendezvous drainage of obstructed biliary and pancreatic ducts: Report of 6 cases. *Gastrointest Endosc* 2004;**59**:100-107.
 22. Kahaleh M, Hernandez AJ, Tokar J, Adams RB, Shami VM, Yeaton P. Interventional EUS-guided cholangiography: evaluation of a technique in evolution. *Gastrointest Endosc* 2006;**64**:52-59.
 23. Maranki J, Hernandez AJ, Arslan B, et al. Interventional endoscopic ultrasound-guided cholangiography: long-term experience of an emerging alternative to percutaneous transhepatic cholangiography. *Endoscopy* 2009;**41**:532-538.
 24. Iwashita T, Lee JG, Shinoura S, et al. Endoscopic ultrasound-guided rendezvous for biliary access after failed cannulation. *Endoscopy* 2012;**44**:60-65.
 25. Dhir V, Bhandari S, Bapat M, Joshi N, Vivekanandarajah S, Maydeo A. Comparison of transhepatic and extrahepatic routes for EUS-guided rendezvous procedure for distal CBD obstruction. *United European Gastroenterol J* 2013;**1**:103-108.
 26. Iwashita T, Yasuda I, Mukai T, et al. EUS-guided rendezvous for difficult biliary cannulation using a standardized algorithm: a multicenter prospective pilot study (with videos). *Gastrointest Endosc* 2016;**83**:394-400.
 27. Dhir V, Bhandari S, Bapat M, Maydeo A. Comparison of EUS-guided rendezvous and precut papillotomy techniques for biliary access (with videos). *Gastrointest Endosc* 2012;**75**:354-359.
 28. Salerno R, Davies SEC, Mezzina N, Ardizzone S. Comprehensive review on EUS-guided biliary drainage. *World J Gastrointest Endosc* 2019;**11**:354-364.
 29. Tyberg A, Sarkar A, Shahid HM, et al. EUS-guided biliary drainage versus ERCP in malignant biliary obstruction before hepatobiliary surgery: an international multicenter comparative study. *J Clin Gastroenterol* 2023;**57**:962-966.
 30. Hara K, Yamao K, Niwa Y, et al. Prospective clinical study of EUS-guided choledochoduodenostomy for malignant lower biliary tract obstruction. *Am J Gastroenterol* 2011;**106**:1239-1245.
 31. Komaki T, Kitano M, Sakamoto H, Kudo M. Endoscopic ultrasonography-guided biliary drainage: evaluation of a choledochoduodenostomy technique. *Pancreatol* 2011;**11**(Suppl 2):47-51.
 32. Park DH, Jang JW, Lee SS, Seo DW, Lee SK, Kim MH. EUS-guided biliary drainage with transluminal stenting after failed ERCP: predictors of adverse events and long-term results. *Gastrointest Endosc* 2011;**74**:1276-1284.
 33. Artifon EL, Aparicio D, Paione JB, et al. Biliary drainage in patients with unresectable, malignant obstruction where ERCP fails: endoscopic ultrasonography-guided choledochoduodenostomy versus percutaneous drainage. *J Clin Gastroenterol* 2012;**46**:768-774.
 34. Khashab MA, Valeshabad AK, Modayil R, et al. EUS-guided biliary drainage by using a standardized approach for malignant biliary obstruction: rendezvous versus direct transluminal techniques (with videos). *Gastrointest Endosc* 2013;**78**:734-741.
 35. Kawakubo K, Isayama H, Kato H, et al. Multicenter retrospective study of endoscopic ultrasound-guided biliary drainage for malignant biliary obstruction in Japan. *J Hepatobiliary Pancreat Sci* 2014;**21**:328-334.
 36. Hara K, Yamao K, Hijioaka S, et al. Prospective clinical study of endoscopic ultrasound-guided choledochoduodenostomy with direct metallic stent placement using a forward-viewing echoendoscope. *Endoscopy* 2013;**45**:392-396.
 37. Rai P, Lokesh CR, Goel A, Aggarwal R. Endoscopic ultrasound-guided choledochoduodenostomy using partially-covered self-expandable metal stent in patients with malignant distal biliary obstruction and unsuccessful ERCP. *Endosc Int Open* 2018;**6**:E67-E72.
 38. Jacques J, Privat J, Pinard F, et al. Endoscopic ultrasound-guided choledochoduodenostomy with electrocautery-enhanced lumen-apposing stents: a retrospective analysis. *Endoscopy* 2019;**51**:540-547.
 39. Anderloni A, Fugazza A, Troncone E, et al. Single-stage EUS-guided choledochoduodenostomy using a lumen-apposing metal stent for malignant distal biliary obstruction. *Gastrointest Endosc* 2019;**89**:69-76.
 40. Ogura T, Itoi T. Technical tips and recent development of endoscopic ultrasound-guided choledochoduodenostomy. *DEN Open* 2021;**1**:e8.
 41. El Chafic AH, Shah JN, Hamerski C, et al. EUS-guided choledochoduodenostomy for distal malignant biliary obstruction using electrocautery-enhanced lumen-apposing metal stents: first US, multicenter experience. *Dig Dis Sci* 2019;**64**:3321-3327.
 42. Matsumoto S, Hara K, Mizuno N, et al. Risk factor analysis for adverse events and stent dysfunction of endoscopic ultrasound-guided choledochoduodenostomy. *Dig Endosc* 2020;**32**:957-966.
 43. Ogura T, Higuchi K. Technical tips of endoscopic ultrasound-guided choledochoduodenostomy. *World J Gastroenterol* 2015;**21**:820-828.
 44. de Benito Sanz M, Nájera-Muñoz R, de la Serna-Higuera C, et al. Lumen apposing metal stents versus tubular self-expandable metal stents for endoscopic ultrasound-guided choledochoduodenostomy in malignant biliary obstruction. *Surg Endosc* 2021;**35**:6754-6762.
 45. Teoh AYW, Napoleon B, Kunda R, et al. EUS-guided choledochoduodenostomy using lumen apposing stent versus ERCP with covered metallic stents in patients with unresectable malignant distal biliary obstruction: a multicenter randomized controlled trial (DRA-MBO Trial). *Gastroenterology* 2023;**165**:473-482.e472.
 46. Vanella G, Bronswijk M, Dell'Anna G, et al. Classification, risk factors, and management of lumen apposing metal stent dysfunction during follow-up of endoscopic ultrasound-guided choledochoduodenostomy: multicenter evaluation from the Leuven-Amsterdam-Milan Study Group. *Dig Endosc* 2023;**35**:377-388.
 47. Rana SS, Shah J, Bhujade H, Gorski U, Kang M, Gupta R. Prevention of serious complications during endoscopic ultrasound-guided biliary drainage: a case-based technical review. *J Dig Endosc* 2022;**13**:082-088.
 48. Attasaranya S, Netinasunton N, Jongboonyanuparp T, et al. The spectrum of endoscopic ultrasound intervention in biliary diseases: a single center's experience in 31 cases. *Gastroenterol Res Pract* 2012;**2012**:680753.
 49. Borjes E, Pesenti C, Caillol F, Lopes C, Giovannini M. Transgastric endoscopic ultrasonography-guided biliary drainage: results of a pilot study. *Endoscopy* 2007;**39**:287-291.
 50. Vila JJ, Pérez-Miranda M, Vazquez-Sequeiros E, et al. Initial experience with EUS-guided cholangiopancreatography for biliary and pancreatic duct drainage: a Spanish national survey. *Gastrointest Endosc* 2012;**76**:1133-1141.
 51. Poincloux L, Rouquette O, Buc E, et al. Endoscopic ultrasound-guided biliary drainage after failed ERCP: cumulative experience

- of 101 procedures at a single center. *Endoscopy* 2015;**47**:794-801.
52. Khashab MA, Messallam AA, Penas I, et al. International multicenter comparative trial of transluminal EUS-guided biliary drainage via hepatogastrostomy vs. choledochoduodenostomy approaches. *Endosc Int Open* 2016;**4**:E175-E181.
 53. Oh D, Park DH, Song TJ, et al. Optimal biliary access point and learning curve for endoscopic ultrasound-guided hepaticogastrostomy with transmural stenting. *Therap Adv Gastroenterol* 2017;**10**:42-53.
 54. Ogura T, Nishioka N, Ueno S, et al. Effect of echoendoscope angle on success of guidewire manipulation during endoscopic ultrasound-guided hepaticogastrostomy. *Endoscopy* 2021;**53**:369-375.
 55. Matsubara S, Nakagawa K, Suda K, Otsuka T, Oka M, Nagoshi S. Practical tips for safe and successful endoscopic ultrasound-guided hepaticogastrostomy: a state-of-the-art technical review. *J Clin Med* 2022;**11**:1591.
 56. Uemura RS, Khan MA, Otoch JP, Kahaleh M, Montero EF, Artifon ELA. EUS-guided choledochoduodenostomy versus hepaticogastrostomy: a systematic review and meta-analysis. *J Clin Gastroenterol* 2018;**52**:123-130.
 57. Li J, Tang J, Liu F, Fang J. Comparison of choledochoduodenostomy and hepaticogastrostomy for EUS-guided biliary drainage: a meta-analysis. *Front Surg* 2022;**9**:811005.
 58. Ogura T, Chiba Y, Masuda D, et al. Comparison of the clinical impact of endoscopic ultrasound-guided choledochoduodenostomy and hepaticogastrostomy for bile duct obstruction with duodenal obstruction. *Endoscopy* 2016;**48**:156-163.
 59. Giri S, Mohan BP, Jearth V, et al. Adverse events with EUS-guided biliary drainage: a systematic review and meta-analysis. *Gastrointest Endosc* 2023;**98**:515-523.e518.
 60. Choi JH, Lee SS, Choi JH, et al. Long-term outcomes after endoscopic ultrasonography-guided gallbladder drainage for acute cholecystitis. *Endoscopy* 2014;**46**:656-661.
 61. Law R, Grimm IS, Stavas JM, Baron TH. Conversion of percutaneous cholecystostomy to internal transmural gallbladder drainage using an endoscopic ultrasound-guided, lumen-apposing metal stent. *Clin Gastroenterol Hepatol* 2016;**14**:476-480.
 62. Tyberg A, Saumoy M, Sequeiros EV, et al. EUS-guided versus percutaneous gallbladder drainage: isn't it time to convert? *J Clin Gastroenterol* 2018;**52**:79-84.
 63. Irani S, Ngamruengphong S, Teoh A, et al. Similar efficacies of endoscopic ultrasound gallbladder drainage with a lumen-apposing metal stent versus percutaneous transhepatic gallbladder drainage for acute cholecystitis. *Clin Gastroenterol Hepatol* 2017;**15**:738-745.
 64. Ahmed O, Rogers AC, Bolger JC, et al. Meta-analysis of outcomes of endoscopic ultrasound-guided gallbladder drainage versus percutaneous cholecystostomy for the management of acute cholecystitis. *Surg Endosc* 2018;**32**:1627-1635.
 65. Issa D, Irani S, Law R, et al. Endoscopic ultrasound-guided gallbladder drainage as a rescue therapy for unresectable malignant biliary obstruction: a multicenter experience. *Endoscopy* 2021;**53**:827-831.
 66. Nakai Y, Kogure H, Isayama H, Koike K. Endoscopic ultrasound-guided biliary drainage for benign biliary diseases. *Clin Endosc* 2019;**52**:212-219.
 67. Mukai S, Itoi T, Sofuni A, et al. EUS-guided antegrade intervention for benign biliary diseases in patients with surgically altered anatomy (with videos). *Gastrointest Endosc* 2019;**89**:399-407.
 68. Hosmer A, Abdelfatah MM, Law R, Baron TH. Endoscopic ultrasound-guided hepaticogastrostomy and antegrade clearance of biliary lithiasis in patients with surgically-altered anatomy. *Endosc Int Open* 2018;**6**:E127-e130.
 69. Rerknimitr R, Angsuwatcharakon P, Ratanachu-ek T, et al. Asia-Pacific consensus recommendations for endoscopic and interventional management of hilar cholangiocarcinoma. *J Gastroenterol Hepatol* 2013;**28**:593-607.
 70. Sundaram S, Dhir V. EUS-guided biliary drainage for malignant hilar biliary obstruction: A concise review. *Endosc Ultrasound* 2021;**10**:154-160.
 71. Minaga K, Takenaka M, Kitano M, et al. Rescue EUS-guided intrahepatic biliary drainage for malignant hilar biliary stricture after failed transpapillary re-intervention. *Surg Endosc* 2017;**31**:4764-4772.
 72. Kongkam P, Orprayoon T, Boonmee C, et al. ERCP plus endoscopic ultrasound-guided biliary drainage versus percutaneous transhepatic biliary drainage for malignant hilar biliary obstruction: a multicenter observational open-label study. *Endoscopy* 2021;**53**:55-62.
 73. Khashab MA, El Zein MH, Sharzei K, et al. EUS-guided biliary drainage or enteroscopy-assisted ERCP in patients with surgical anatomy and biliary obstruction: an international comparative study. *Endosc Int Open* 2016;**4**:E1322-E1327.
 74. Cahen DL, Gouma DJ, Nio Y, et al. Endoscopic versus surgical drainage of the pancreatic duct in chronic pancreatitis. *N Engl J Med* 2007;**356**:676-684.
 75. Gobien RP, Stanley JH, Anderson MC, Vujic I. Percutaneous drainage of pancreatic duct for treating acute pancreatitis. *AJR Am J Roentgenol* 1983;**141**:795-796.
 76. Dalsania R, Shah R, Rana S, Chawla S. Endoscopic ultrasound-guided management of chronic pancreatitis. *Curr Gastroenterol Rep* 2020;**22**:34.
 77. Adams DB, Ford MC, Anderson MC. Outcome after lateral pancreaticojejunostomy for chronic pancreatitis. *Ann Surg* 1994;**219**:481-487; discussion 487-489.
 78. Zarzavadjian Le Bian A, Cesaretti M, Tabchouri N, Wind P, Fuks D. Late pancreatic anastomosis stricture following pancreaticoduodenectomy: a systematic review. *J Gastrointest Surg* 2018;**22**:2021-2028.
 79. Chen YL, Levy MJ, Moreels TG, et al. An international multicenter study comparing EUS-guided pancreatic duct drainage with enteroscopy-assisted endoscopic retrograde pancreatography after Whipple surgery. *Gastrointest Endosc* 2017;**85**:170-177.
 80. Kogure H, Sato T, Nakai Y, et al. Endoscopic management of pancreatic diseases in patients with surgically altered anatomy: clinical outcomes of combination of double-balloon enteroscopy- and endoscopic ultrasound-guided interventions. *Dig Endosc* 2021;**33**:441-450.
 81. Teh JL, Teoh AYB. Techniques and outcomes of endoscopic ultrasound guided-pancreatic duct drainage (EUS- PDD). *J Clin Med* 2023;**12**:1626.
 82. Chandan S, Mohan BP, Khan SR, et al. Efficacy and safety of endoscopic ultrasound-guided pancreatic duct drainage (EUS-PDD): A systematic review and meta-analysis of 714 patients. *Endosc Int Open* 2020;**8**:E1664-E1672.
 83. Bhurwal A, Tawadros A, Mutneja H, et al. EUS guided pancreatic duct decompression in surgically altered anatomy or failed ERCP - A systematic review, meta-analysis and meta-regression. *Pancreatol* 2021;**21**:990-1000.
 84. Tyberg A, Bodiwala V, Kedia P, et al. EUS-guided pancreatic drainage: A steep learning curve. *Endosc Ultrasound* 2020;**9**:175-179.
 85. Nakai Y, Kogure H, Isayama H, Koike K. Endoscopic ultrasound-guided pancreatic duct drainage. *Saudi J Gastroenterol* 2019;**25**:210-217.
 86. Abdelqader A, Kahaleh M. When ERCP fails: EUS-guided access to biliary and pancreatic ducts. *Dig Dis Sci* 2022;**67**:1649-1659.
 87. Imoto A, Ogura T, Higuchi K. Endoscopic ultrasound-guided pancreatic duct drainage: techniques and literature review of transmural stenting. *Clin Endosc* 2020;**53**:525-534.
 88. Nakai Y, Kogure H, Koike K. Double-guidewire technique for endoscopic ultrasound-guided pancreatic duct drainage. *Dig Endosc* 2019;**31**(Suppl 1):65-66.

89. Krafft MR, Nasr JY. Anterograde endoscopic ultrasound-guided pancreatic duct drainage: a technical review. *Dig Dis Sci* 2019;**64**:1770-1781.
90. Oh D, Park DH, Cho MK, et al. Feasibility and safety of a fully covered self-expandable metal stent with antimigration properties for EUS-guided pancreatic duct drainage: early and midterm outcomes (with video). *Gastrointest Endosc* 2016;**83**:366-373.e362.
91. Will U, Reichel A, Fuehdner F, Meyer F. Endoscopic ultrasonography-guided drainage for patients with symptomatic obstruction and enlargement of the pancreatic duct. *World J Gastroenterol* 2015;**21**:13140-13151.
92. Rana SS, Sharma R, Gupta R. Endoscopic treatment of refractory external pancreatic fistulae with disconnected pancreatic duct syndrome. *Pancreatol* 2019;**19**:608-613.
93. van der Merwe SW, van Wanrooij RLJ, Bronswijk M, et al. Therapeutic endoscopic ultrasound: European Society of Gastrointestinal Endoscopy (ESGE) Guideline. *Endoscopy* 2022;**54**:185-205.
94. Dalal A, Patil G, Maydeo A. Six-year retrospective analysis of endoscopic ultrasonography-guided pancreatic ductal interventions at a tertiary referral center. *Dig Endosc* 2020;**32**:409-416.
95. Uchida D, Kato H, Saragai Y, et al. Indications for endoscopic ultrasound-guided pancreatic drainage: for benign or malignant cases? *Can J Gastroenterol Hepatol* 2018;**2018**:8216109.
96. Fujii LL, Topazian MD, Abu Dayyeh BK, et al. EUS-guided pancreatic duct intervention: outcomes of a single tertiary-care referral center experience. *Gastrointest Endosc* 2013;**78**:854-864.e851.
97. Oh D, Park DH, Song TJ, et al. Long-term outcome of endoscopic ultrasound-guided pancreatic duct drainage using a fully covered self-expandable metal stent for pancreaticojejunal anastomosis stricture. *J Gastroenterol Hepatol* 2020;**35**:994-1001.
98. Rana SS, Sharma R, Gupta R. EUS-guided transmural pancreatic duct interventions for relief of pain in patients with chronic pancreatitis and failed ERCP. *Endosc Ultrasound* 2020;**9**:274-275.