

*Case report***Isolated Crohn's disease of the vermiform appendix or chronic granulomatous appendicitis?**

E.Tsianos, K. Katsanos, G. Mpaltayiannis, D. Christodoulou

SUMMARY

The etiology of granulomatous appendicitis includes infectious diseases, foreign bodies and diseases of unknown etiology such as Crohn's disease and sarcoidosis. Pain in the right lower quadrant is a common symptom of intestinal Crohn's disease but, pain in this area can also be the presenting symptom of acute appendicitis. Crohn's disease affects any part of the gastrointestinal tract including the vermiform appendix. Crohn's disease initially confined to the appendix is rare and there are less than 100 well-documented cases in the literature. A 28-years-old female patient was admitted to our hospital because of fever up to 39°C and abdominal pain in the right lower quadrant with bloating. Serology and faecal, urine and blood cultures for microbial infection including *Yersinia* proved negative. Lower abdomen ultrasonography revealed no evidence of adnexae inflammation but suspected thickness of the bowel wall in the right lower quadrant. Because of no response to conservative treatment two months later surgery was performed. At laparotomy a long, thickened and distended appendix was found and removed. No other lesions were noted in the intestines or mesentery. Histological examination of the removed appendix showed signs compatible with Crohn's disease of the appendix. In case of Crohn's disease of the appendix two clinical possibilities may arise; the first is the presence of mild Crohn's disease in other intestinal parts and the second possibility is the risk of relapse which occurred in 7-14% of the published cases. Could

this case be regarded as an isolated Crohn's disease of the appendix or as a granulomatous and follicular appendicitis of unknown etiology (idiopathic) and unrelated to a "formal" Crohn's disease according to the accepted definition.

Key words: Crohn's disease, appendix, granuloma, appendicitis

INTRODUCTION

The etiology of granulomatous appendicitis includes infectious diseases, foreign bodies and diseases of unknown etiology such as Crohn's disease and sarcoidosis. Pain in the right lower quadrant is a common symptom of intestinal Crohn's disease^{1,2}, but pain in this area can also be the presenting symptom of acute appendicitis. For this reason, right lower quadrant pain has frequently been the cause of diagnostic dilemmas because patients with Crohn's disease seem to have the same risk for developing acute suppurative appendicitis as healthy subjects. Crohn's disease affects any part of the gastrointestinal tract including the vermiform appendix. The appendix was involved in about one quarter of terminal ileum Crohn's disease cases, and simultaneous involvement of other bowel parts has also been reported.³ Crohn's disease initially confined to the appendix is rare and there are less than 100 well-documented cases in the literature.⁴⁻⁷ In these cases, granulomatous process was apparently limited to an inflamed and swollen appendix, while the remaining intestine seemed macroscopically normal. When Crohn's disease is initially confined to the appendix it seems to have a much lower recurrence rate than that of the disease affecting other bowel parts.⁸

Department of Internal Medicine, Medical School University of Ioannina

Author for correspondence:

Epameinondas Tsianos, Professor of Medicine-Gastroenterology, Medical School University of Ioannina, Greece, Tel: 003-0651-99736, 99617, Fax: 003-0651-99736, e-mail: etsianos@cc.uoi.gr

¹This paper was announced at the 1st European Congress on Gastrointestinal Oncology, 22-25 June 2000

CASE REPORT

A 28-years-old female patient was admitted to our Hospital because of fever up to 39°C and abdominal pain in the right lower quadrant with bloating. There was previous medical history of recurrent right salpingitis. Palpation of the abdomen caused guarding and rebound tenderness in the right lower quadrant with no palpable mass. Rectal examination revealed mild tenderness on the right side. Laboratory examination showed hematocrit 36.5%, hemoglobin 11.8 gr/dl, white blood cell count 16.900/mm³ with polymorphonuclear predominance, ESR 62 mm/h. Serology and faecal, urine and blood cultures for microbial infection including negative serology and multiple fecal cultures for *Yersinia* proved negative. Lower abdomen ultrasonography revealed no evidence of adnexae inflammation but suspected thickness of the bowel wall in the right lower quadrant. Further investigation with barium enema examination and enteroclysis revealed edematous mucosa, with evidence of ileocecal valve cobblestoning and appendical orifice and caecum involvement (Figure 1).

Abdominal computed tomography showed phlegmon

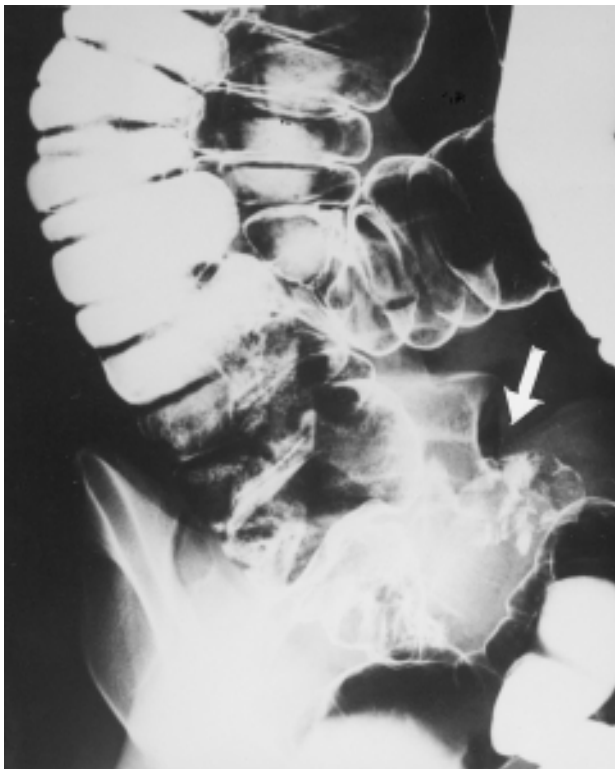

Figure 1. Oedema and cobblestoning of the caecum and ileocaecal valve.

of the appendix and colonoscopy revealed nodular lesions and oedematous mucosa of the appendical orifice. No other lesions were seen in the ileum or in the ileocaecal valve. Biopsies taken from the orifice of the appendix, showed histological signs compatible with granulomatous inflammation with no crypt distortion and no marked goblet cell depletion. Moreover capillary congestion and diffuse inflammatory cell infiltrate throughout the lamina propria and granulomata without caseating necrosis were also present (Figure 2). Further histological evaluation with PAS, Ziehl-Nielsen and Gram stain was negative and there was no evidence of fungal involvement in the biopsy specimen. Because of no response to conservative treatment, two months later surgery was performed. At laparotomy a long, thickened and distended appendix was found and removed. No other lesions were noted in the intestines or mesentery. Histological examination of the removed appendix showed signs compatible with Crohn's disease of the appendix with fissuring and transmural inflammations, ulcerations and numerous granulomata in the mucosa submucosa and muscularis. The patient recovered and remains symptom-free 8 years after surgery.

DISCUSSION

Crohn's disease diagnosis is based on a combination of clinical, radiologic endoscopic findings and histologic findings. When morphologic features of Crohn's disease are isolated to the appendix, diagnosis is based only on histological criteria. In such cases the pathologists tend to support diagnosis based on the presence of granulomas, which seems to be one of the specific histologic fea-

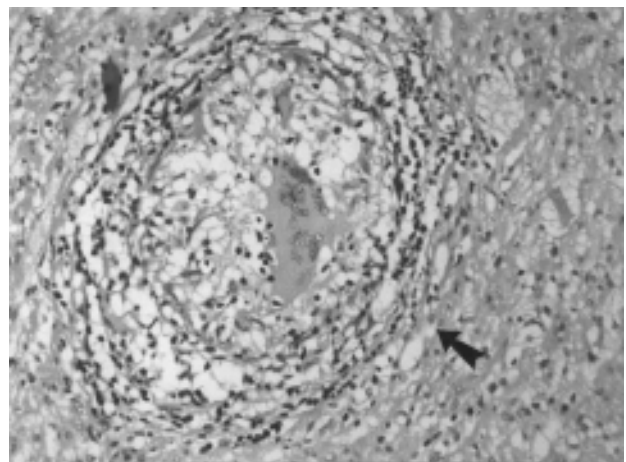


Figure 2. Granuloma in appendix region (E and H x 200).

tures of Crohn's disease. In our patient all known infectious diseases were excluded as well as the presence of foreign bodies in the appendix. The history of recurrent right salpingitis might have just been an epiphenomenon to this regional bowel inflammation because after surgical intervention it never reappeared. Gastrointestinal sarcoidosis is uncommon and even more rare is appendicular sarcoidosis. In sarcoidosis other organs are also involved with non-caseating granulomas, which was not evident in this case. The granulomas of tuberculosis are more numerous and larger and have necrosis and acid-fast demonstrable by Ziehl-Nielsen stain. Rarely granulomatous appendicitis may be the result of a Yersinia infection but this possibility was excluded.

In case of Crohn's disease of the appendix two clinical possibilities may arise; the first is the presence of mild Crohn's disease in other intestinal parts and this may happen to 11-25% of patients. The second possibility is the risk of relapse which occurred in 7-14% of the published cases.^{6,7,9,10} Of interest is the much lower recurrence rate among these patients than in those with extended intestinal Crohn's disease after primary excisional surgery (7-14% vs 34-58%).^{11,12} The rate is comparable to that of colonic Crohn's disease (16%).¹³

In our case, inflammation of vermiform appendix was histologically suggestive of localized Crohn's disease. Disease was isolated to the appendix with no evidence of concurrent Crohn's disease elsewhere in the gastrointestinal tract or recurrence of the disease so far (8 years). Could this case be regarded as an isolated Crohn's disease of the appendix or is this a granulomatous and follicular appendicitis of unknown etiology (idiopathic^{15,16}) and unrelated to a "formal" Crohn's disease as it is classically defined?⁷ The rarity of granulomatous appendicitis¹⁷ and the relatively mild Crohn's disease profile in our area make this case a real dilemma. The answering options seem to be more than one in this case and in many other so far described cases¹⁸ and the general term "granulomatous appendicitis" is sometimes preferable.

REFERENCES

1. Dyer NH, Dawson AM. Diagnosis in Crohn's disease: a continuing course of error. *Br Med J* 1970; 1:735-738.
2. Hellers G. Crohn's disease in Stockholm county, 1955-

1974. A study of epidemiology, results of surgical treatment and long term prognosis. *Acta Chir Scand (Suppl)* 1979; 490:1.
3. Warren S, Sommers SG. Cicatrizing enteritis (regional ileitis) as a pathologic entity: analysis of one hundred and twenty cases. *Am J Pathol* 1948; 24:475-501.
4. Hollings RM. Crohn's disease of the appendix. *Med J Aust* 1964; 1:639-641.
5. Treatt B, Applemans H. Crohn's disease of the appendix presenting as acute appendicitis. Report of 3 cases with review of the literature. *Radiology* 1974; 110:313-316.
6. Allen DC, Biggart JD. Granulomatous disease in the vermiform appendix. *J Clin Pathol* 1983; 36:632-638.
7. Ariel I, Vinograd I, Hershlag A, Olsha O, Argov S, Klausner JM, et al. Crohn's disease isolated to the appendix. Truths and fallacies. *Hum Pathol* 1986; 17:1116-1121.
8. Price AB, Morson BC. Inflammatory bowel disease. The surgical pathology of Crohn's disease and ulcerative colitis. *Hum Pathol* 1975; 6:7-10.
9. Yang SS, Givson P, McCaughey RS, Arcari FA, Bernstein J. Primary Crohn's disease of the appendix. Report of 14 cases and review of the literature. *Ann Surg* 1979; 189:334-339.
10. De Dombal FT, Burton I, Goligher JC. Recurrence of Crohn's disease after primary excisional surgery. *Gut* 1971; 12:519-523.
11. Creenstein AJ, Sachar DB, Pasternack BS, Janowitz HC. Reoperation and recurrence in Crohn's colitis and ileocolitis. Grude and cumulative rates. *N Engl J Med* 1975; 293:685-689.
12. Farmer RG, Hawk WA, Turnbull RB. Clinical patterns in Crohn's disease: A statistical study of 615 cases. *Gastroenterology* 1975; 68:627-632.
13. MacLeod JB, Jenkins AM, Gill W. Sarcoidosis involving the vermiform appendix. *JR Coll. Surg Edinb.* 1965; 10:319-323.
14. Scully RE, Mark EJ, McNeely WF, Ebeling SH. Case records of the Massachusetts General Hospital (case 10-1996). *N Engl J Med* 1996; 334 (No 13):849-854.
15. Dudley TH, Dean PJ. Idiopathic granulomatous appendicitis, or Crohn's disease of the appendix revisited. *Hum Pathol* 1993; 24:595-601.
16. Hall JH, Hellier MD. Crohn's disease of the appendix presenting as acute appendicitis. *Br J Surg* 1969; 5:390-392.
17. Richards ML, Aberger FJ, Landercasper J. Granulomatous appendicitis: Crohn's disease, atypical Crohn's or not Crohn's at all? *J Am Coll Surg* 1997; 185:13-17.
18. Koutroubakis I, Tzardi M, Zois E, Spiropoulos Ch, Mouzas I, Manousos O. Granulomatous appendicitis: a clinical and epidemiological study in Crete. *Eur J Gastroenterol Hepatol* 1993; 5:1061-1065.