

## Case Report

# Autoimmune hepatitis, 2 years after successful peg-interferon-alpha 2b plus ribavirin treatment in a patient with chronic hepatitis C

K.G. Petropoulou,<sup>1</sup> S.P. Dourakis,<sup>1</sup> J. Delladetsima,<sup>2</sup> A.J. Archimandritis<sup>1</sup>

## SUMMARY

A 76-year old female patient with chronic hepatitis C virus (HCV) infection successfully treated with pegylated interferon- alpha 2b plus ribavirin four years ago who developed autoimmune hepatitis (AIH) is described. The patient presented with jaundice and worsening of liver function tests during the last two years. HCV-RNA was negative. Diagnosis was assessed according to the international AIH scoring system, including liver biopsy and confirmed by positive response to steroid challenge. We hypothesize that pegylated interferon triggered an immune-mediated hepatitis. We suggest long term follow up of the patients with sustained virological response after treatment for chronic HCV infection.

**Keywords:** Chronic hepatitis C; Interferon; Autoimmune hepatitis

## 1. INTRODUCTION

Interferon (IFN) is a cytokine produced by different cell types of the immune system. IFN plays a crucial role in immune response by activating natural killer cells, macrophages and cytotoxic T cells and by upregulating the expression of MHC.<sup>1</sup> IFN has been introduced as a therapeutic choice for several neoplasias and has been established in the treatment of HBV and HCV hepatitis. The current recommended therapy for chronic HCV infection is the combination of pegylated interferon and ribavirin.<sup>2</sup>

<sup>1</sup>2<sup>nd</sup> Department of Medicine, University of Athens, Medical School, Hippokration General Hospital, Greece, <sup>2</sup>1<sup>st</sup> Department of Pathology, University of Athens, Medical School, Greece

### Author for correspondence:

Konstantina G. Petropoulou, Address: 19, Armatolon str, TK 16344, Athens, Greece, Tel:+30 210-9702113, Fax:+30 210-9702113, E-mail address: konspetropoulou@yahoo.com

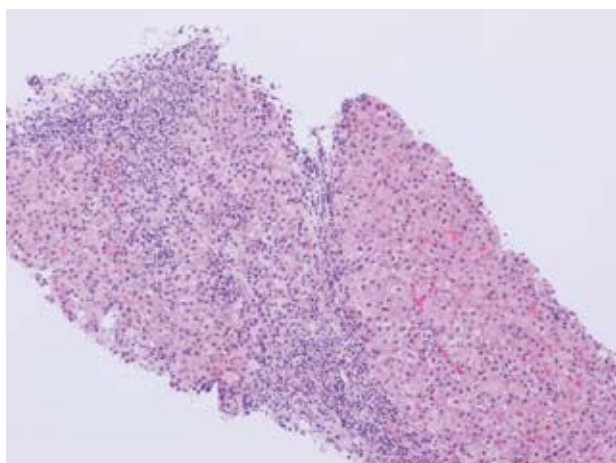
The use of IFN- $\alpha$  therapy in chronic HCV infection can induce autoimmune reactions<sup>3</sup> occasionally leading to overt autoimmune disorders such as thyroiditis, diabetes mellitus, lupus erythematosus-like syndrome, haemolytic anaemia, immune-mediated thrombocytopenia, as well as autoimmune hepatitis.<sup>4</sup> Autoimmune hepatitis following chronic hepatitis C infection therapy seems to be a rare complication.<sup>9,11</sup>

Herein we report a case of autoimmune hepatitis induced by pegylated interferon 2 years after successful treatment of chronic HCV infection.

## 2. CASE REPORT

A 76-year-old woman presented in February 2009, with jaundice, dark urine, fatigue, excessive elevation of serum transaminases, hypoalbuminemia and prolongation of INR, PT, and aPTT. The patient had a history of sporadic HCV genotype 2a/2c infection treated successfully for a period of 48 weeks with pegylated interferon-alpha 2b plus ribavirin 4 years ago. Since then, HCV-RNA was found repeatedly negative. In addition she had hypertension and hypothyroidism with positive antithyroid autoantibodies. There was no family history of autoimmune diseases, she did not consume any alcohol and the only medications she was receiving was atenolol for hypertension and levothyroxine sodium for hypothyroidism. One year and 3 months after chronic HCV infection treatment, antinuclear antibodies (ANA) were found positive in a titer of 1:320, while during the last 2 years serum transaminases levels were increased. The patient was followed by her general practitioner.

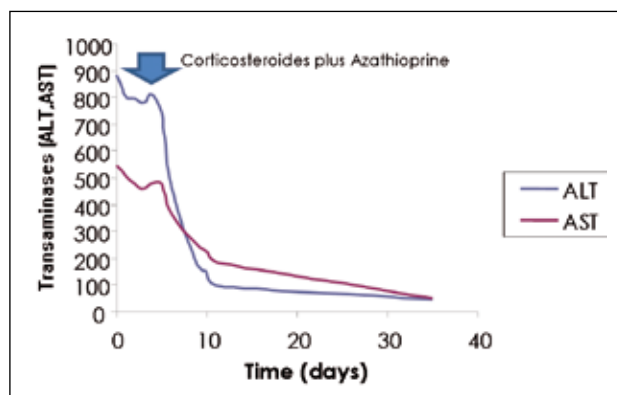
By the time of admission to our hospital serum aspartate aminotransferase (AST) was 546 IU/L (normal < 40 IU/L), serum alanine aminotransferase (ALT) was 882



**Figure 1.** Liver biopsy showing two cirrhotic nodules with severe interface hepatitis. (H&E stain 200 X).

IU/L (normal < 40 IU/L), bilirubin 4,50 mgr/dL (normal < 1,00), albumin 3,00 g/dL (normal 3.5-5.1) and INR: 1,7.

Laboratory serological findings excluded hepatitis A and B, CMV and EBV. Anti-HCV was positive and HCV-RNA was negative tested by polymerase chain reaction (Roche Amplicor-COBAS, sensitivity level: 615 IU/ml). The level of  $\alpha$ 1-antitrypsin was normal and there was no evidence of Wilson's disease or haemochromatosis. Serum electrophoresis showed a significant elevation of the  $\gamma$ -globulin fraction. Serum IgG was markedly elevated 5590 mg/dl (normal: 700-1600 mgr/dl), IgA 150 mg/dl (normal: 70-400 mgr/dl) and IgM 298 mg/dl (normal: 40-230 mgr/dl). ANA were positive in a titer 1:1280, antibodies against smooth muscle cells (ASMA) and antibodies against soluble liver antigen (anti-SLA) were also detectable. Antimitochondrial antibodies (AMA) and



**Figure 2.** Evolution of serum liver aminotransaminases (ALT, AST) during hospitalisation, after initiation of treatment and follow-up period.

antibodies against liver kidney microsomes (anti-LKM) were absent.

Imaging studies including abdominal ultrasound and CT were normal, transient elastometry evaluation (FibroScan®) indicated liver fibrosis (35, 8 Kpa) and endoscopy of the upper alimentary track revealed portal gastropathy.

The histological examination of the liver biopsy revealed micronodular cirrhosis with severe chronic hepatitis, characterized by dense portal/periportal plasmacytic predominant inflammatory infiltrates, severe interface hepatitis, multiple focal and occasional confluent bridging hepatocellular necrosis. (Fig. 1).

Autoimmune hepatitis was assessed by applying the international AIH scoring system (>15) suggesting “definite AIH” and treatment with corticosteroids and azathioprine was initiated. A decline of hepatic serum transaminases (Fig. 2) was observed within a few days and the prednisone dosage was gradually tapered.

One month later bilirubin and ALT levels were within the normal limits.

### 3. DISCUSSION

The present case concerns a female patient who developed autoimmune hepatitis-cirrhosis 2 years after successful treatment for chronic HCV infection.

The immunogenic activity of INF may trigger the emergence, exacerbation or de novo manifestation of autoimmune diseases including autoimmune hepatitis. The occurrence of autoimmune hepatitis has been described in patients receiving IFN for multiple sclerosis,<sup>5</sup> chronic myeloid leukemia<sup>6,7</sup> and malignant melanoma.<sup>8</sup>

In patients with chronic HCV infection the use of IFN- $\alpha$  has been implicated in the development of diverse autoimmune disorders, their prevalence ranging between 4%-19%.<sup>9</sup> Within this setting the appearance of autoimmune hepatitis is an expected complication while a number of reports<sup>10,11,12,13, 14,15</sup> provide evidence of its association with IFN- $\alpha$ . Moreover sporadic case reports refer to the development of autoimmune hepatitis in liver grafts after chronic hepatitis C recurrence treated with IFN<sup>16, 17,18,19</sup> and in HIV-HCV co-infection after successful treatment with IFN.<sup>20,21</sup>

The correlation of chronic HCV infection with autoimmunity is well known. The epiphenomenon of autoantibodies generation<sup>22</sup> and in particular the relationship of chronic hepatitis C with a variety of autoimmune diseases reflects disturbances in self tolerance due to the molecular

mimicry between viral proteins and autoantigens.<sup>23</sup> Hepatitis C virus is thought to be involved in the pathogenesis of autoimmune hepatitis type 2 by the presence of anti LKM-1 directed mainly against cytochrome P450IID6 and by autoreactive liver infiltrating T cells.<sup>24</sup>

One may assume, that HCV related deficient self tolerance renders patients with chronic hepatitis C more susceptible to autoimmune reactions under the immunostimulatory impact of IFN. Our patient combines the aforementioned risk factors and in addition a background of autoimmune diathesis due to the appearance of positive antithyroid autoantibodies.

What differentiates our case from those reported in the literature is the time interval between cessation of treatment and the appearance of autoimmune hepatitis. To our knowledge, none of the reported cases of autoimmune hepatitis occurred such a long time after successful treatment of chronic hepatitis C with pegylated interferon and ribavirin. In the reviewed literature IFN-induced autoimmune hepatitis developed during or short after discontinuation of therapy. In our patient, autoimmune hepatitis appeared nearly 2 years after virus clearance.

The delayed manifestation does not rule out the synergistic effect of a co-stimulatory factor in the post-treatment period.

Immunosuppressive treatment, including corticosteroids with or without azathioprine, is the treatment of choice for autoimmune hepatitis and achieves remission ranging from 65% to 80% of cases.<sup>25</sup> Our patient showed a very good response to corticosteroids and azathioprine.

In conclusion, autoimmune hepatitis although a rare complication of IFN- $\alpha$  therapy, should be considered as a possible cause of liver dysfunction in patients with previous successful IFN treatment for HCV hepatitis, suggesting the importance of long term follow-up after sustained virological response, at least in those patients with underlying autoimmune diathesis.

## REFERENCES

- Samuel CE. Antiviral actions of interferons. *Clin Microbiol Rev* 2001;14:778-809
- Hoofnagle JH, Seeff LB. Peginterferon and Ribavirin for Chronic Hepatitis C. *N. Engl. J. Med.* 2006 7; 355: 2444-2451.
- Conrad B. Potential mechanisms of interferon-alpha induced autoimmunity. *Autoimmunity* 2003;36:519-523
- Krause I, Valesini G, Scrivo R, Shoenfeld Y. Autoimmune aspects of cytokine and anticytokine therapies. *Am J Med* 2003;115:390-397
- Durelli L, Bongioanni MR, Ferrero B, Oggero A, Marzano A, Rizzetto M. Interferon treatment for multiple sclerosis: Autoimmune complications may be lethal. *Neurology* 1998;50:570-571
- Steegmann JL, Requena MJ, Garcia-Buey ML, Granados E, Romero R, Fernandez-Ranada JM, et al. Severe autoimmune hepatitis in a chronic myeloid leukaemia patient treated with interferon-alpha and with complete genetic response. *Am J Hematol* 1998;59:95-97
- Steegmann JL, Requena MJ, Martin-Regueira P, de la Cámara R, Casado F, Rodriguez Salvanés F, et al. High incidence of autoimmune alterations in chronic myeloid leukemia patients treated with interferon-alpha. *Am J Hematol* 2003;72:170-176
- Lebiedz P, August C, Domschke W, Schmidt HH. Interferon (IFN) for malignant melanoma unmasking an autoimmune hepatitis. *Eur J Inter Med* 2009; 20:e 3-4
- Garcia-Buey L, Garcia-Monzon C, Rodriguez S, Borque MJ, Garcia-Sanchez A, Iglesias R, et al. Latent autoimmune hepatitis triggered during interferon therapy in patients with chronic hepatitis C. *Gastroenterology* 1995;108: 1770-1777
- Kogure T, Ueno K, Fukushima K, Nagasaki F, Inoue J, Kakuza E, et al. Fulminant hepatic failure in a case of autoimmune hepatitis in hepatitis C during peg-interferon-alpha 2b plus ribavirin treatment. *World J Gastroenterology* 2007; 13:4394-4397
- Lorke J, Erhardt A, Haussinger D. Induction of autoimmune hepatitis by pegylated interferon alpha-2b in chronic hepatitis C. *Clin Gastroenterol Hepatol* 2004;2(12):xx
- Shindo M, Di Bisceglie AM, Hoofnagle JH. Acute exacerbation of liver disease during interferon alpha therapy for chronic hepatitis C. *Gastroenterology* 1992;102:1406-1408
- Papo T, Marcellin P, Bernuau J, Durand F, Poinard T, Benhemou JP. Autoimmune chronic hepatitis exacerbated by alpha-interferon. *Ann Intern Med* 1992; 116:51-53
- Eisenburg J. Interferon or C virus-induced autoimmune chronic hepatitis? Report of personal observations and review of the literature. *Fortschr Med* 1994; 112:317-21
- Ruiz-Moreno M, Ruá MJ, Carreño V, Quiroga JA, Manns M, Meyer zum Büschenfelde KH. Autoimmune chronic hepatitis type 2 manifested during interferon therapy in children. *J. Hepatol* 1991; 12:265-266
- Merli M, Gentili F, Giusto M, Attili AF, Corradini SG, Menzini G, et al. Immune-mediated liver dysfunction after antiviral treatment in liver transplanted patients with hepatitis c: Allo or autoimmune de novo hepatitis? *Dig Liver Dis* 2009; 41:345-349.
- Berardi S, Lodato F, Gramenzi A, D'Errico A, Lenzi M, Bonfadini A, et al. High incidence of allograft dysfunction in liver transplanted patients treated with pegylated-interferon alpha-2b and ribavirin for hepatitis C recurrence: possible de novo autoimmune hepatitis? *Gut* 2007; 56:237-242
- Cholongitas E, Samonakis D, Patch D, Senzolo M, Burroughs AK, Quaglia A, et al. Induction of autoimmune hepatitis by pegylated interferon in a liver transplant patient with recurrent hepatitis C virus. *Transplantation* 2006; 15:488-490
- Kontorinis N, Agarwal K, Elhadj N, Fiel MI, Schiano TD.

- Pegylated interferon-induced immune-mediated hepatitis post-liver transplantation *Liver Transpl* 2006 ;12:827-830
20. Coriat R, Podevin P. Fulminant autoimmune hepatitis after successful interferon treatment in an HIV-HCV co-infected patient. *Int J STD AIDS* 2008 ;19:208-210
  21. Vispo E, Maida I, Moreno A, Barreiro P, Soriano V. Autoimmune hepatitis induced by pegylated interferon in an HIV-infected patient with chronic hepatitis C. *J Antimicrob Chemother* 2008; 62:1470-1472
  22. Zauli D, Cassani F, Bianchi FB. Auto-antibodies in hepatitis C. *Biomed Pharmacother* 1999;53:234-241
  23. Bianchi FB, Muratori P, Granito A, Pappas G, Ferri S, Muratori L. Hepatitis C and autoreactivity. *Dig Liver Dis* 2007;1: S22-24
  24. Kammer AR, van de Burg SH, Grabscheid B, Hunziker IP, Kwappenberg KM, Reichen J, et al. Molecular mimicry of human cytochrome P450 by hepatitis C virus at the level of cytotoxic T cell recognition. *J Exp Med* 1999; 190:169-176
  25. Krawitt EL. Clinical features and management of autoimmune hepatitis. *World J Gastroenterology* 2008; 14:3301-3305.