

# Complicated hepatic hydatid cyst with simultaneous biliary tree and intraperitoneal rupture: can we treat it in a minimally invasive way?

Georgios Germanidis<sup>a</sup>, Konstantinos Mantzoukis<sup>a</sup>, Tasos Kelekis<sup>b</sup>, Eleni Doumaki<sup>c</sup>, Konstantinos Vasiliou<sup>a</sup>, Ioannis Kokinakis<sup>c</sup>, Pantelis Zebekakis<sup>c</sup>, Pavlos Nikolaidis<sup>c</sup>

Aristotle University of Thessaloniki Medical School, Thessaloniki, Greece

## Abstract

We report a case of complicated liver hydatid cyst with biliary system communication, cholangitis, and having at the same time simultaneous free intraperitoneal rupture. This very rare case was treated successfully by a minimally invasive method, namely ERCP, large sphincterotomy and bile duct decompression by cysts and membranes, percutaneous radiologic subdiaphragmatic drainage and prolonged medical treatment with albendazole. Our patient, an 87-year-old lady, was considered unfit for open or laparoscopic surgery because of her poor general condition, although surgery represents the common practice in such cases.

**Keywords** complicated hydatid cyst, cholangitis, ERCP, drainage

*Ann Gastroenterol* 2011; 24 (4): 328-330

## Introduction

In the most complete known study concerning liver cystic echinococcosis [1], comprising 2,013 patients operated for hydatid cyst, 12% had a rupture into the biliary tract, forming large biliocystic fistula >5mm, 1.6% had a rupture into the peritoneum cavity, but none had simultaneous rupture in both. A recent systematic review on the management of cystic echinococcosis complications and dissemination [2], concluded that regarding the treatment of complicated liver hydatid cysts the level of evidence is low.

## Case report

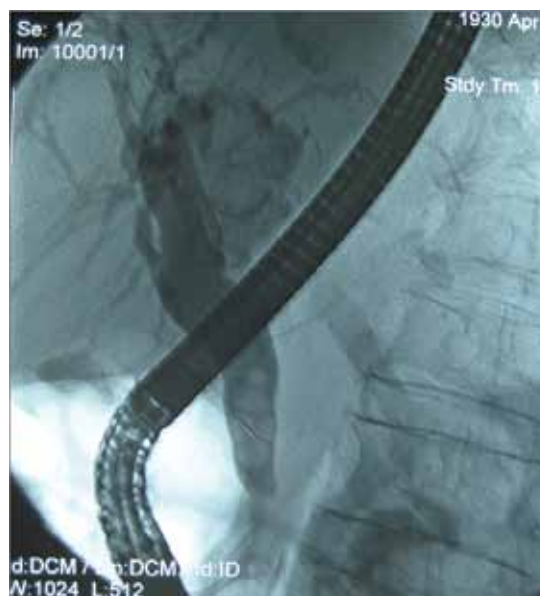
An 87-year-old woman, with senile dementia, diabetes mellitus, hypertensive diastolic heart failure and chronic renal disease presented at the Accident and Emergency

<sup>a</sup>Gastroenterology Division (Georgios Germanidis, Konstantinos Mantzoukis, Konstantinos Vasiliou); <sup>b</sup>Radiology Department (Tasos Kelekis), Aristotle University of Thessaloniki Medical School; <sup>c</sup>1st Department of Internal Medicine (Eleni Doumaki, Ioannis Kokinakis, Pantelis Zebekakis, Pavlos Nikolaidis);

Conflict of Interest: None

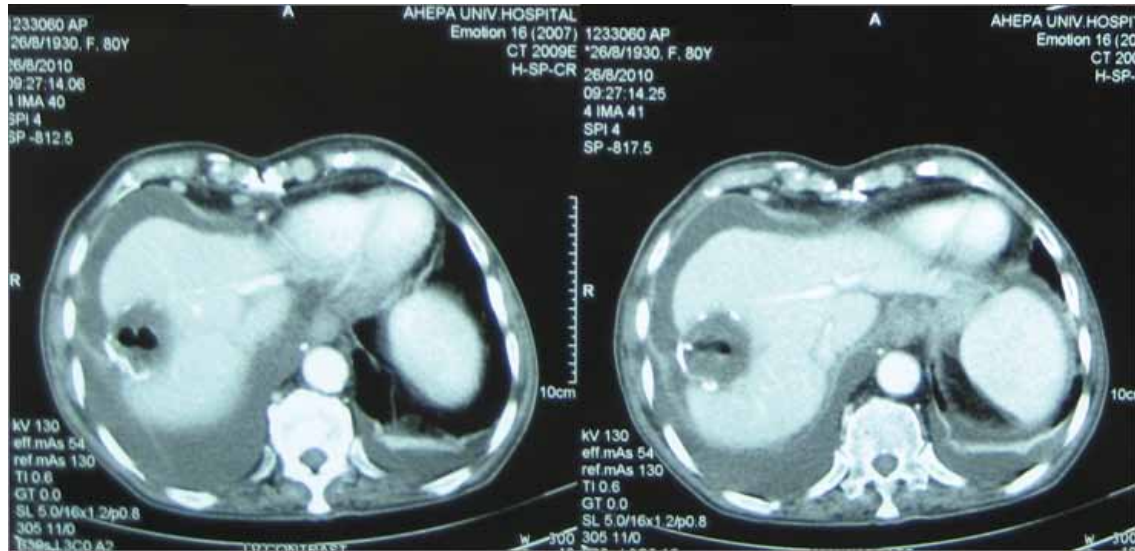
Correspondence to: Konstantinos Mantzoukis, AHEPA University Hospital, St. Kyriakidi 1, 546 36 Thessaloniki, Greece, tel.: +306936076410, fax: +302310994603; e-mail: kmantzoukis@hotmail.com

Received 7 April 2011; accepted 7 July 2011



**Figure 1** ERCP revealing at least five round bile duct contents (hydatid cysts and membranes)

Department with jaundice (total bilirubin 15.8 mg/dL, direct 12.4 mg/dL), significant bile duct dilatation at ECHO examination and obstructing cholangitis. Since 1987, when she has had an open cholecystectomy for symptomatic cholelithiasis, she was known to have three calcified asymptomatic hydatid cysts. One cyst was located at the spleen and another at the left liver lobe, both heavily calci-



**Figure 2** CT scan showing pleural effusion and large diffuse peritoneal effusion around the liver. Air is present inside the hydatid cyst

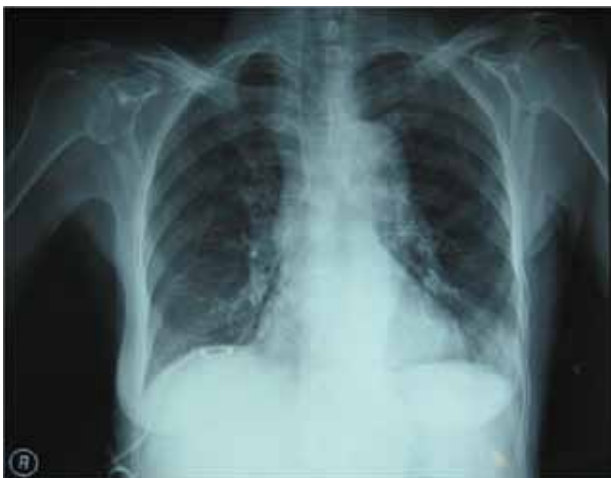fied. The third one, that was barely calcified radiologically, was at the periphery of the right liver lobe, about 45-50mm in diameter. An ERCP performed the next day visualized at least five round bile duct contents (Fig. 1), which proved to be, after sphincterotomy and debridement of the bile duct, hydatid cyst remnants. A 10F plastic stent was inserted and broad spectrum antibiotics were initiated. Bilirubin level dropped to a total of 5.31 mg/dL (direct 4.95 mg/dL) on day 3 of admission.

On the third day of hospitalization, the patient developed dyspnea, tachypnea and clinical signs of right pleural effusion and ascitic fluid. An emergency CT scan of the thorax and abdomen was performed that revealed a large right pleural effusion with atelectasis (which proved to be reactive after laboratory analysis), a small left effusion and a large dif-

fuse peritoneal effusion around the liver and down to the pelvis. Air was present inside the right hepatic lobe hydatid cyst, consistent with a biliary tree communication and the antecedent sphincterotomy (Fig. 2). The CT scan suggested a simultaneous free intraperitoneal cyst rupture. Due to the concomitant biliary tree communication, not only hydatid cysts and remnants, but also bile leak, was probably the cause of patient's large effusions.

After thorough discussion with the patient's family and considering her poor general status and possible technical difficulties, a minimal invasive approach was selected. After a second ERCP that removed the plastic stent and another debridement that confirmed an efficient sphincterotomy and a clear duct, a subdiaphragmatic drainage was placed radiologically. Albendazole at a dose of 15 mg/kg/day was initiated.

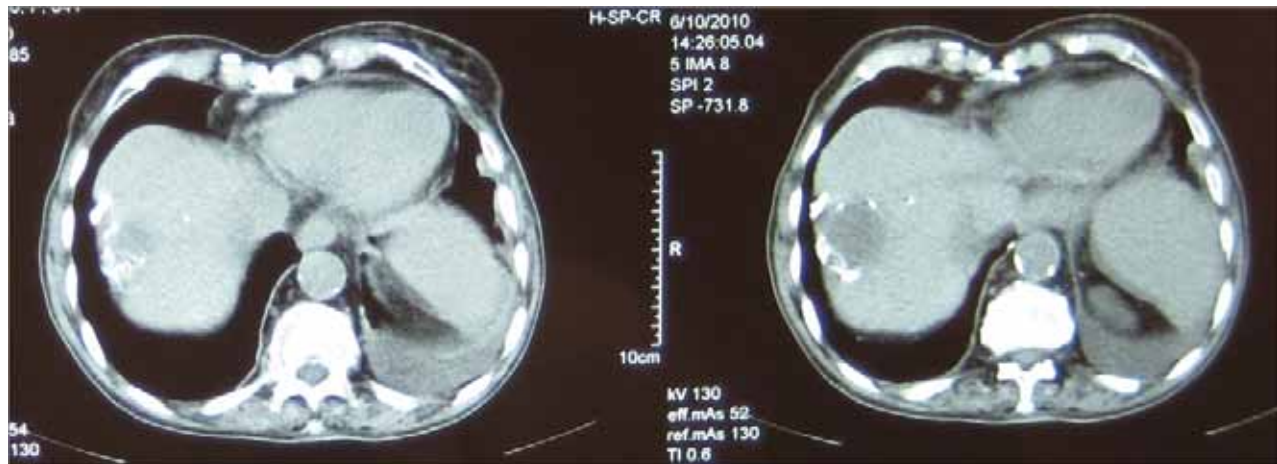
Peritoneal fluid drainage gradually fell from 300 cc to about 50 cc/day over a two-week period. X-ray chest film showed a complete resolution of the pleural effusions (Fig. 3) and CT scan revealed the absence of ascites (Fig. 4). After 3 months of albendazole, the drainage tube was extracted and patient remained both clinically and radiologically improved at the first monthly scheduled follow-up.



**Figure 3** Plain x-ray showing complete absorption of pleural effusion. A percutaneous subdiaphragmatic drainage is also noted

## Discussion

We report a case of complicated liver hydatid cyst with biliary tree communication, cholangitis, and simultaneous free intraperitoneal rupture. This very rare case was successfully treated in a minimally invasive way, initially with ERCP (large sphincterotomy and bile duct debridement), followed by percutaneous radiologic subdiaphragmatic drainage and prolonged administration of albendazole.



**Figure 4** Follow up CT scan with absence of ascites

Minimally invasive approaches like PAIR (Puncture, Aspiration, Injection, and Re-aspiration) are accepted, although as yet not fully, only for the treatment of uncomplicated hydatid cysts [4]. The best approach for complicated liver peripheral cysts ruptured into the biliary tract, is ERCP combined with complete surgical cyst removal including pericystic tissue and fistulous tract [4,5]. Surgery is not easy to perform in the context of acute cholangitis, especially in the presence of a free peritoneal cyst rupture. In fact, the principal difficulty concerns the management of the large biliocystic fistula (>5 mm), suture, internal transistulary drainage or fistulization. After a liver hydatid cyst intraperitoneal rupture, the mortality rate increases up to 6% and morbidity rates range between 20% and 35% [3,6]. These rates are even higher for older patients with poor performance status and comorbidities.

In conclusion, this very rare case which has not previously been reported to our knowledge, evaluates a clinically efficient alternative minimally invasive strategy for the treatment of complicated liver hydatid cyst. On this subject, the level of

evidence is low and there are still many questions but few answers, clearly demanding further study and evaluation.

## References

1. Zaouche A. La chirurgie des kystes hydatiques du foie, Tunis, *Société Tunisienne de Chirurgie* 1994;28-190.
2. Zaouche A, Haouet K, Jouini M, et al. Management of liver hydatid cysts with large biliocystic fistula: multicenter retrospective study. *World J Surg* 2001;25:28-39.
3. Dziri C, Haouet K, Fingerhut A, et al. Management of cystic echinococcosis complications and dissemination: where is the evidence? *World J Surg* 2009;33:1266-1273.
4. Shaw JM, Bornman PC, Krige JEJ. Hydatid disease of the liver. *SAJS* 2006;44:70-77.
5. Giouleme O, Nikolaidis N, Zazos P, et al. Treatment of complications of hepatic hydatid disease by ERCP. *Gastrointest Endosc* 2001;54:508-510.
6. Larbi N, Hedfi S, Selmi M, et al. Acute intraperitoneal rupture of liver hydatid cysts. *Ann Chir* 2002;127:487-488.