

Non-perforated duodenal diverticulitis

Konstantinos H. Katsanos^a, Dimitrios Nastos^b, Epameinondas V. Tsianos^a

University Hospital of Ioannina, Greece

Diverticula rarely occur within the lumen of the duodenum and are diagnosed in 2-5% of patients. They usually arise near the papilla of Vater and extend distally [1]. Duodenal diverticula are classified into two types: extraluminal or intraluminal. Although the patient with a diverticulum may be asymptomatic, a duodenal diverticulum usually presents with typical or atypical symptoms of peptic ulcer disease, but sometimes manifestations such as gastrointestinal bleeding, duodenal obstructions or pancreatitis may be severe [2]. The diagnosis of duodenal diverticula can be made with hypotonic duodenography, CT tomography and endoscopy. Duodenal diverticulitis is a rare complication of duodenal diverticulosis. It is often clinically misdiagnosed because it has no typical signs or symptoms and its CT findings may mimic other intra-abdominal processes.

We report the case of a 68-year-old female patient who presented with acute upper quadrant abdominal pain and leukocytosis and was diagnosed with non-perforated duodenal diverticulitis (Fig. 1). Patient was treated conservatively with antibiotics. In symptomatic duodenal diverticulitis cases, extraluminal diverticula are amenable to surgery, whereas intraluminal diverticula may be either surgically or endoscopically resected. Imaging of the biliary tree should be performed prior to any intervention [3].

In conclusion, duodenal diverticulitis can be a difficult endoscopic or CT diagnosis and should always include the differential diagnosis of duodenal and pancreatic inflammatory processes and masses. Operative treatment of duodenal diverticula is safe but should be reserved for those with emergent presentations or intractable symptoms.

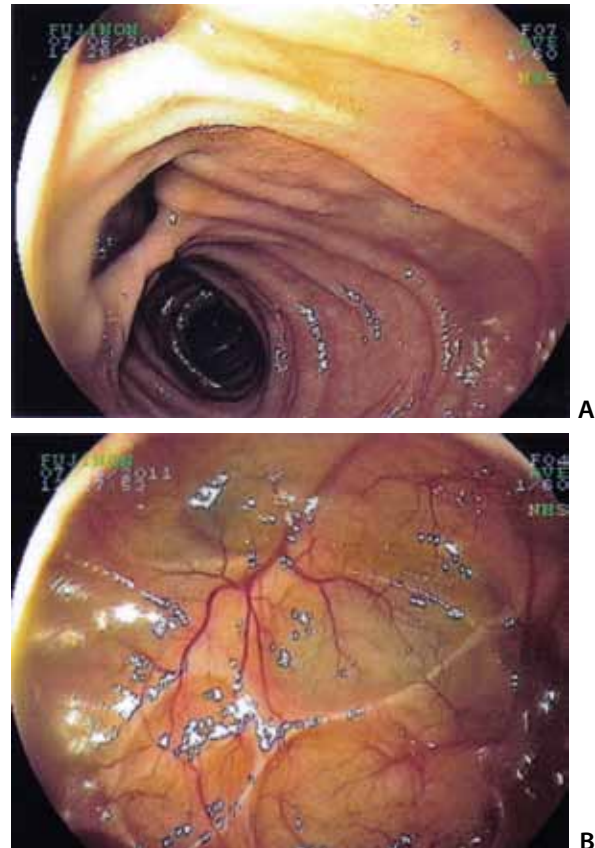


Figure 1. Duodenal diverticula in a patient presenting with acute upper abdominal pain (A. diverticulum opening and B. inside view).

^a1st Department of Internal Medicine & Hepato-Gastroenterology Unit, University Hospital of Ioannina, Greece (Konstantinos H. Katsanos, Epameinondas V. Tsianos); ^bDepartment of Surgery, University Hospital of Ioannina, Greece (Dimitrios Nastos)

Conflict of Interest: None

Correspondence to: Prof. Epameinondas V. Tsianos, MD, PhD, FEBGH, AGAF, Professor of Internal Medicine, 1st Division of Internal Medicine & Hepato-Gastroenterology Unit, Department of Internal Medicine, Medical School, University of Ioannina, 451 10, Ioannina, Greece, tel: 0030-26510-97501, fax: 0030-26510-97016, e-mail: etsianos@uoi.gr

Received 20 July 2011; accepted 29 July 2011

References

1. Fleming CR, Newcomer AD, Stephens DH, Carlson HC. Intraluminal duodenal diverticulum. Report of two cases and review of the literature. *Mayo Clin Proc* 1975;**50**:244-248.
2. Economides NG, McBurney RP, Hamilton FH 3rd. Intraluminal duodenal diverticulum in the adult. *Ann Surg* 1977;**185**:147-152.
3. Afridi SA, Fichtenbaum CJ, Taubin H. Review of duodenal diverticula. *Am J Gastroenterol* 1991;**86**:935-938.